

AMERICAN COLLEGE OF MOHS SURGERY



Final Program



Austin

41ST MOHS COLLEGE ANNUAL MEETING
HILTON AUSTIN - APRIL 23 - 26, 2009



American College of Mohs Surgery

41st Annual Meeting

April 23 – 26, 2009

Hilton Austin

Austin, TX

Final Program



American College of Mohs Surgery

555 East Wells Street, Suite 1100
Milwaukee, WI 53202

Phone: 414-347-1103 • 1-800-500-7224 • Fax: 414-276-2146

Email: info@mohscollege.org • Website: www.mohscollege.org



41ST MOHS COLLEGE ANNUAL MEETING
HILTON AUSTIN - APRIL 23 - 26, 2009

© 2009 American College of Mohs Surgery

No part of this publication may be reproduced without the prior written permission of the ACMS. Photos courtesy of the Austin Convention & Visitors Bureau (ACVB).

Photography Policy:

The ACMS arranged for a photographer to be present throughout the 2009 Annual Meeting. ACMS may use these photos on its World Wide Web site or in other official printed publications. Individuals photographed will not receive compensation for the use and release of these photos and will be deemed to have consented to the use and release of photos in which they appear. Individuals also acknowledge ACMS' right to crop or treat the photographs at its discretion. If you are opposed to being photographed, please immediately notify the photographer or an ACMS staff member if your picture is taken.

Thank you for your cooperation.

Table of Contents

Save-the-Date for 2010 Annual Meeting	3
ACMS Board of Directors	4
ACMS Committees and Task Forces	4
Fellowship Training Director Listing	5
Welcome Messages.	6
Program-at-a-Glance.	8
Hilton Austin Floor Plans	11
Guest Speakers	12
Faculty and Guest Speaker Listing	13
CME Information	14
Faculty Disclosure Information.	16
Scientific Program Schedule	
Thursday, April 23 rd	18
Friday, April 24 th	21
Saturday, April 25 th	23
Sunday, April 26 th	26
Abstracts	
Thursday, April 23 rd ; Tromovitch Award & Research	28
Friday, April 24 th ; Clinical Pearls	37
Saturday, April 25 th ; Research	39
Poster Presentation List.	43
Poster Presentation Summaries	45
Exhibitor Floor Plan.	63
Exhibitor Listing	64
ASMH Program-at-a-Glance.	68
Save-the-Date for 2011 Annual Meeting	Back Cover

42nd American College of Mohs Surgery Annual Meeting

Friday, April 30 –
Monday, May 3, 2010

Marriott Marquis New York, NY



New York • NY

2008–2009 Officers and Board of Directors

Officers

Duane C. Whitaker, MD, FACMS
President

Leonard M. Dzubow, MD, FACMS
Vice President

Brett M. Coldiron, MD, FACP, FACMS
Secretary/Treasurer

David G. Brodland, MD, FACMS
Immediate Past-President

Board of Directors

David P. Clark, MD, FACMS

Joel Cook, MD

Jonathan L. Cook, MD

Andrew J. Kaufman, MD, FACP

J. Ramsey Mellette, Jr., MD

Gregg M. Menaker, MD, FACMS

Marcy Neuburg, MD, FACMS

Roberta D. Sengelmann, MD, FACMS

Daniel M. Siegel, MD

Scientific Program Committee

Ken K. Lee, MD, FACMS, Chair

Roberta D. Sengelmann, MD, FACMS, Co-Chair

Brett M. Coldiron, MD, FACP, FACMS

Leonard M. Dzubow, MD, FACMS

Marcy Neuburg, MD, FACMS

Duane C. Whitaker, MD, FACMS

Sumaira Z. Aasi, MD, FACMS, Ex-Officio

Headquarters Staff

Georganne Dixon, Executive Director

Kim Schardin, Director of Programs

Erin O'Krongly, Communications Manager

Susan Sadowski, Program Manager

Courtney Kissinger, Administrative Assistant

Committees and Task Forces - 2009–2010

ASMH Manual Committee

Frederick S. Fish, III, MD, Chair

Bylaws Committee

Vicki J. Levine, MD, Chair

Communications & PR Committee

Alysa R. Herman, MD, Chair

CPT Rapid Response Task Force

David G. Brodland, MD, FACMS, Chair

Diagnostic Quality Control & Teaching Library Committee

Frederick S. Fish, III, MD, Co-Chair

Sumaira Z. Aasi, MD, FACMS, Co-Chair

Ethics Committee

Mary E. Maloney, MD, Chair

Frederic E. Mohs Award Committee

Ann F. Haas, MD, Chair

Industry Relations Committee

Gary Lask, MD, Chair

Investment Committee

Brett M. Coldiron, MD, FACP, FACMS, Chair

Membership Committee

Leonard M. Dzubow, MD, FACMS, Chair

Mohs Histotechnology Quality Assurance Committee

Elizabeth M. Billingsley, MD, Chair

Newsletter Committee

Désirée Ratner, MD, Chair

Nominating Committee

Hubert T. Greenway, Jr., MD, Chair

Scientific Program Committee

Ken K. Lee, MD, FACMS, Chair

Tromovitch Award Committee

Peter K. Lee, MD, PhD, Chair

Website Committee

Christine Min-Wei Lee, MD, Chair

Site Inspection & Slide Review Board, LLC

(An ACMS subsidiary)

Fellowship Training Committee

Suzanne Olbricht, MD, Chair

Slide Review Committee

Glenn D. Goldstein, MD, Chair

Fellowship Training Director Listing

Murad Alam, MD
John G. Albertini, MD
Joseph Alcalay, MD
Christopher J. Arpey, MD
Philip L. Bailin, MD
David S. Becker, MD
Anthony V. Benedetto, DO
Richard G. Bennett, MD
Daniel Berg, MD
Robert A. Buzzell, MD
Roger I. Ceilley, MD
Armand B. Cognetta, Jr., MD
Brett M. Coldiron, MD, FACP, FACMS
Brian Cook, MD
Joel Cook, MD
Scott M. Dinehart, MD
Heidi B. Donnelly, MD
Raymond G. Dufresne, Jr., MD
Yehuda D. Eliezri, MD
Michael J. Fazio, MD
Franklin P. Flowers, MD
Scott W. Fosko, MD
Algin B. Garrett, MD
Roy G. Geronemus, MD
Hugh M. Gloster, Jr., MD
David J. Goldberg, MD
Leonard H. Goldberg, MD
Glenn D. Goldman, MD
Glenn D. Goldstein, MD
Donald J. Grande, MD
Steven S. Greenbaum, MD
Hubert T. Greenway, Jr., MD
Roy C. Grekin, MD
C. William Hanke, MD
George J. Hruza, MD
S. Brian Jiang, MD
David E. Kent, MD
Gary Lask, MD
Naomi Lawrence, MD
Susana M. Leal-Khoury, MD
David J. Leffell, MD
Mary E. Maloney, MD
Victor J. Marks, MD
Michael W. McCall, MD
J. Ramsey Mellette, Jr., MD
Gary D. Monheit, MD
Greg S. Morganroth, MD
Ronald L. Moy, MD
Bruce R. Nelson, MD

Tri H. Nguyen, MD
Peter B. Odland, MD
Suzanne Olbricht, MD
Ida F. Orengo, MD
Robert D. Paver, MD
Steven A. Proper, MD
Michael L. Ramsey, MD
Désirée Ratner, MD
Randall K. Roenigk, MD
Gary S. Rogers, MD
Thomas E. Rohrer, MD
Paul J.M. Salmon, MD
Daniel M. Siegel, MD
Ronald J. Siegle, MD
Stephen N. Snow, MD
Thomas Stasko, MD
Neil A. Swanson, MD
R. Stan Taylor, III, MD
Abel Torres, MD
Carl Vinciullo, MD
Timothy S. Wang, MD
Carl V. Washington, Jr., MD
J. Michael Wentzell, MD
Phillip M. Williford, MD
Nathalie C. Zeitouni, MD
John A. Zitelli, MD
David M. Zloty, MD

Welcome from the President



Dear ACMS Members and Colleagues,

On behalf of the ACMS Board of Directors, I welcome you down to Austin, Texas and to the 41st Annual Meeting of the College.

I hope you have been looking forward to this week as much as I have; to join the more than 700 ACMS fellowship-trained skin cancer and reconstructive surgeons to learn, collaborate, and share with one another for the benefit of our patients. My sincere hope is that you are able to take much away from this meeting, which will resonate long after in your own practice.

I extend my sincere appreciation and gratitude to the Scientific Program Committee Chair, Dr. Ken K. Lee, for the enormous amount time and effort he has put into assembling a well-rounded and exceptional program. Special thanks go out to the members of the Scientific Program Committee: Drs. Brett M. Coldiron, Leonard M. Dzubow, Marcy Neuburg, Roberta D. Sengelmann, and Sumaira Z. Aasi, for their diligent work and contributions in planning this year's events.

In addition to an excellent program, the Exhibit Hall will provide information and extensive resources to benefit your practice. I strongly encourage you to take full advantage of the exhibitors' presence and visit them during your time here.

Aside from the opportunities available at our meeting for you to grow as a Mohs surgeon, take the time to experience what Austin has to offer. Dubbed the Live Music Capital of the World®, Austin has nearly 200 live music venues throughout the city, as well as a vast array of recreational activities and scenic beauty to explore.

I hope you enjoy your time here in Austin for what I believe will be another outstanding Annual Meeting of the American College of Mohs Surgery!

Sincerely,

Duane C. Whitaker, MD, FACMS
ACMS President

Welcome from the Scientific Program Chair



Dear Colleagues,

I am pleased to present the educational program for the 2009 ACMS Annual Meeting in Austin. The program has been created with great care to provide practical, broad, and relevant knowledge to enhance your practice skill in Mohs surgery, cutaneous oncology, reconstructive and cosmetic surgery.

We are fortunate to have two distinguished guest speakers both who bring unique and important perspectives from longstanding close relationships with Mohs surgeons.

Dr. Shan R. Baker, Professor and Director of the Center for Facial Cosmetic Surgery at the University of Michigan Medical Center will lecture on *Applying Rhinoplasty Principles to Nasal Reconstruction*, giving us insight into the aesthetic and three dimensional aspects of nasal repairs. Dr. Clay J. Cockerell, Director of Dermatopathology at the UT Southwestern Medical School, will team up with R. Stan Taylor, III, MD and share in *Challenging Cases from Dallas*, demonstrating the important interaction between Mohs surgeons and dermatopathologists.

There are several new additions to this year's program. *Reconstructive Challenges* is a new series that will provide an in-depth view of difficult repairs: this year's subject is *Full Thickness Defects*. We have also added the *Clinical Pearls Abstracts* giving our members a forum to share their practical tips. Saturday afternoon will feature *Practical Issues in Practicing Mohs Surgery*, a session devoted to effectively running a Mohs surgery office.

I want to extend a special thanks to the Scientific Program Committee members: Drs. Brett M. Coldiron, Leonard M. Dzubow, Marcy Neuburg, Roberta D. Sengemann, Duane C. Whitaker, and Ex-Officio Member, Sumaira Z. Aasi, for their valuable insights and advice that went into bringing these quality sessions to our program.

The Scientific Program Committee hopes that you are as excited as we are about what the 2009 Annual Meeting for the American College of Mohs Surgery in Austin has to offer.

Sincerely,

A stylized, handwritten signature in black ink that reads "Ken K. Lee".

Ken K. Lee, MD, FACMS
ACMS Scientific Program Committee, Chair

Program-at-a-Glance

Wednesday, April 22

3:30 – 6:30 pm	Registration	Austin Grand Ballroom Lobby
3:30 – 6:30 pm	Speaker Ready Room	Room 404

Thursday, April 23

6:30 am – 5:00 pm	Registration	Austin Grand Ballroom Lobby
6:30 am – 5:00 pm	Speaker Ready Room	Room 404
7:00 am – 5:00 pm	Slide Library and Diagnostic Quality Control Self-Examination	Room 602
7:15 – 8:45 am	Concurrent Morning Mini-sessions:	
	103.1 Nasal Reconstruction for Medium Sized Defects	Salon J
	103.2 Melanoma Update	Salon K
	103.3 An Approach to Periorbital Reconstruction	Room 400
	103.4 Incorporating Cosmetic Surgery into a Mohs Practice	Room 412
	103.5 Immunostaining	Room 408
9:00 – 9:30 am	Opening Session	Governor's Ballroom
9:30 – 10:30 am	Tromovitch Award Abstract Session	Governor's Ballroom
10:30 – 10:45 am	Break	
10:45 – 11:45 am	How Would You Reconstruct It? (Interactive Polling)	Governor's Ballroom
11:45 am – 1:00 pm	Visit the Exhibit Hall and Posters; lunch provided in Exhibit Hall	Salon H
12:00 – 6:30 pm	Exhibit Hall Open	Salon H
1:00 – 2:00 pm	Revision Surgery	Governor's Ballroom
2:00 – 3:00 pm	Controversies in Mohs Surgery (Interactive Polling)	Governor's Ballroom
3:00 – 3:30 pm	Break; visit the Exhibit Hall and Posters	Salon H
3:30 – 4:30 pm	Research Abstract Session	Governor's Ballroom
4:30 – 5:30 pm	Reconstructive Challenges: The Full Thickness Defect	Governor's Ballroom
5:30 – 7:00 pm	Welcome Reception	Salon H

Special Event for Thursday, April 23

Welcome Reception 5:30 – 7:00 pm; Salon H

Don't miss this chance to relax and unwind with colleagues before an evening out in beautiful Austin. Hors d'oeuvres and beverages will be provided for your enjoyment.

Special Event for Friday, April 24

ACMS Membership Business Meeting 12:15 – 1:30 pm; Salons J & K

Mohs College members are encouraged to attend the annual membership business meeting and lunch. This important meeting brings members up-to-date on issues of significance, such as CPT coding. The winners of the prestigious Frederic E. Mohs Distinguished Service Award and the Tromovitch Award will be announced. Lunch will be provided.

Program-at-a-Glance

Friday, April 24

6:30 am – 5:00 pm	Registration	Austin Grand Ballroom Lobby
6:30 am – 5:00 pm	Speaker Ready Room	Room 404
7:00 am – 5:00 pm	Slide Library and Diagnostic Quality Control Self-Examination	Room 602
7:15 – 8:45 am	Concurrent Morning Mini-sessions:	
	203.1 Setting Up a Mohs Histopathology Laboratory	Room 410
	203.2 Role of Imaging in Non-melanoma Skin Cancer	Room 400
	203.3 Perioral Reconstruction	Salon J
	203.4 CPC: Challenging Cutaneous Tumors	Room 412
	203.5 Regional Reconstruction	Room 408
	203.6 Managing Lower Extremity Cancers and Defects	Salon K
9:00 – 10:00 am	Coding Conundrums (Interactive Polling)	Governor's Ballroom
10:00 – 11:00 am	Applying Rhinoplasty Principles to Nasal Reconstruction —featuring guest speaker Shan R. Baker, MD	Governor's Ballroom
11:00 – 11:15 am	Break	
11:15 am – 12:15 pm	Mohs Histopathology Conundrums (Interactive Polling)	Governor's Ballroom
12:00 – 6:00 pm	Exhibit Hall Open	Salon H
12:15 – 1:30 pm	ACMS Annual Business Meeting (lunch provided) Non-members and guests lunch on own; visit the Exhibit Hall	Salons J & K; Salon H
1:30 – 2:30 pm	The Undesirable Result in Reconstructive Surgery	Governor's Ballroom
2:30 – 3:00 pm	Break; visit the Exhibit Hall and Posters	Salon H
3:00 – 4:00 pm	Clinical Pearls Abstract Session	Governor's Ballroom
4:00 – 5:00 pm	Afternoon at the Movies	Governor's Ballroom
5:00 – 6:00 pm	Visit the Exhibit Hall and Posters	Salon H

Special Events for Saturday, April 25

WDS Networking Luncheon 1:00 – 2:30 pm; Room 400

As part of its mission to foster leadership, mentorship, and networking among women dermasurgeons, the WDS Women Dermatologic Surgeons Committee is holding a Networking Luncheon at the ACMS meeting. Pre-registration was required for attendance to this event.

Industry Sponsored Session: Advanced Asset Protection, Tax and Estate Planning for Mohs Surgeons 1:00 – 3:00 pm; Salon J

This Industry Sponsored Session, hosted by O'Dell Jarvis Mandell, LLC, is free to all attendees of the ACMS Annual Meeting. Attendees of this session will be eligible to earn an additional 4 Category 1 CME Credits through O'Dell Jarvis Mandell, LLC, which will be discussed during the session. Lunch will be provided.

Fellowship Training Directors' Session 5:00 – 6:00 pm; Salon J

All Fellowship Training Directors are encouraged to attend this session, followed by the Fellows-in-training Reception at 6:00 pm in Salon K.

Fellows-in-Training Reception 6:00 – 7:30 pm; Salon K

Fellowship training directors and current fellows-in-training are invited to attend. This event offers the opportunity for fellows-in-training to network and socialize with each other, other fellowship training directors, and the College leadership. The Tromovitch award will be presented and hors d'oeuvres and beverages will be provided. Come prepared to introduce yourself to the group.

Program-at-a-Glance

Saturday, April 25

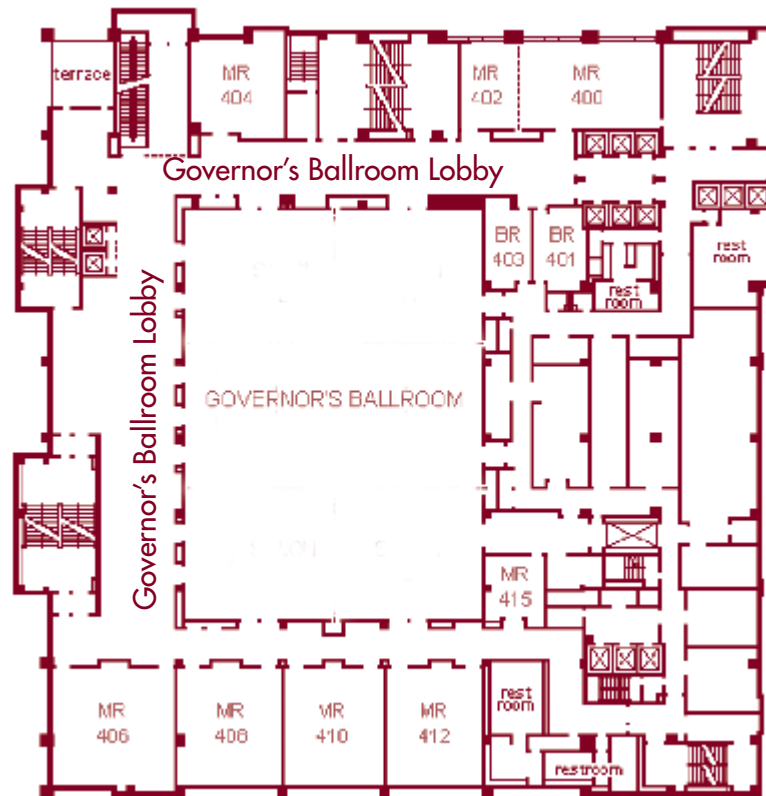
7:00 am – 2:00 pm	Registration	Austin Grand Ballroom Lobby
7:00 am – 2:00 pm	Speaker Ready Room	Room 404
7:00 am – 2:00 pm	Slide Library and Diagnostic Quality Control Self-Examination	Room 602
7:15 – 8:45 am	Concurrent Morning Mini-sessions:	
	304.1 Advanced Reconstruction: From Plastics to Mohs	Salon J
	304.2 Beyond the Basics: Advanced Nail Surgery	Room 400
	304.3 Ear Reconstruction	Salon K
	304.4 Advanced Blepharoplasty	Room 412
	304.5 Lasers for the Mohs Surgeon	Room 408
8:30 am – 2:00 pm	Exhibit Hall Open	Salon H
9:00 – 10:30 am	Concurrent Scientific Sessions:	
	306.1 Tumor Board (9:00 – 10:30 am)	Salon K
	306.2 Morning at the Movies: Cosmetic Surgery (9:00 – 10:00 am)	Salon J
	306.3 Managing Cosmetic Patients: Conversation with the Experts (10:00 – 10:30 am)	Salon J
10:30 – 11:00 am	Break; visit the Exhibit Hall and Posters	Salon H
11:00 am – 12:00 pm	Challenging Cases from Dallas —featuring guest speaker Clay J. Cockerell, MD	Governor's Ballroom
12:00 – 1:00 pm	Research Abstract Session	Governor's Ballroom
1:00 – 2:30 pm	WDS Networking Luncheon	Room 400
1:00 – 3:00 pm	Industry Sponsored Session: Advanced Asset Protection, Tax and Estate Planning for Mohs Surgeons (Hosted by: O'Dell Jarvis Mandell, LLC) (Additional 4 Category 1 CME Credits available with this session)	Salon J
2:00 – 7:00 pm	Exhibit and Poster Tear-Down	Salon H
3:00 – 5:00 pm	Practical Issues in Practicing Mohs Surgery	Governor's Ballroom
4:00 – 5:00 pm	Fellowship Training Committee Meeting	Room 403
5:00 – 6:00 pm	Fellowship Training Directors' Session	Salon J
6:00 – 7:30 pm	Fellows-in-Training Reception	Salon K

Sunday, April 26

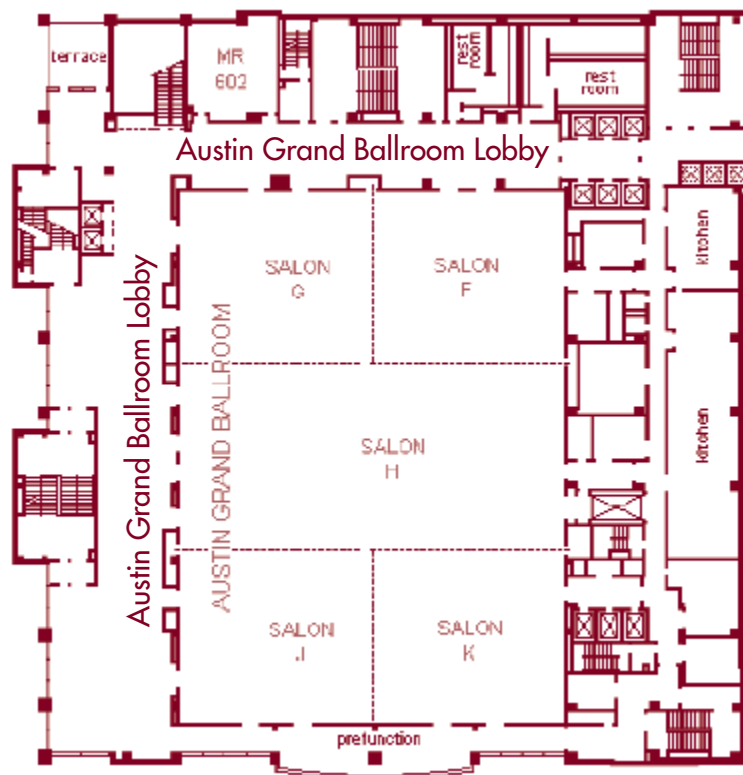
7:00 – 10:00 am	Registration	Austin Grand Ballroom Lobby
7:00 – 10:00 am	Speaker Ready Room	Room 404
7:15 – 8:45 am	Concurrent Morning Mini-sessions:	
	402.1 Reconstruction of the Face with Cutaneous Flaps	Room 400
	402.2 Nasal Reconstruction: Classic and Unconventional	Salon K
	402.3 Coding for Mohs Surgeons	Salon J
9:00 – 9:50 am	Diagnostic Quality Control Exam Review	Governor's Ballroom
9:50 – 10:00 am	Break	
10:00 am – 12:00 pm	Cosmetic Symposium	Governor's Ballroom
12:00 pm	Meeting adjourns	

Hilton Austin Floor Plans

Fourth Floor



Sixth Floor



Guest Speakers



Shan R. Baker, MD

Shan R. Baker, MD is Professor and Director of the Center for Facial Cosmetic Surgery at the University of Michigan Medical Center where he has been on faculty since 1977.

Dr. Baker is a diplomate of the American Board of Facial Plastic and Reconstructive Surgery, American

Board of Cosmetic Surgery, and the American Board of Otolaryngology-Head and Neck Surgery. He is the past president of the American Academy of Facial Plastic and Reconstructive Surgery and is currently the president of the American Board of Facial Plastic and Reconstructive Surgery.

Dr. Baker is an internationally renowned lecturer and his distinguished academic career includes over 140 publications, 70 book chapters, and 6 books on facial plastic surgery and reconstruction. His textbooks *Local Flaps in Facial Reconstruction* and *Principles of Aesthetic Nasal Reconstruction* have been essential references for all reconstructive surgeons.

He will share his unique experiences in combining aesthetic rhinoplasty and reconstruction in his lecture *Applying Rhinoplasty Principles to Nasal Reconstruction* on Friday, April 24th, from 10:00 – 11:00 am.



Clay J. Cockerell, MD

Clay J. Cockerell, MD is Professor of Dermatology and Pathology and Director of Dermatopathology at UT Southwestern Medical School. He is the Medical Director of Cockerell and Associates Dermatopathology as well as a diplomate of the American Academy of Dermatology and

American Board of Dermatopathology.

Dr. Cockerell is internationally recognized for his contributions to both dermatology and dermatopathology. He is the past president of the American Academy of Dermatology. For many years, Dr. Cockerell has overseen an educational program designed to train the next generation of dermatopathologists. He has served as Associate Editor of the *Journal of the American Academy of Dermatology* and is on the editorial boards of a number of medical journals including the *American Journal of Dermatopathology*.

He will share his experiences working with Mohs surgeons in presenting *Challenging Cases from Dallas* on Saturday, April 25th, from 11:00 am – 12:00 pm.



Faculty and Guest Speaker Listing

Sumaira Z. Aasi, MD, FACMS, New Haven, CT
Murad Alam, MD, Chicago, IL
John G. Albertini, MD, Greensboro, NC
Christie T. Ammirati, MD, Hershey, PA
Stephen D. Antrobus, MD, Baton Rouge, LA
Christopher J. Arpey, MD, Iowa City, IA
Mathew M. Avram, MD, JD, Boston, MA
Shan R. Baker, MD, Livonia, MI
Anna A. Bar, MD, Portland, OR
Christian L. Baum, MD, Iowa City, IA
Richard G. Bennett, MD, Santa Monica, CA
Ashish Bhatia, MD, Aurora, IL
Christopher K. Bichakjian, MD, Ann Arbor, MI
Glen M. Bowen, MD, Salt Lake City, UT
Jerry D. Brewer, MD, Rochester, MN
Gregory M. Bricca, MD, Roseville, CA
David G. Brodland, MD, FACMS, Pittsburgh, PA
Marc D. Brown, MD, Rochester, NY
Susan Butler, MD, St. Louis, MO
John A. Carucci, MD, PhD, New York, NY
Kyung H. Chang, MD, PhD, Boston, MA
Michael W. Chen, MD, Santa Monica, CA
Basil S. Cherpelis, MD, Tampa, FL
Leslie J. Christenson, MD, Ames, IA
Vinh Q. Chung, MD, Atlanta, GA
Clay J. Cockerell, MD, Dallas, TX
Joel L. Cohen, MD, Englewood, CO
Brett M. Coldiron, MD, FACP, FACMS, Cincinnati, OH
Siobhan C. Collins, MD, Farmington, CT
Joel Cook, MD, Charleston, SC
Jonathan L. Cook, MD, Durham, NC
Robert H. Cook-Norris, MD, Rochester, MN
Bryce J. Cowan, MD, Vancouver, Canada
Aerlyn G. Dawn, MD, MBA, Philadelphia, PA
Scott M. Dinehart, MD, Little Rock, AR
Heidi B. Donnelly, MD, Dayton, OH
Leonard M. Dzubow, MD, FACMS, Villanova, PA
Quenby L. Erickson, DO, Houston, TX
Edgar F. Fincher, MD, Los Angeles, CA
Frederick S. Fish, III, MD, Fridley, MN
Scott W. Fosko, MD, St. Louis, MO
Manish J. Gharra, MD, Brookfield, WI

Hayes B. Gladstone, MD, Stanford, CA
Glenn D. Goldman, MD, Burlington, VT
Glenn D. Goldstein, MD, Leawood, KS
Monica Halem, MD, San Francisco, CA
Christopher B. Harmon, MD, Birmingham, AL
Todd E. Holmes, MD, Burlington, VT
George J. Hruza, MD, Chesterfield, MO
Tatyana R. Humphreys, MD, Philadelphia, PA
Humza Ilyas, MD, Madison, WI
Christopher R. Jarvis, MBA, Austin, TX
Nathaniel J. Jellinek, MD, Providence, RI
Timothy M. Johnson, MD, Ann Arbor, MI
Hillary Johnson-Jahangir, MD, PhD, New York, NY
Andrew J. Kaufman, MD, FACP, Thousand Oaks, CA
Jenny J. Kim, MD, PhD, Los Angeles, CA
Ravi S. Krishnan, MD, Seattle, WA
Joy H. Kunishige, MD, Pittsburgh, PA
Gary Lask, MD, Los Angeles, CA
Naomi Lawrence, MD, Marlton, NJ
Brian C. Leach, MD, Colorado Springs, CO
Ken K. Lee, MD, FACMS, Portland, OR
Peter K. Lee, MD, PhD, Edina, MN
Thomas G. Lewis, MD, Kettering, OH
Nanette Liégeois-Kwon, MD, PhD, Lutherville, MD
Deborah MacFarlane, MD, Houston, TX
Cathy A. Macknet, MD, Loma Linda, CA
Robert J. MacNeal, MD, Iowa City, IA
David B. Mandell, JD, MBA, Fort Lauderdale, FL
Victor J. Marks, MD, Danville, PA
Juan-Carlos Martinez, MD, Jacksonville, FL
J. Ramsey Mellette, Jr., MD, Aurora, CO
Christopher J. Miller, MD, Philadelphia, PA
Greg S. Morganroth, MD, Mountain View, CA
Kevin J. Mott, MD, Honolulu, HI
Ronald L. Moy, MD, Los Angeles, CA
Girish S. Munavalli, MD, MHS, Charlotte, NC
Marcy Neuburg, MD, FACMS, Milwaukee, WI
Isaac M. Neuhaus, MD, San Francisco, CA
Tri H. Nguyen, MD, Houston, TX
Keyvan Nouri, MD, Miami, FL
Suzanne Olbricht, MD, Burlington, MA
Clark C. Otley, MD, Rochester, MN

David M. Pariser, MD, FAAD, Norfolk, VA
John C. Perrotto, DO, West Des Moines, IA
Jeffrey E. Petersen, MD, Columbus, IN
Melissa Pugliano-Mauro, MD, Burlington, VT
Désirée Ratner, MD, New York, NY
Larisa Ravitskiy, MD, Columbus, OH
Jennifer L. Reichel, MD, Seattle, WA
Randall K. Roenigk, MD, Rochester, MN
Heather D. Rogers, MD, New York, NY
Thomas E. Rohrer, MD, Chestnut Hill, MA
Steven M. Rotter, MD, Vienna, VA
Carl F. Schanbacher, MD, Milford, MA
Chrysalyne D. Schmulse, MD, Jamaica Plain, MA
Rafael Schulze, MD, Mountain View, CA
Roberta D. Sengemann, MD, FACMS, Santa Barbara, CA
Stephen N. Snow, MD, Madison, WI
Brian Somoano, MD, San Mateo, CA
Monika Srivastava, MD, Teaneck, NJ
Thomas Stasko, MD, Nashville, TN
Neil A. Swanson, MD, Portland, OR
R. Stan Taylor, III, MD, Dallas, TX
Jens Thiele, MD, Birmingham, AL
Valencia D. Thomas, MD, Houston, TX
Maya Thosani, MD, Cincinnati, OH
Emily P. Tierney, MD, Carmel, IN
Timothy S. Wang, MD, Ann Arbor, MI
Carl V. Washington, Jr., MD, Atlanta, GA
Susan H. Weinkle, MD, Bradenton, FL
Duane C. Whitaker, MD, FACMS, Tucson, AZ
Andrea Willey, MD, Sacramento, CA
Summer R. Youker, MD, Sacramento, CA
Christopher B. Zachary, MD, Irvine, CA
Mark J. Zalla, MD, Florence, KY
John A. Zitelli, MD, Pittsburgh, PA

CME Information

Verification of Attendance

Registrants will receive a two-part CME letter of accreditation/claim form on-site. The second (yellow) page of the form must be submitted to the ACMS on-site or via mail/fax no later than May 25, 2009 for proper documentation of attendance. The first (white) page of the form should be kept by each meeting attendee as verification of meeting attendance.

CME Credit

This activity has been planned and implemented in accordance with the Essential Areas and policies of the Accreditation Council for Continuing Medical Education (ACCME) through the joint sponsorship of the Medical College of Wisconsin and The American College of Mohs Surgery. The Medical College of Wisconsin (MCW) is accredited by the ACCME to provide continuing medical education for physicians.

The Medical College of Wisconsin designates this educational activity for a maximum of *25 AMA PRA Category 1 Credits™*. Physicians should only claim credit commensurate with the extent of their participation in the activity.

Please complete the conference evaluation forms in your packet. Your feedback is extremely valuable. Be sure to evaluate each presentation and indicate the actual hours you attend the conference. Participants will be sent an overall evaluation via email upon completion of the conference and suggestions for future topics are welcome. CME certificates will be awarded at the conclusion of the conference.

The American College of Mohs Surgery (ACMS) Annual Meeting is recognized by the American Academy of Dermatology for 25 hours of AAD Category 1 CME credit and may be used toward the American Academy of Dermatology's Continuing Medical Education Award. The program number is 197-100.

AAD members should claim their AAD recognized Category 1 Credits via the AAD Online Transcript Program.

Industry Sponsored Session CME Credit

Attendees of the *Industry Sponsored Session: Advanced Asset Protection, Tax and Estate Planning for Mohs Surgeons*, hosted by O'Dell Jarvis Mandell, LLC on Saturday, April 25, will be eligible to receive 4 Category 1 CME credits. Those interested in claiming credit hours will receive the enduring material monograph *Risk Management for the Practicing Physician*, accredited for 4 Category 1 hours. At the session it will be explained how credits are earned with the monograph.

Physician Assistant Credit

The American Academy of Physician Assistants accepts AMA PRA Category 1 Credit(s)™ from organizations accredited by the ACCME. Physician Assistants attending the annual meeting can submit certificates or transcripts showing how many physician CME credits were offered for an activity to the American Association of Physician Assistants and get them "converted" to PA CME credit. **

** Doctors earn AMA PRA Category 1 Credits from CME activities. The AAPA also grants and counts Category 1 CME credits, but those are specifically for PAs and have to come from a provider accredited by the AAPA. Both groups label their credits Category 1 CME, but the labels, though they read the same, refer to different evaluations.

Disclosure of Faculty Financial Affiliations

The Medical College of Wisconsin, as an ACCME accredited provider, endorses and strives to comply with the Accreditation Council for Continuing Medical Education (ACCME) Standards of Commercial Support on the need for disclosure and monitoring of proprietary and financial interests that may affect the scientific integrity and balance of content delivered in continuing medical education activities under our auspices. The Medical College of Wisconsin requires that all CME activities accredited through this institution be developed independently and be scientifically rigorous, balanced, and objective in the presentation/discussion of its content, theories, and practices. Disclosure of faculty and commercial relationships will be made known at the annual meeting.

Disclosure of Discussion of Non-FDA Approved Uses for Pharmaceutical Products and/or Medical Devices

The Medical College of Wisconsin, as an ACCME provider, requires that all faculty presenters identify and disclose any off-label uses for pharmaceutical and medical device products.

Disclaimer

The views expressed and the techniques presented by the speakers of the ACMS-sponsored educational meetings are not necessarily shared or endorsed by the organization. Speakers are required to disclose all relevant conflicts of interest and any unapproved or off-label uses of medical devices or pharmaceutical agents that they discuss, describe, or demonstrate during their presentations.

Meeting attendees should use their independent judgment in applying the information discussed in these educational sessions in the treatment of patients. Handout materials are prepared and submitted for distribution by the presenters, who are solely responsible for their content.

CME Information

Learning Objectives

Upon completion of the Annual Meeting, participants will be able to describe the latest advances in the treatment of skin cancer, discuss recent research findings in the area of Mohs micrographic surgery and cutaneous oncology, and explain new techniques in reconstruction that promote optimal surgical outcomes.

The specific learning objectives, upon completion of the ACMS Annual Meeting include, but are not limited to:

- Describe various research projects being pursued within the areas of Mohs surgery, cutaneous oncology, and reconstruction.
- Identify controversial practices in the field of Mohs surgery and cutaneous oncology and explain both arguments for and against particular techniques.
- Describe the correct way to bill for Mohs surgery, reconstruction, and other dermatologic surgery procedures in real clinical situations.
- Discuss novel techniques for repair of surgical defects of the nose, ears, lips, and eyes.
- Discuss the principles and limitations of MR, CT, and US as applied to non-melanoma skin cancer.
- Discuss various ways to reconstruct specific surgical defects for optimal cosmetic and functional results.
- Discuss the optimal management of unusual and difficult tumors.
- Approach nail surgery with a greater understanding of anatomy and principles of anesthesia and techniques to achieve excellent surgical exposure, including novel plate avulsion techniques, nail fold reflection, and methods to obtain a bloodless field.
- Get to know the different laser and non-laser devices available on the market and understand how to use lasers in your practice as an adjunct to Mohs surgery.
- Apply new practice management pearls to ones practice.



Faculty Disclosure Information

Interest Disclosures

As an organization accredited by the ACCME to sponsor continuing medical education activities, The Medical College of Wisconsin is required to disclose any real or apparent conflicts of interest (COI) that any speakers may have related to the content of their presentations.

The Medical College of Wisconsin requires that each speaker participating in a program designated for AMA Physician's Recognition Award Category 1 credit disclose any financial interest/arrangement or affiliation with a corporate organization that may impact on his/her presentation (i.e. grants, research support, honoraria, member of speakers' bureau, consultant, major stock shareholder, etc.). In addition, the faculty member must disclose when an unlabeled use of a commercial product or an investigational use not yet approved for any purpose is discussed during the educational activity.

No Interests to Disclose:

Sumaira Z. Aasi, MD, FACMS

Murad Alam, MD

John G. Albertini, MD

Christie T. Ammirati, MD

Stephen D. Antrobus, MD

Christopher J. Arpey, MD

Shan R. Baker, MD

Christian L. Baum, MD

Richard G. Bennett, MD

Ashish Bhatia, MD

Christopher K. Bichakjian, MD

Glen M. Bowen, MD

Jerry D. Brewer, MD

Gregory M. Bricca, MD

David G. Brodland, MD, FACMS

Marc D. Brown, MD

John A. Carucci, MD, PhD

Kyung H. Chang, MD, PhD

Michael W. Chen, MD

Basil S. Cherpelis, MD

Leslie J. Christenson, MD

Vinh Q. Chung, MD

Clay J. Cockerell, MD

Brett M. Coldiron, MD, FACP, FACMS

Siobhan C. Collins, MD

Joel Cook, MD

Jonathan L. Cook, MD

Robert H. Cook-Norris, MD

Bryce J. Cowan, MD

Heidi B. Donnelly, MD

Leonard M. Dzubow, MD, FACMS

Quenby L. Erickson, DO

Frederick S. Fish, III, MD

Manish J. Gharia, MD

Hayes B. Gladstone, MD

Glenn D. Goldman, MD

Glenn D. Goldstein, MD

Monica Halem, MD

Christopher B. Harmon, MD

Todd E. Holmes, MD

Tatyana R. Humphreys, MD

Humas Ilyas, MD

Christopher R. Jarvis, MBA

Nathaniel J. Jellinek, MD

Hillary Johnson-Jahangir, MD, PhD

Timothy M. Johnson, MD

Andrew J. Kaufman, MD, FACP

Ravi S. Krishnan, MD

Joy Kunishige, MD

Brian C. Leach, MD

Thomas G. Lewis, MD

Deborah MacFarlane, MD

Cathy A. Macknet, MD

Robert J. MacNeal, MD

David B. Mandell, JD, MBA

Victor J. Marks, MD

Juan-Carlos Martinez, MD

J. Ramsey Mellette, Jr., MD

Christopher J. Miller, MD

Greg S. Morganroth, MD

Kevin J. Mott, MD

Ronald L. Moy, MD

Isaac Neuhaus, MD

Tri H. Nguyen, MD

Suzanne Olbricht, MD

Clark C. Otley, MD

David M. Pariser, MD, FAAD

John C. Perrotto, DO

Jeffrey E. Petersen, MD

Melissa Pugliano-Mauro, MD

Désirée Ratner, MD

Larisa Ravitskiy, MD

Randall K. Roenigk, MD

Heather D. Rogers, MD

Steven M. Rotter, MD

Carl F. Schanbacher, MD

Chrysalyne D. Schmults, MD

Rafael Schulze, MD

Roberta D. Sengemann, MD, FACMS

Brian Somoano, MD

Monika Srivastava, MD

Thomas Stasko, MD

R. Stan Taylor, III, MD

Jens Thiele, MD

Valencia D. Thomas, MD

Maya Thosani, MD

Timothy S. Wang, MD

Carl V. Washington, Jr., MD

Duane C. Whitaker, MD, FACMS

Andrea Willey, MD

Summer R. Youker, MD

Mark J. Zalla, MD

John A. Zitelli, MD

Failed to disclose (Disclosure will be made on-site - all possible conflicts if interest, if applicable, will be resolved prior to talk):

Susan Butler, MD

Scott W. Fosko, MD

Stephen N. Snow, MD

Faculty Disclosure Information

Interests to Disclose/COI/Bias Resolved*:

Mathew M. Avram, MD, JD	Consultant for a Fee – Zeltiq Aesthetics, Inc. Researcher – Candela
Anna A. Bar, MD	Consultant for a Fee – Bioform
Ashish Bhatia, MD	Consultant for a Fee – OrthoNeutrogena, Bioform Medical
Marc D. Brown, MD	Consultant for a Fee – Graceway, Novartis
Joel L. Cohen, MD	Consultant for a Fee – Galderma, Stiefel Consultant for a Fee, Speaker – DUSA Consultant for Fee, Clinical Trials – Allergan, Medicis, Merz Contract Research – Abbott Laboratories, Dow Pharmaceuticals Speaker, Clinical Research Study – Cynosure Shareholder – Medicis
Scott M. Dinehart, MD	Research, Speaker – Syneron
Edgar F. Fincher, MD	Medical Advisory Board – Ulthera
George J. Hruza, MD	Medical Advisory Board – Allergan, Galderma, Stiefel
Jenny J. Kim, MD, PhD	Medical Advisory Board – Candela
Gary Lask, MD	Physician Trainer – Medicis, Dermik Labs
Naomi Lawrence, MD	Consultant for a Fee – Johnson & Johnson/ColBar Investigator – Allergan, Graceway, Medicis Advisory Board, Speaker – DUSA
Ken K. Lee, MD, FACMS	Stockholder – Meridian Skin Care
Peter K. Lee, MD, PhD	Speakers Bureau, Consultant – DUSA
Nanette Liégeois-Kwon, MD, PhD	Consultant for a Fee – Gerson Lehrman Group
Girish S. Munavalli, MD, MHS	Speaker – Candela
Marcy Neuburg, MD, FACMS	Speaker, Advisor – Candela, Medicis
Keyvan Nouri, MD	Research – Merz
Thomas E. Rohrer, MD	Advisory Board – CORIA, Graceway, Medicis, Stiefel
Neil A. Swanson, MD	Advisory Board – Allergan, Bioform, Dermik, Galderma, Kythera, OrthoNeutrogena, Proctor & Gamble, Stiefel
Susan H. Weinkle, MD	Consultant for a Fee – Medicis Speaker – Allergan, Bioform, Dermik, Galderma, OrthoNeutrogena, Proctor & Gamble Stockholder – Derm Advance
Christopher B. Zachary, MD	Speaker, Researcher – Solta Medical Advisory Board – Primaeva Speaker – Cutera

Speaker has indicated that he/she will be discussing the unlabeled use of a commercial product:

Ashish Bhatia, MD will be discussing off label injections of fillers.
Glen M. Bowen, MD will be discussing Imiquimod and Tazarotene as topicals prior to surgical excision for lentigo maligna.
Hayes B. Gladstone, MD will be discussing Endotine for brow lift.
Peter K. Lee, MD, PhD will be discussing Levulan.
Thomas Stasko, MD will be discussing acitretin and capecitabine for metastatic squamous cell carcinoma.
Christopher B. Zachary, MD will be discussing lasers.

*Having a financial interest or other relationship with a corporate organization, **or discussing an unlabeled use of a commercial product**, may not prevent a speaker from making a presentation. However, the existence of the relationship must be made known to the planning committee prior to the conference, so that any possible conflict of interest may be resolved prior to the talk.

Scientific Program—Thursday, April 23

7:00 am – 5:00 pm

Slide Library and Diagnostic

Quality Control Self-Examination

Room 602

7:15 – 8:45 am

Concurrent Morning Mini-sessions

103.1 Nasal Reconstruction

for Medium Sized Defects

Salon J

At the conclusion of this session, participants should be able to:

- 1) Have a better understanding of unique transposition flaps that have been found to be useful for common Mohs defects of the nasal sidewall, dorsal nose, and nose tip,
- 2) Understand how to best provide symmetry, how to maintain an open air way, and how to avoid trapdooring and saddle nose problems,
- 3) Understand the nuanced differences between a good and a great nasal reconstruction.

Richard G. Bennett, MD; Manish J. Gharia, MD

103.2 Melanoma Update

Salon K

At the conclusion of this session, participants should be able to better understand the current concepts of clinical management of melanoma with respect to:

- 1) Initial workup tests,
- 2) Follow-up,
- 3) Sentinel lymph node biopsy, including controversial aspects, comprehensive assessment of the extensive evidence-based data, and its current role and applications,
- 4) Future directions.

Christopher K. Bichakjian, MD; Timothy M. Johnson, MD

103.3 An Approach to Periorbital Reconstruction

Room 400

At the conclusion of this session, participants should be able to:

- 1) Understand the anatomy of the eyelids and periorbital region as it applies to reconstruction,
- 2) Develop a logical approach to repair of the periorbital defects including the need for oculoplastic consultation,
- 3) Anticipate and address complications such as ectropion following eyelid reconstruction.

John G. Albertini, MD; Ken K. Lee, MD, FACMS

103.4 Incorporating Cosmetic Surgery

into a Mohs Practice

Room 412

At the conclusion of this session, participants should be able to:

- 1) Market cosmetic surgery to your Mohs patients with internal marketing,
- 2) Understand the most common cosmetic procedures performed by Mohs surgeons and get advice on how to become proficient in these cosmetic procedures,
- 3) Understand the necessary changes required to transform a Mohs micrographic surgery practice to attract cosmetic surgery patients.

Greg S. Morganroth, MD; Ronald L. Moy, MD

103.5 Immunostaining

Room 408

At the conclusion of this session, participants should be able to:

- 1) Have a practical understanding of the science behind immunostaining in order to incorporate immunostaining and/or troubleshoot common challenges in the Mohs lab,
- 2) Recognize and manage common diagnostic challenges in the interpretation of frozen section immunostains for melanoma,
- 3) Have a comprehensive understanding of the literature to compare the advantages and disadvantages of Mohs surgery versus other surgical approaches to melanoma.

Christopher J. Miller, MD; Gregory M. Bricca, MD

9:00 – 9:30 am

Opening Session

Governor's Ballroom

At the conclusion of this session, participants should be able to recite trends in Mohs surgery and cutaneous oncology as well as socioeconomic issues affecting Mohs surgery.

Duane C. Whitaker, MD, FACMS; David M. Pariser, MD, FAAD

9:30 – 10:30 am

Tromovitch Award Abstracts

Governor's Ballroom

At the conclusion of this session, participants should:

- 1) Become updated on recent advances in cutaneous oncology and pathology,
- 2) Become aware of the current state of the practice of Mohs surgery,
- 3) Learn about young investigators research and scholarly activities.

Moderators: Murad Alam, MD; Valencia D. Thomas, MD

9:34 – 9:42 am

Surgical Margins for Excision of Melanoma in Situ

Joy H. Kunishige, MD; John A. Zitelli, MD; David G. Brodland, MD, FACMS

9:42 – 9:50 am

Office Surgery Incidents: What Nine Years of Florida Data Show Us

Maya Thosani, MD; Brett M. Coldiron, MD, FACP, FACMS

9:50 – 9:58 am

The Public's Perception of Dermatologists as Surgeons

Vinh Q. Chung, MD; Herbert Alexander, MD; Michelle Pavlis, BS; Melissa Alexander, PhD; Suephy Chen, MD, MS; Carl V. Washington, Jr., MD

9:58 – 10:06 am

Safety and Efficacy of Oral Midazolam for Perioperative Anxiolysis of Patients Undergoing Mohs Surgery

Larisa Ravitskiy, MD; Randall K. Roenigk, MD; P. Kim Phillips, MD; Amy Weaver; Jill Killian; Clark C. Otley, MD

Scientific Program—Thursday, April 23

10:06 – 10:14 am

Mohs Surgery for Periocular Skin Cancers: A Retrospective Series of 553 Cases

Jens Thiele, MD; Gary D. Monheit, MD; Christopher B. Harmon, MD

10:14 – 10:22 am

Mohs Surgery is Effective for High-Risk Squamous Cell Carcinoma

Melissa Pugliano-Mauro, MD; Glenn D. Goldman, MD

10:22 – 10:30 am

Sebaceous Carcinoma of the Eyelids Treated with Mohs Micrographic Surgery

Humza Ilyas, MD; Nancy Kim, MD, PhD; Regina M. Yavel, MD; Mark Lucarelli, MD; John G. Rose, MD; Stephen N. Snow, MD

10:30 – 10:45 am

Break

10:45 – 11:45 am

How Would You Reconstruct It?

(Interactive Polling)

Governor's Ballroom

At the conclusion of this session, participants should be able to:

- 1) Consider several reconstructive options for any surgical defect,
- 2) Understand the pros and cons of alternative reconstructive techniques.

Moderators: Anna A. Bar, MD; Glenn D. Goldman, MD

Panelists: Sumaira Z. Aasi, MD, FACMS; David G. Brodland, MD, FACMS; Joel W. Cook, MD; Todd E. Holmes, MD

11:45 am – 1:00 pm

Lunch (provided in Exhibit Hall)

Salon H

12:00 – 6:30 pm

Exhibit Hall Open

Salon H

1:00 – 2:00 pm

Revision Surgery

Governor's Ballroom

At the conclusion of this session, participants should be able to:

- 1) Rethink concepts of undermining, eversion, and suturing in surgical scar,
- 2) Appreciate revision options for the lip and nasal ala,
- 3) Understand the importance of the nasal valve in reconstructive surgery.

Moderator: Tri H. Nguyen, MD

1:00 – 1:17 pm

Optimal Scar: Paradigm Shifts

Tri H. Nguyen, MD

1:17 – 1:34 pm

Revision of Lip Repairs

Richard G. Bennett, MD

1:34 – 1:51 pm

Revision of the Nasal Ala and Valve

Andrew J. Kaufman, MD, FACP

2:00 – 3:00 pm

Controversies in Mohs Surgery

(Interactive Polling)

Governor's Ballroom

At the conclusion of this session, participants should be able to:

- 1) Select appropriate therapy for complex patients with difficult-to-manage tumors,
- 2) Appreciate the potential role of cetuximab in the management of recurrent or metastatic squamous cell carcinoma,
- 3) Understand the role of adjuvant radiation therapy in the treatment of basal cell carcinoma,
- 4) Understand the strengths and limitations in the use of frozen sections in the surgical management of sebaceous carcinoma.

Moderators: Désirée Ratner, MD; Summer R. Youker, MD

2:00 – 2:20 pm

Controversy #1: Should this transplant patient, with metastatic SCC, receive cetuximab?

Presenter: Hillary Johnson-Jahangir, MD, PhD

Pro: Monica Halem, MD

Con: Thomas Stasko, MD

2:20 – 2:40 pm

Controversy #2: Should this patient, with an incompletely excised large perineural BCC, receive postoperative radiation therapy?

Presenter: Heather D. Rogers, MD

Pro: Timothy S. Wang, MD

Con: Carl V. Washington, Jr., MD

2:40 – 3:00 pm

Controversy #3: Should Mohs surgery with frozen sections be performed on this patient with sebaceous carcinoma of the eyelid?

Presenter: Susan Butler, MD

Pro: John A. Zitelli, MD

Con: Roberta D. Sengemann, MD, FACMS

3:00 – 3:30 pm

Break; visit the Exhibit Hall and Posters

Salon H

Scientific Program—Thursday, April 23

3:30 – 4:30 pm

Research Abstract Session

Governor's Ballroom

At the conclusion of this session, participants should be able to understand and identify new research developments in Mohs surgery and oncology.

Moderators: Marcy Neuburg, MD, FACMS; Isaac M. Neuhaus, MD

3:33 – 3:41 pm

Innovative 19 Minute Rapid Cytokeratin Immunostaining of Non-melanoma Skin Cancer in Mohs Micrographic Surgery

Basil S. Cherpelis, MD; Logan Turner, MD; Sharron Ladd, BS; L. Frank Glass, MD; Neil Fenske, MD

3:41 – 3:49 pm

Topical Imiquimod Versus Imiquimod and Tazarotene for Lentigo Maligna Followed by Staged Excision

Glen M. Bowen, MD; Mark A. Hyde, MMS, PA-C

3:49 – 3:57 pm

Complications of Cutaneous Surgery in Patients Who Are Taking Clopidogrel

Robert H. Cook-Norris, MD; Jason D. Michaels, MD; P. Kim. Phillips, MD; M. Amanda Jacobs, MD; Randall K. Roenigk, MD; Clark C. Otley, MD

3:57 – 4:05 pm

Treatment of Rare and Uncommon Non-melanoma Tumors by Mohs Surgery: A Meta-Analysis of 1232 Cases

Murad Alam, MD; Christopher Wickman, M4; Daniel Danahey, MD; Simon S. Yoo, MD; Natalie Kim, BS Clinical; Alfred Rademaker, PhD

4:05 – 4:13 pm

Malignant Melanoma in Solid Transplant Recipients, Collection of Database Cases with Comparison to SEER Data for Outcome Analysis

Jerry D. Brewer, MD; Leslie J. Christenson, MD; Amy L. Weaver; Roger Veenig; Katherine K. Lim, MD; James H. Keeling, MD; Clark C. Otley, MD

4:13 – 4:21 pm

Mohs Micrographic Surgery for the Treatment of Lentigo Maligna, the University Experience

Robert J. MacNeal, MD; Christopher J. Arpey, MD; Carrie E. Cera-Hill; Marta J. Van Beek, MD

4:30 – 5:30 pm

Reconstructive Challenges:

The Full Thickness Defect

Governor's Ballroom

At the conclusion of this session, participants should be able to:

- 1) Understand the challenge of full thickness defects in regards to potential functional and aesthetic problems,
- 2) Formulate an appropriate reconstructive plan to ensure restoration of form and function,
- 3) Learn the operative techniques likely to yield durable and reproducible repair.

Moderator: Joel Cook, MD

4:30 – 4:50 pm

Full Thickness Eyelid Repairs

J. Ramsey Mellette, Jr., MD

4:50 – 5:10 pm

Full Thickness Nasal Repairs

Jonathan L. Cook, MD

5:10 – 5:30 pm

Full Thickness Lip Repairs

Tri H. Nguyen, MD

5:30 – 7:00 pm

Welcome Reception in Exhibit Hall

Salon H



Scientific Program—Friday, April 24

7:00 am – 5:00 pm

Slide Library and Diagnostic Quality Control

Self-Examination

Room 602

7:15 – 8:45 am

Concurrent Morning Mini-sessions

203.1 Setting Up a Mohs

Histopathology Laboratory

Room 410

At the conclusion of this session, participants should be able to:

- 1) Understand the regulatory requirements of establishing a Mohs laboratory; including space requirements, equipment needs, and maintenance,
- 2) Utilize the quality control resources and proficiency testing available.

Stephen N. Snow, MD; Frederick S. Fish, III, MD

203.2 Role of Imaging in

Non-melanoma Skin Cancer

Room 400

At the conclusion of this session, participants should be able to:

- 1) Utilize radiologic imaging techniques in the management of difficult cases of non-melanoma skin cancer,
- 2) Understand the principles of available imaging modalities as well as the power and limitations of each modality,
- 3) Understand indications for pre and postoperative imaging with regard to non-melanoma skin cancer,
- 4) Understand how to choose the best imaging study for a specific clinical indication.

Deborah MacFarlane, MD; Tatyana R. Humphreys, MD

203.3 Perioral Reconstruction

Salon J

At the conclusion of this session, participants should be able to:

- 1) Approach perioral reconstruction in a systematic fashion. This will be accomplished by breaking down the area into four reconstructive subunits: central lip including Cupid's bow and philtral defects, medial lip adjacent to the lateral aspect of the philtrum, lateral lip, and apical lip,
- 2) Understand techniques to repair "wet," "dry," and combination defects,
- 3) Understand standard reconstructive approaches for the lower lip and learn several "out of the box" options.

J. Ramsey Melleite, Jr., MD; Roberta D. Sengelmann, MD, FACMS

203.4 CPC: Challenging Cutaneous Tumors

Room 412

At the conclusion of this session, participants should be able to:

- 1) Identify key diagnostic and management issues regarding the care of patients with complex cutaneous malignancies,
- 2) Establish a framework for a comprehensive and appropriate work-up for complex or uncommon cutaneous malignancies,
- 3) Identify when Mohs micrographic surgery alone may be insufficient for adequate patient management, and multidisciplinary care may be of benefit.

Christopher J. Arpey, MD; Marc D. Brown, MD; Leslie J. Christensen, MD

203.5 Regional Reconstruction

Room 408

At the conclusion of this session, participants should be able to:

- 1) Have a better understanding of the dynamics in place for a variety of local flaps and why certain flaps are used more often,
- 2) Have a better idea of why small adjustments to certain flaps can have a major impact on the final aesthetic outcome,
- 3) Have a more clear understanding of which flaps work best for certain defects, and have an algorithm to go through for many specific regions of the face.

Andrew J. Kaufman, MD, FACP; Thomas E. Rohrer, MD

203.6 Managing Lower Extremity

Cancers and Defects

Salon K

At the conclusion of this session, participants should be able to:

- 1) Understand different treatment modalities for patients with multiple squamous cell carcinomas of the lower extremities,
- 2) Evaluate approaches to Mohs surgery in patients with lymphedema, lipodermatosclerosis, and scleroderma,
- 3) Discuss treatment options with Achilles tendon exposure.

Peter K. Lee, MD, PhD; Jeffrey E. Petersen, MD

9:00 – 10:00 am

Coding Conundrums

(Interactive Polling)

Governor's Ballroom

At the conclusion of this session, participants should be able to:

- 1) Be familiar with recent changes regarding coding for Mohs micrographic surgery,
- 2) Code correctly for Mohs excisions and common types of reconstruction,
- 3) Be aware of various "gray areas" in coding with regard to Mohs and reconstruction.

Moderator: Mark J. Zalla, MD

Panelists: Brett M. Coldiron, MD, FACP, FACMS; Glenn D. Goldman, MD; John A. Zitelli, MD

10:00 – 11:00 am

Applying Rhinoplasty Principles

to Nasal Reconstruction

Governor's Ballroom

—featuring guest speaker Shan R. Baker, MD

At the conclusion of this session, participants should be able to:

- 1) Understand alternatives for reconstruction of nasal lining defects,
- 2) Recognize the importance of structural support and options for providing nasal support during reconstruction of deep nasal defects,
- 3) Understand the variety of nasal cutaneous flaps available for repair of small nasal cutaneous defects and the appropriate indications for each flap.

Moderator: Neil A. Swanson, MD

Panelist: Shan R. Baker, MD

11:00 – 11:15 am

Break

Scientific Program—Friday, April 24

11:15 am – 12:15 pm

Mohs Histopathology Conundrums

(Interactive Polling)

Governor's Ballroom

At the conclusion of this session, participants should be able to:

- 1) Troubleshoot common technical problems to obtain quality histopathology slides,
- 2) Differentiate false positives/false negatives when reading Mohs histopathology,
- 3) Appreciate and discuss complex histopathology and the conundrums in frozen sections.

Moderator: Sumaira Z. Aasi, MD, FACMS

Panelists: Todd E. Holmes, MD; Nanette Liégeois-Kwon, MD, PhD; Carl G. Schanbacher, MD

12:00 – 6:00 pm

Exhibit Hall Open

Salon H

12:15 – 1:30 pm

ACMS Annual Business Meeting and Lunch

Salon J & K

Non-members and guests lunch on own; visit the Exhibit Hall

1:30 – 2:30 pm

The Undesirable Result in

Reconstructive Surgery

Governor's Ballroom

At the conclusion of this session, participants should be able to thoughtfully analyze less desirable results in facial reconstructive surgery in order to determine sources of potential error in operative design or surgical technique.

Moderator: Jonathan L. Cook MD

Panelists: Shan R. Baker, MD; Leonard M. Dzubow, MD, FACMS; Tatyana R. Humphreys, MD; Steven M. Rotter, MD

2:30 – 3:00 pm

Break; visit the Exhibit Hall and Posters

Salon H

3:00 – 4:00 pm

Clinical Pearls Abstract Session

Governor's Ballroom

This new session highlights practical pearls submitted by our members.

Moderators: Scott W. Fosko, MD; Suzanne Olbricht, MD

3:03 – 3:11 pm

Nasal Valve Repair Using Double Lateral Suture Suspension

Thomas G. Lewis, MD; Heidi B. Donnelly, MD

3:11 – 3:19 pm

The Hughes Tarsoconjunctival Flap: A Useful Flap for Repair of Full-Thickness Lower Eyelid Defects Following Mohs Surgery

Kevin J. Mott, MD

3:19 – 3:27 pm

Revisionary Technique for Alar Rim Notching: The Stair-Step Flap

Brian C. Leach, MD; Joel Cook, MD

3:27 – 3:35 pm

Reconstruction Pearl: A Proximally-based Alar Hinge Flap for a Nasal Soft Triangle Defect

Michael W. Chen, MD; Richard G. Bennett, MD

3:35 – 3:43 pm

Standardized Photography in Facial Reconstructive Surgery: Clinical Pearls to Simplify a Complicated Task

Juan-Carlos Martinez, MD

3:43 – 3:51 pm

Using Rotation Flaps to Repair Large Scalp Defects without the Aid of Tissue Expanders

Ravi S. Krishnan, MD

4:00 – 5:00 pm

Afternoon at the Movies

Governor's Ballroom

At the conclusion of this session, participants should be able to understand how leading experts design and execute:

- 1) A bilobe flap and helical rim rotation flap,
- 2) An island pedicle flap and forehead flap,
- 3) A cheek interpolation flap and manipulate cartilage during certain reconstructive procedures.

Moderators: Thomas E. Rohrer, MD; Roberta D. Sengelmann, MD, FACMS

4:00 – 4:10 pm

Variations on the Bilobe Flap

Heidi B. Donnelly, MD

4:10 – 4:20 pm

Helical Rim Rotation Flap

R. Stan Taylor, III, MD

4:20 – 4:30 pm

Island Pedicle Flap

David G. Brodland, MD, FACMS

4:30 – 4:40 pm

Forehead Flap

Steven M. Rotter, MD

4:40 – 4:50 pm

Cheek Interpolation Flap

John A. Zitelli, MD

4:50 – 5:00 pm

Cartilage Manipulation in Surgical Reconstruction

Leonard M. Dzubow, MD, FACMS

5:00 – 6:00 pm

Visit the Exhibit Hall and Posters

Salon H

Scientific Program—Saturday, April 25

7:00 am – 2:00 pm

Slide Library and Diagnostic Quality Control

Self-Examination

Room 602

7:15 – 8:45 am

Concurrent Morning Mini-sessions

304.1 Advanced Reconstruction:

From Plastics to Mohs

Salon J

At the conclusion of this session, participants should be able to:

- 1) Recognize reconstructive biases derived from formal training in plastic surgery,
- 2) Understand how plastic surgeons' approach to reconstruction has evolved over the course of a Mohs practice,
- 3) Incorporate new techniques into the reconstruction of Mohs defects,
- 4) Modify Mohs resection techniques in special reconstructive situations.

Stephen D. Antrobus, MD; Bryce J. Cowan, MD

304.2 Beyond the Basics: Advanced Nail Surgery Room 400

At the conclusion of this session, participants should be able to:

- 1) Reliably achieve appropriate wide surgical exposure of the nail apparatus, through novel avulsion techniques in a bloodless field,
- 2) Perform Mohs surgery for nail tumors, including a technique utilizing nail anatomic and histologic subunits,
- 3) Perform a wide range of nail surgeries for common indications such as longitudinal melanonychia and longitudinal erythronychia,
- 4) Design and perform a variety of nail flaps.

Siobhan C. Collins, MD; Nathaniel J. Jellinek, MD

304.3 Ear Reconstruction

Salon K

At the conclusion of this session, participants should be able to:

- 1) Have a better understanding of the surgical anatomy of the ear,
- 2) Have an improved ability to assess wounds of the ear with regards to whether or not reconstruction is necessary,
- 3) If reconstruction is necessary the participant will be aware of numerous options for reconstruction of each type of defect based on both the extent of the defect and the location on the ear,
- 4) Generate multiple reconstructive options for most wounds,
- 5) Have a better understanding of how to execute flaps, grafts and multistage procedures for closure.

Christie T. Ammirati, MD; David G. Brodland, MD, FACMS

304.4 Advanced Blepharoplasty Room 412

At the conclusion of this session, participants should be able to:

- 1) Understand eyelid aesthetics and what makes a "beautiful" eye,
- 2) Manage upper eyelid lateral hooding and lower eyelid skin laxity,
- 3) Avoid ectropion with lower eyelid blepharoplasty,
- 4) Combine techniques to achieve the beautiful eye (laser resurfacing, canthopexy, browpexy, brow lift).

Hayes B. Gladstone, MD; Edgar F. Fincher, MD

304.5 Lasers for the Mohs Surgeon

Room 408

At the conclusion of this session, participants should be able to:

- 1) Understand the types of lasers available in practice today,
- 2) Classify basic indications for each type of laser, including scars, vascular lesions, acne, pigmented lesions, tattoos, hair removal, hypopigmentation/vitiligo/psoriasis,
- 3) Implement appropriate pre-, intra-, and post-laser treatment plans.

George J. Hruza, MD; Andrea Willey, MD; Keyvan Nouri, MD

8:30 am – 2:00 pm

Exhibit Hall Open

Salon H

9:00 – 10:30 am

Concurrent Scientific Sessions

306.1 Tumor Board (9:00 – 10:30 am)

Salon K

At the conclusion of this session, participants should be able to:

- 1) Discuss the clinicopathologic correlation of high risk skin cancers,
- 2) Recognize when a patient may require preoperative radiologic imaging for high risk skin cancers,
- 3) Appreciate the various approaches to high risk skin cancer and adjuvant diagnostic and therapeutic modalities.

Moderators: Clark C. Otley, MD; Chrysalyne D. Schmults, MD; Timothy S. Wang, MD

Panelists: Shan R. Baker, MD; John A. Carucci, MD, PhD; Victor J. Marks, MD; Désirée Ratner, MD

306.2 Morning at the Movies:

Cosmetic Surgery (9:00 – 10:00 am)

Salon J

At the conclusion of this session, participants should be able to:

- 1) Understand the implementation of endovenous techniques and sclerotherapy in patients with venous disease,
- 2) Understand indications of new fillers and expanded use of current fillers,
- 3) Understand and utilize updated techniques for laser rejuvenation and non-surgical fat dissolution.

Moderators: Gary Lask, MD; Naomi Lawrence, MD

Update on Sclerotherapy and Endovenous Procedures

Girish S. Munavalli, MD, MHS

New Fillers and New Uses for Fillers

Naomi Lawrence, MD

Laser Rejuvenation Practical Pearls

Gary Lask, MD

Fat Dissolution

Mathew M. Avram, MD, JD

Scientific Program—Saturday, April 25

306.3 Managing Cosmetic Patients: Conversation with the Experts (10:00 – 10:30 am)

Salon J

At the conclusion of this session, participants should be able to:

- 1) Evaluate the needs of the cosmetic patient,
- 2) Describe various minimally invasive cosmetic procedures,
- 3) Assess the appropriate cosmetic procedure for specific cosmetic indications.

Moderator: Hayes B. Gladstone, MD

Panelists: Ronald L. Moy, MD; Christopher B. Zachary, MD

10:30 – 11:00 am

Break; visit the Exhibit Hall and Posters

Salon H

11:00 am – 12:00 pm

Challenging Cases from Dallas

Governor's Ballroom

—featuring guest speaker Clay J. Cockerell, MD

At the conclusion of this session, participants should be able to:

- 1) Develop new insights into the diagnosis and management of less common malignancies of the skin,
- 2) Gain greater appreciation for the synergistic role played by dermatopathologists in the Mohs practice.

Moderator: R. Stan Taylor, III, MD

Panelist: Clay J. Cockerell, MD

12:00 – 1:00 pm

Research Abstract Session

Governor's Ballroom

At the conclusion of this session, participants should be able to understand and identify new research developments in Mohs surgery and oncology.

Moderators: Jenny J. Kim, MD, PhD; Susan H. Weinkle, MD

12:03– 12:11 pm

Can Flash Freezing of Mohs Layers Expedite Slide Turn Around Time and Minimize Sample Distortion (Freezing Artifact)?

Quenby L. Erickson, DO; Trishina Clark; Kassandra Larson; Tri H. Nguyen, MD; T. Minsue Chen, MD

12:11– 12:19 pm

Mohs Micrographic Surgery for the Treatment of Atypical Fibroxanthoma

Christian L. Baum, MD; Marta J. Van Beek, MD; Christopher J. Arpey, MD

12:19 – 12:27 pm

The Value of Immunohistochemistry in Discriminating Primary from Secondary Extramammary Paget's Disease

John C. Perrotto, DO; Roger I. Ceilley, MD; Jared Abbott; Ifrikhar Ahmed, MD

12:27 – 12:35 pm

Floater in Mohs Micrographic Surgery: Expert Consensus of Mohs Surgeons and Histotechnologists

Murad Alam, MD; Sumaira Z. Aasi, MD, FACMS; Ashish Bhatia, MD; Steven J. Goulder, MD; Vivek Iyengar, MD; Nanette Liégeois-Kwon, MD, PhD; Kishwer S. Nehal, MD; Anjali D. Shah, MD

12:35 – 12:43 pm

An Automated 16-Minute Technique for Processing Mohs Sections for Melanoma

Kyung H. Chang, MD, PhD; Daniel T. Finn, MD; Dennis Lee, MD; Gary S. Rogers, MD

12:43 – 12:51 pm

Randomized Controlled Trial: Rapid Absorbing Gut Suture Versus Tissue Adhesive in the Closure of Linear Repairs

Emily P. Tierney, MD; David J. Kouba, MD, PhD; Ronald L. Moy, MD

12:51 – 12:59 pm

Subclinical Spread of Amelanotic vs. Pigmented Melanomas: Amelanotic Tumors Require More Stages of Mohs Surgery

Aerlyn G. Dawn, MD, MBA; Christopher J. Miller, MD

1:00 – 2:30 pm

WDS Networking Luncheon

(Advance Ticket Required—

See pg. 9 for more information)

Room 400

1:00 – 3:00 pm

Industry Sponsored Session: Advanced Asset Protection, Tax and Estate Planning for Mohs Surgeons

Salon J

At the conclusion of this session, participants should be able to:

- 1) Understand the pro/cons of different practice structure options (C & S corporations, multiple entities, etc.),
- 2) Appreciate how a self-funded Exit Strategy can be built into a medical practice structure and benefit offerings,
- 3) Make sense of the “sliding scale of asset protection” and “tax diversification” and how one might take advantage of both,
- 4) Identify the #1 risk of qualified retirement plans (401(k)s, profit-sharing plans, etc.) and understand other options for medical practice,
- 5) Appreciate the 16-44% investment trap most doctors get caught in – even when the market is rising.

An additional 4 Category 1 CME credit hours are available if attending this session. See pgs. 9 and 14 for more information.

Speakers: David B. Mandell, JD, MBA; Christopher R. Jarvis, MBA, of O'Dell Jarvis Mandell, LLC

Scientific Program—Saturday, April 25

2:00 pm

Exhibit Hall and Posters Close

Salon H

3:00 – 5:00 pm

Practical Issues in Practicing

Mohs Surgery

Governor's Ballroom

At the conclusion of this session, participants should be able to:

- 1) Learn about various practice management and development issues involved in running a Mohs surgery practice,
- 2) Apply new management techniques to improve one's practice.

This session will be particularly helpful for current and recent fellows.

Moderator: Andrew J. Kaufman, MD, FACP

3:00 – 3:20 pm

Hanging up Your Shingle: Deciding between Different Practice Types

Monika Srivastava, MD

3:20 – 3:40 pm

Marketing Your Mohs Practice Most Effectively

Andrew J. Kaufman, MD, FACP

3:40 – 4:00 pm

How to Make Your Mohs Practice Most Efficient

Glenn D. Goldstein, MD

4:00 – 4:20 pm

Coding, Billing, and Collecting: Getting Paid for Your Work

Scott M. Dinehart, MD

4:20 – 4:40 pm

Benefits and Drawbacks of an Ambulatory Surgery Center: What Should You Do?

Ronald L. Moy, MD

4:40 – 5:00 pm

When is a Satellite Office a Good Choice?

Christopher B. Harmon, MD

4:00 – 5:00 pm

Fellowship Training Committee Meeting

Room 403

5:00 – 6:00 pm

Fellowship Training Directors' Session

Salon J

6:00 – 7:30 pm

Fellows-in-Training Reception

Salon K



Scientific Program—Sunday, April 26

7:15 – 8:45 am

Concurrent Morning Mini-sessions

402.1 Reconstruction of the Face with Cutaneous Flaps

Room 400

At the conclusion of this session, participants should be able to:

- 1) Illustrate the reconstruction of various facial wounds with local flaps,
- 2) Understand the design modifications of flaps that produce more optimal surgical outcomes,
- 3) Explain the surgical techniques that promote more aesthetically suitable operative results.

Jonathan L. Cook, MD; Glenn D. Goldman, MD

402.2 Nasal Reconstruction:

Classic and Unconventional

Salon K

At the conclusion of this session, participants should be able to:

- 1) Understand the importance of functional and aesthetic nasal reconstruction following Mohs surgery,
- 2) Review the classical methods of nasal repair with particular emphasis on flap reconstructive surgery,
- 3) Explore unconventional methods of nasal reconstruction including, but not limited to, tunneled flaps, composite repairs, hinge flap repairs, unusual variations of conventional flaps, and other advanced reconstructive dermatologic surgical procedures,
- 4) Compare the advantages and disadvantages of conventional and unconventional repair techniques.

Joel Cook, MD; Tri H. Nguyen, MD

USED IN OVER 1,000 OFFICES
INTERNATIONALLY,

The **cryoEMBEDDER®**

- Adapts to all makes of cryostats
- Fast turn around time
- Ergonomic design
- Add more patients to surgery schedule
- Pays for itself with one Mohs surgery
- Unlimited (800) Tech Support
- Lifetime warranty



cryoEMBEDDER®

Patented
System



The **cryoEMBEDDER®** has revolutionized the process of preparing fresh tissue for frozen sectioning.

It provides quick and precise tissue sample preparation by speeding up the embedding process and enhancing the quality of slides for diagnosis.



Mohs Training Workshop

- Courses for beginners and experienced technicians
- 3 day training: Thur., Fri., and Sat.
- Hands-on training with 10 hours cutting time
- Variety of methods demonstrated
- HT ASCP certified instructors
- Workshop fees include room, meals, and materials

3434 East 7800 South #131
Salt Lake City, UT 84121
Fax: 801-453-0187

1-800-447-0718

www.cryoembedder.com

Scientific Program—Sunday, April 26

402.3 Coding for Mohs Surgeons

Salon J

At the conclusion of this session, participants should be able to:

- 1) Cope with the loss of the Mohs multiple surgery exemption,
- 2) Utilize the latest coding information,
- 3) Be aware of the advantages of having their own permanent section laboratory.

Brett M. Coldiron, MD, FACP, FACMS; Randall K. Roenigk, MD

9:00 – 9:50 am

Diagnostic Quality Control Exam Review Governor's Ballroom

At the conclusion of this session, participants should be able to understand the importance of dermatopathology in Mohs surgery.

Moderator: Frederick S. Fish, III, MD

9:50 – 10:00 am

Break

10:00 am – 12:00 pm

Cosmetic Symposium Governor's Ballroom

At the conclusion of this session, participants should be able to:

- 1) Understand new approaches to filler, photodynamic therapy, and fractional resurfacing enabling them to expand their use of these techniques,
- 2) Utilize cyanoacrylate tissue adhesive to enhance the results of their face lift and learn to select patients, in which chin implants provide an alternative to face lifts,
- 3) Use a carbon dioxide laser to rejuvenate the lower eyelids and use a chin implant to substitute for a face lift in men with weak chins.

Moderators: Greg S. Morganroth, MD; Girish S. Munavalli, MD, MHS

10:00 – 10:10 am

Intraoral Access for Volumetric Correction of the Upper Face

Girish S. Munavalli, MD, MHS

10:10 – 10:20 am

Photodynamic Therapy for Prevention of Skin Cancer: My Techniques

Joel L. Cohen, MD

10:20 – 10:30 am

Questions

10:30 – 10:50 am

Vertical Vector Face Lift with Cyanoacrylate Tissue Adhesive

Greg S. Morganroth, MD

10:50 – 11:00 am

Chin Implants: A Facelift Alternative for Men?

Rafael Schulze, MD

11:00 – 11:10 am

Inner Thigh Liposuction: Achieving Even Contours

Jennifer L. Reichel, MD

11:10 – 11:20 am

Questions

11:20 – 11:30 am

Carbon Dioxide Transconjunctival Blepharoplasty

Cathy A. Macknet, MD

11:30 – 11:40 am

Tumescent Anesthesia of the Face for Laser Resurfacing

Brian Somoano, MD

11:40 – 11:50 am

Resurfacing of the Neck and Chest: Novel Frontiers with Fractionated CO₂

Ashish Bhatia, MD

11:50 am – 12:00 pm

Questions

12:00 pm

Meeting adjourns



Jromovitch Award Abstract Session—Thursday, April 23; 9:30 – 10:30 am

9:34 – 9:42 am

PRESENTER: Joy H. Kunishige, MD

TITLE: Surgical Margins for Excision of Melanoma in Situ

AUTHORS: Joy H. Kunishige, MD; John A. Zitelli, MD; David G. Brodland, MD, FACMS

Purpose: Although 5 mm margins are frequently recommended for excision of melanoma in situ, several studies have shown 5 mm margins to be inadequate. Further, dermatologists are increasingly managing melanoma in situ and inadequate treatment frequently leads to recurrence as invasive melanoma. It is time to reconsider the guideline in view of new evidence since the 1992 consensus.

Our purpose was to develop evidence-based guidelines for predetermined surgical margins for excision of melanoma in situ.

Design: A prospectively collected series of 1256 consecutive patients with 1330 melanoma in situs was studied. All lesions were excised by means of fresh tissue technique of Mohs micrographic surgery with frozen section examination of the margin. After 2003, MART-1 immunostains were used. The surgical margin needed for excision of melanoma was determined by measuring the invisible extensions of tumor around the melanoma. The minimal surgical margin was 6 mm and the total margin was calculated by adding additional 3 mm for each subsequent stage to remove the tumor completely.

Summary: 84.96 percent of melanoma in situs were successfully excised with a 6 mm margin. 9 mm removed 99.1% of melanoma in situs. Margins to remove melanoma in situs on the face were greater than that for other locations (scalp, neck, trunk, extremities, hands and feet). Margins to remove melanomas more than 2 cm in diameter were greater than that for smaller-diameter melanomas.

Conclusions: The frequently recommended 5 mm margin for melanoma is inadequate. Predetermined surgical margins for standard surgical excision should include 9 mm of normal-appearing skin for melanoma in situs. Larger margins should be considered when possible for melanoma in situ located on the face or greater than 2 cm in diameter. Required width of surgical margins for melanoma in situ is similar to that recommended for early invasive melanoma.

9:42 – 9:50 am

PRESENTER: Maya Thosani, MD

TITLE: Office Surgery Incidents: What Nine Years of Florida Data Show Us

AUTHORS: Maya Thosani, MD; Brett M. Coldiron, MD, FACP, FACMS

Purpose: There are increasing amounts of medical legislation that are being passed in an endeavor to protect patients, and reduce medical errors. In this effort, state medical boards

and legislatures are drafting regulations which will have a considerable impact on patient access to medically necessary procedures, and should therefore be based on sound data. This report summarizes 9 years of prospective data from the state of Florida, the best data available on office surgery incidents.

The objective was to determine the nature and incidence of hospital transfers and deaths resulting from physician office procedures.

Design: This study is a compilation of mandatory reporting by Florida physicians to a central agency of all in-office adverse incidents resulting in death, serious injury, or hospital transfer in the state of Florida from March 2000 to the present. Telephone and internet follow-up was conducted to determine physician board certification, hospital privileges, and office accreditation.

Summary: Analysis of 9 years of data shows that approximately half the injuries and deaths are due to cosmetic procedures performed under general anesthesia by plastic surgeons. The remainder of deaths and injuries are a wide mix of medically necessary procedures.

Conclusions: The data does not support that requiring board certification, office accreditation, or hospital privileges would improve matters. There were no deaths attributed to dermatologists, and no injuries or deaths from Mohs surgery or liposuction performed with dilute local anesthesia.

We also report on mandatory reporting from other states and compare this to the Florida data.

9:50– 9:58am

PRESENTER: Vinh Q. Chung, MD

TITLE: The Public's Perception of Dermatologists as Surgeons

AUTHORS: Vinh Q. Chung, MD; Herbert Alexander, MD; Michelle Pavlis, BS; Melissa Alexander, PhD; Suephy Chen, MD, MS; Carl V. Washington, Jr., MD

Purpose: Although dermatologists perform more surgical procedures to treat skin cancers than physicians from any other medical specialty, some patients may not be aware that skin surgery is an integral component of the training and practice of dermatologists. We hoped to determine whether dermatology patients and the general population have preconceived ideas regarding the ability of different medical specialists to perform skin surgeries.

Design: We recruited subjects from 2 sites: the university student center (N=250) and the clinic (N=250). The majority of the subjects from the first site were students while those from the second site were patients and/or their family members.

Participating subjects were asked to complete a 15-question survey regarding the relative skill levels of five medical specialists—dermatologists, emergency medicine physicians, family practitioners, general surgeons, and plastic surgeons.

Jromovitch Award Abstract Session—Thursday, April 23; 9:30 – 10:30 am

They then rated the cosmetic appearance of a set of 16 images of surgical scars using a visual analog scale ranging from 1 to 10. The 16 images were duplicated and arranged in the same order in four different binders. A label under each image indicated that the surgery was performed by a dermatologist, plastic surgeon, general surgeon, or "unknown." The label differed in each binder for the exact same image; i.e., in binder A, image #1 read "dermatologist," in binder B, it read "general surgeon," in binder C, "plastic surgeon," and in binder D, "unknown." Subjects were given only one binder to rate, and the binders were rotated with each subsequent subject.

For images designated "unknown," the subjects were asked to specify which of the three medical specialists (i.e., dermatologist, plastic surgeon, or general surgeon) he/she believed performed the surgery based on the cosmetic appearance of the scar. This helped determine if a bias existed towards a particular medical specialist.

Summary: Results from both sites were similar and statistically significant. Plastic surgeons received the highest rating when subjects were asked which medical specialist is capable of achieving the best result when performing skin surgery. Dermatologists received the second highest score, followed by general surgeons.

Plastic surgeons received the highest score for all parameters related to skin surgery: level of training, number of surgical procedures performed, advanced surgical instruments, advanced surgical skills, confidence in performing skin surgery on the face for cosmetic reasons, and confidence in performing skin surgery on the face to treat skin cancer. Dermatologists and general surgeons shared the second and third rank for most of these parameters. When the subjects were asked who performed the greatest number of surgical procedures in the past year, dermatologists ranked 4th, behind plastic surgeons, general surgeons, and emergency medicine physicians. The majority of subjects at both sites did not perceive dermatologists as surgical specialists.

Subjects generally perceived scars as more cosmetically acceptable if they believed the scars were created by a plastic surgeon. Images labeled "plastic surgeon" received higher scores for cosmetic appearance than images labeled "dermatologist," "general surgeon," and "unknown." Subjects also attributed the more cosmetically acceptable scars to plastic surgeons. Statistical analyses are pending.

Conclusions: The public has preconceived ideas about which medical specialists have the greatest ability to perform cutaneous surgeries and leave cosmetically acceptable scars. Beyond their reported biases, the subjects' own evaluation of the cosmetic appearance of a scar is influenced by who they think performed the surgery.

Subjects reported the greatest confidence in plastic surgeons in performing skin surgery for cosmetic reasons as well as for treatment of skin cancer. They also reported that plastic surgeons have the greatest level of training, do the greatest number of surgical procedures, have the most advanced instruments, and have the most advanced surgical techniques. Dermatologists received evaluations comparable to general surgeons. Subjects in general did not perceive dermatologists as surgical specialists.

When evaluating a surgical scar, subjects more frequently attributed cosmetically acceptable scars to plastic surgeons than to dermatologists or general surgeons. They also perceived scars as more cosmetically acceptable if they believed that the scars were created by a plastic surgeon than if they thought the scars had been created by a dermatologist or a general surgeon.

Since dermatologists perform more skin cancer surgeries than any other medical specialist and since the patient's confidence in the physician is integral to the patient-doctor relationship, dermatologists must continue to educate the public about the depth and breadth of our field. We must also identify strategies to promote the public's confidence in dermatologic surgeons.

9:58 – 10:06 am

PRESENTER: Larisa Ravitskiy, MD

TITLE: Safety and Efficacy of Oral Midazolam for Perioperative Anxiolysis of Patients Undergoing Mohs Surgery

AUTHORS: Larisa Ravitskiy, MD; Randall K. Roenigk, MD; P. Kim Phillips, MD; Amy Weaver; Jill Killian; Clark C. Otley, MD

Purpose: Preoperative and perioperative anxiety can complicate any outpatient procedure performed on an unsedated patient by causing elevation in blood pressure and heart rate with resultant increase in intra- and post-operative bleeding. Anxiety may also impair patient's ability to remain motionless during delicate surgery. Finally, anxiety reduces patient comfort and satisfaction with the surgical experience, which could result in unwillingness to obtain subsequent necessary healthcare. Midazolam is an efficacious short acting benzodiazepine with an excellent safety record. It has been widely used for anxiolysis in outpatient gastroenterology and dentistry, but little experience has been documented in outpatient dermatologic surgery.

The main objective of this study was to establish the safety and efficacy of orally administered midazolam in skin cancer patients undergoing outpatient Mohs micrographic surgery.

Design: We examined 44 patients randomized in a double-blind placebo-controlled study of a single-dose midazolam syrup (10 mg) for efficacy in producing safe anxiolysis of short duration. In addition, a second group of 31 patients wishing to receive oral midazolam in a non-blinded fashion

Jromovitch Award Abstract Session—Thursday, April 23; 9:30 – 10:30 am

were evaluated as well. Data on vital signs, anxiety, adverse events, and overall satisfaction with the anxiolytic agent were collected. Analysis of covariance model was employed to compare the outcome measures (e.g. visual analog scale (VAS) anxiety scores) between the two treatment arms, thereby allowing for the adjustment of the baseline VAS anxiety score and potential confounders (e.g., age and gender).

Summary: All groups were similar in age, sex, weight, education level, history of Mohs surgery, and number of tumor sites. There was no statistical difference in tumor type, size, location, or maximum layers to clearance. Repair types, type and amount of anesthetic were similar. All groups had no statistical differences in baseline vital signs. There was no clinically significant difference between the groups in pulse oximetry and respiratory rate over the course of the study. At 30 min post drug administration, in both midazolam groups there was a small, but statistically significant, decrease in median systolic and diastolic blood pressure (BP) that became more pronounced at 60 min. This was associated with a compensatory increase in heart rate (HR). Notably, BP in the control group increased over time, while the midazolam groups experienced reduction in BP. BP in the treatment groups reached nadir at about 60 min, then began recovery towards baseline, while HR peaked at 20 min and continued to decrease over the next 100 min.

At baseline, patients in prospective midazolam pM group were statistically significantly more anxious both self-reported and noted by staff. There was no difference in self-reported or staff noted baseline pain, alertness, or mini-mental examination scores. At 60 min, there was clinically and statistically significant reduction in anxiety in the pM group from 3.0 to 0.0 on VAS ($p < 0.001$). A less dramatic decrease in anxiety occurred in randomized midazolam rM (0.5 to 0.0, $p = 0.065$) and control (1.0 to 0.1, $p = 0.002$) groups. This was accompanied by a statistically significant decrease in alertness in the treatment groups. There was no paradoxical increase in pain in the treatment groups.

Forty three of 44 patients in the randomized arm and 28 of 31 patients in prospective completed a next-day questionnaire. Patients in the treatment groups had difficulty recalling either entire or parts of the procedure ($p = 0.004$). There was no difference between groups in postoperative nausea, vomiting, headache, cough, hiccups, involuntary muscle movement, insomnia, unusual sleepiness, increase in anxiety, nightmares, or difficulty speaking. Finally, patients in all three groups were equally satisfied with their experience. Over the course of the study there were no significant adverse events, such as hypoventilation, hypoxia, apnea, or increased pain perception.

Conclusions: Oral midazolam is an effective and safe anxiolytic for perioperative anxiety in outpatient dermatologic surgery patients. Oral midazolam is not associated with

substantial intra- and post-operative complications, including hypoventilation, hypoxia, apnea, or increased pain perception. The rapid onset and short duration of midazolam are particularly suitable for short procedures such as Mohs surgery. Midazolam caused minor changes in systolic BP and HR which did not result in clinically impactful outcomes. The primary benefit of midazolam on perioperative anxiety is in self-proclaimed apprehensive patients. The study is limited by a small number of patients enrolled.

10:06 – 10:14 am

PRESENTER: Jens Thiele, MD

TITLE: Mohs Surgery for Periocular Skin Cancers: A Retrospective Series of 553 Cases

AUTHORS: Jens Thiele, MD; Gary D. Monheit, MD; Christopher B. Harmon, MD

Purpose: There is a lack of large U.S. based case series on Mohs surgery for periocular skin cancers. Purpose of this study is to identify the location, histologic sub-types, pre-operative and defect sizes, and number of Mohs layers needed to clear periocular basal cell cancers (BCCs), squamous cell cancers (SCCs), and melanomas (MM).

Design: Data were obtained from a retrospective chart review of 553 consecutive patients (from January 2005 through September 2008) with confirmed periocular skin cancers requiring Mohs surgery and oculoplastic repair.

Summary: Our 553 patients were all Caucasians (Fitzpatrick phototypes I, II, and III) and included 346 (62.6%) males and 207 (37.4%) females. Skin cancers included a total of 435 (78.7%) BCCs, 105 (19.0%) SCCs, 10 (1.8%) MM, and 3 other tumors (0.5%; sebaceous carcinoma, trichoepithelioma, and dermatofibrosarcoma protuberans). BCCs were most frequently located on the lower eyelid (246/56.6%), followed by the medial canthus (122/28.0%), the upper eyelid (43/9.9%) and lateral canthus (24/5.5%). SCCs were also most common on the lower eyelid (64/61.0%), followed by the medial canthus (18/17.1%), the upper eyelid (16/15.2%), and the lateral canthus (7/6.7%). MMs were most common on the lower eyelid (6/60.0%). Remarkably, 8 out of 10 MM patients were females.

Pre-operative and defect sizes of BCCs were smallest in upper eyelid locations (0.47cm and 1.61cm, respectively), and largest in medial canthus BCCs (1.42cm and 2.33cm, respectively). The mean number of Mohs layers needed for BCC clearance ranged from 1.33cm (lateral canthus) to 1.42cm (medial canthus). SCC pre-operative and defect sizes were generally larger than those of BCCs and ranged from upper eyelid (smallest; 1.00cm and 1.48cm, respectively) to medial canthi (largest; 3.0cm and 3.37cm, respectively). The mean number of Mohs layers needed to clear SCCs was lowest in the lateral canthi (1.14) and highest in medial canthus locations (1.50).

Jromovitch Award Abstract Session—Thursday, April 23; 9:30 – 10:30 am

Conclusions: To the best of our knowledge, this is the largest U.S. based case series on periocular Mohs surgery focusing on BCCs, SCCs and MM. Our data confirm results from large Australian databases demonstrating that both BCCs and SCCs are most prevalent in the lower eyelid, but indicate a two-fold higher occurrence of SCCs on the upper eyelid than previously reported. Despite its larger pre-operative sizes, periocular SCCs required a lower number of Mohs layers than BCCs, with the exception of medial canthus SCCs. The latter tumors displayed the largest pre-operative and defect sizes as well as the highest number of Mohs layers needed for complete tumor removal.

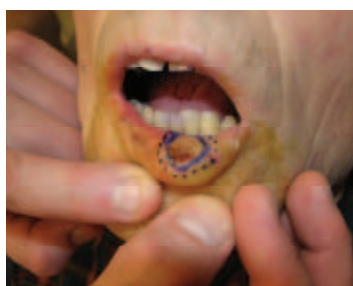Further analysis of the presented data will focus on histologic subtypes and recurrence rates.

10:14 – 10:22 am

PRESENTER: Melissa Pugliano-Mauro, MD

TITLE: Mohs Surgery is Effective for High-Risk Squamous Cell Carcinoma

AUTHORS: Melissa Pugliano-Mauro, MD; Glenn D. Goldman, MD



This squamous cell carcinoma metastasized to submental LN.

Purpose: The effectiveness of MMS has been clearly demonstrated for invasive SCC. As a subgroup, high-risk SCC present a challenge to the dermatologic surgeon and historically have a more guarded prognosis. We report the detailed outcome of ten years of MMS for high-risk SCC in a single practice by a single surgeon using a standardized approach.

Design: Patients with high risk SCC were defined by standard criteria: invasive tumors of lip and ear, tumors over 2cm in diameter, immunocompromise, perineural involvement, rapid growth. All tumors invaded into or deeper than subcutis. 280 cases were treated by MMS by one surgeon. Reconstructions were performed at the time of MMS or shortly thereafter. In cases with large (named) nerve perineural involvement, postoperative radiation therapy was recommended. Long-term follow-up was obtained by the treating MD in the majority of cases and by the referring dermatologist in the remainder. All patients were followed at 4 to 6 month intervals for at least 2 years, and the average follow-up is now greater than 5 years. Photos were obtained of all lesions for presentation.

Summary: We have been successful in obtaining detailed follow-up for greater than 90% of patients, and will obtain follow-up on every patient if feasible.

Mohs surgery was extremely effective at removing high risk SCC and preventing local recurrence. Of 280 tumors removed, 2 have recurred locally for a recurrence rate of 0.7%.

Extensive large nerve perineural (PN) disease was identified in 8 cases, all of whom received adjuvant RT. None of these patients has had local recurrence, and all but one (who died of cardiac disease) have had sequential follow-up for greater than two years with the treating physician and are alive, asymptomatic and well.

Small nerve PN disease was common and treated with surgery alone, and there have been no recurrences and no metastases in these patients.

There have been 6 metastases, all of which occurred within the first year, and one of which was synchronous with tumor removal. All metastases were from well-differentiated tumors. Three of these patients are alive and well more than two years after lymphadenectomy, partial parotidectomy, and adjuvant radiation therapy. One died (without recurrence) from unrelated causes.

Two deaths occurred from metastatic disease. One was from a penile carcinoma with synchronous metastasis and one was in a transplant patient with two explosive SCC on the finger who suffered brachial plexus and pulmonary metastases within months.

Data is currently under analysis for age of onset, sex, comorbid conditions, lesions size, number of stages required per tumor, and reconstruction.

Analysis revealed several ancillary findings:

Patients with one high risk SCC were highly-likely to develop secondary SCC. Up to 70% of patients presenting with one high-risk SCC developed another invasive SCC within the 5 years following presentation.

Patients with high risk SCC have an exceptionally high incidence of death from other causes within the 5 years following surgery, with a very high death rate from other forms of metastatic cancer. Analysis is ongoing.

Patients with high risk SCC have a substantial risk of developing malignant melanoma with subsequent metastasis. Three of our patients died from metastatic, nodular malignant melanoma, and one is alive with widespread metastases. Numerous other patients (data in progress) have been diagnosed with superficially-invasive MM.

Conclusions: MMS is a very effective treatment for high-risk cutaneous SCC. Large nerve perineural involvement treated by MMS followed by adjuvant radiation therapy has a success rate far above historic norms. Metastasis is more common than local recurrence, and generally occurs within one year. Cure of metastatic disease is feasible in many cases, especially with early regional node metastasis. Patients with high-risk SCC have many comorbidities, frequently have other cancers, have an exceptionally high incidence of second squamous carcinoma and malignant melanoma, and have a shorter than expected life expectancy from all causes. Only rarely, however, do they die of metastatic cutaneous squamous carcinoma.

Tromovitch Award Abstract Session—Thursday, April 23; 9:30 – 10:30 am

10:22 – 10:30 am

PRESENTER: Humza Ilyas, MD

TITLE: Sebaceous Carcinoma of the Eyelids Treated with Mohs Micrographic Surgery

AUTHORS: Humza Ilyas, MD; Nancy Kim, MD, PhD; Regina M. Yavel, MD; Mark J. Lucarelli, MD; John G. Rose, MD; Stephen N. Snow, MD

Purpose: Sebaceous cell carcinoma (SbCC) is a rare tumor of the eyelids. Management is usually by complete excision but is complicated by the fact that the tumor can be multicentric or demonstrate pagetoid spread¹. Despite its potential for discontinuous spread, however, there have been reports²⁻⁴ detailing Mohs surgery for SbCC. We present a case series of 16 SbCC patients treated with MMS over the last 21 years.

Design: A retrospective case review of all patients with sebaceous cell carcinoma of the ocular adnexa seen by a university Mohs surgery clinic between 1987 and 2008. The postoperative follow-up period ranged from 7 months to 14 years with a mean duration of 4.5 years. The main presenting parameters of interest included the presence of pagetoid spread, number of Mohs layers taken, final defect size, and time from symptom onset to diagnosis. Outcome measures of particular interest included local recurrence, metastatic disease, and mortality from sebaceous cell carcinoma.

Summary: In the current series, there were 16 cases of ocular adnexal sebaceous cell carcinoma. 9 (56%) cases originated on the upper lid and 7 (44%) on the lower lid. One patient was found to have orbital extension at the time of initial treatment

and was exenterated. The remaining cohort underwent Mohs surgery and achieved clear margins. Of these, one patient was lost to follow up immediately after surgery. One of the remaining 14 patients, (7%) developed local recurrence 1.5 years after Mohs surgery and underwent exenteration with no evidence of further disease 12 years later. Twelve patients (93%) had no evidence of local recurrence with a follow-up of 7 months to 14 years. A single patient had parotid metastases diagnosed and was treated with parotidectomy and neck dissection prior to the evaluation of the primary tumor and subsequent radiotherapy. Of 14 patients treated with Mohs and with documented follow-up, 6 (43%) showed histologic evidence of pagetoid spread. The number of Mohs stages taken ranged from 1 to 6 with a median of 4. Mean defect size measured 3.7 cm². No deaths attributable to sebaceous cell carcinoma occurred.

Conclusions: Sixteen cases of sebaceous cell carcinoma treated with Mohs micrographic surgery are presented. Patient demographics and tumor distribution were compatible with prior series of ocular adnexal sebaceous cell carcinoma. Pagetoid spread was discovered in 42% of the cases which was consistent with other reports. Our outcomes are comparable with published series with conventional wide excision with frozen or paraffin margin controls. These findings indicate that Mohs surgery appears to be an effective form of surgical treatment for primary sebaceous cell carcinoma when orbital extension is not present and management is coordinated with a Mohs surgeon experienced with sebaceous carcinoma.

Research Abstract Session—Thursday, April 23; 3:30 – 4:30 pm

3:33 – 3:41 pm

PRESENTER: Basil S. Cherpelis, MD

TITLE: Innovative 19 Minute Rapid Cytokeratin Immunostaining of Non-melanoma Skin Cancer in Mohs Micrographic Surgery

AUTHORS: Basil S. Cherpelis, MD; Logan Turner, MD; Sharron Ladd, BS; L. Frank Glass, MD; Neil Fenske, MD

Purpose: Our objective was to develop an effective ultra-rapid cytokeratin (CK) frozen section immunostain to be used during Mohs micrographic surgery (MMS) in cases of non-melanoma skin cancer (NMSC) with dense or perineural inflammation.

Dense inflammation can obscure non-melanoma skin cancer on frozen sections which can lead to missed tumor and recurrence. Dense inflammation often prompts removal of additional layers to ensure negative margins. CK immunostaining in MMS has been examined in the past and found useful, but is limited by lengthy 1 hour processing.

Design: Twenty-one patients underwent MMS for biopsy-proven NMSC (11 cases of BCC and 10 of SCC). The frozen sections were stained with H&E and our 19 minute cytokeratin (AE1/AE3 monoclonal antibody) protocol. Additional sections from each case were also submitted for permanent (formalin fixed, paraffin embedded) H&E and CK immunostain processing by standard methods, for comparison. A thickness of 4 microns was used for all sections. For cases of BCC, permanent sections were also stained with Ber-EP4 and compared with cytokeratin stained sections.

Each tumor was debulked prior to the initial Mohs layer, and this material served as a positive control for the AE1/AE3 cytokeratin antibody. The epidermis and adnexal structures overlying and adjacent to the tumor provided additional internal controls for AE1/AE3. All frozen sections staining deemed positive or negative for tumor with the rapid immunostain protocol were confirmed by immunostaining of permanent sections.

Research Abstract Session—Thursday, April 23; 3:30 – 4:30 pm

Summary: The ultra-rapid CK protocol stained all of the cells in each of the 21 examples of BCC and SCC in frozen tissue in an equivalent way as immunostains applied to permanent sections. In each of the twenty-one cases of NMSC, islands of tumor and single cells were clearly labeled by CK immunostaining in both frozen and permanent sections. This rapid stain was useful in identifying perineural invasion and in confirming the presence or absence of cancer cells in areas of dense inflammation.

Conclusions: This innovative 19 minute ultra-rapid CK immunostain can be used to detect trace quantities of NMSC in frozen sections during MMS. This protocol is able to significantly reduce the time required for CK immunostaining compared to previous methods, thus making it more appealing and practical for MMS.

3:41 – 3:49 pm

PRESENTER: Glen M. Bowen, MD

TITLE: Topical Imiquimod Versus Imiquimod and Tazarotene for Lentigo Maligna Followed by Staged Excision

AUTHORS: Glen M. Bowen, MD; Mark A. Hyde, MMS, PA-C

Purpose: In a pilot study we found that in patients with lentigo maligna (LM) treated with imiquimod 5% cream for three months, about 70% of lesions had no sign of residual tumor when a staged excision was performed using two millimeter margins. In an effort to improve response rates a study was designed to add tazarotene 0.05% gel to topical imiquimod to see if disruption of the stratum corneum would improve drug penetration and consequently improve the response rates to imiquimod. Results would be evaluated by performing staged excisions of the entire lesions and analyze the tissue for complete responses.

Design: A randomized prospective study was designed and approved by the internal review board at the University School of Medicine. Ninety patients with histologically defined lentigo maligna were randomized to one of two groups: group one was treated with imiquimod 5% cream five days a week for three months followed by two months of recuperation and then a staged excision was performed to document whether or not a complete response was achieved with the topical agent. A second group received imiquimod on the same schedule but also received tazarotene 0.05% gel two days a week. Degrees of inflammation were recorded in each group. A drug holiday of one week was taken if erosion or seeping was noted on examination.

Summary: Of the ninety patients enrolled in the study, seventy-seven reached the intent to treat: forty-one in the imiquimod only group and 36 in the imiquimod combined with tazarotene group. One person dropped out of the first group due to side effects whereas four dropped out due to side effects in the

combined group. After completing three months of topical treatment, sixty-three percent of patients (26/41) had no residual tumor in the imiquimod-only group whereas eighty-one percent (29/36) had no residual tumor in the combination group. Although a trend tended to favor the combined treatment group, the difference between the two groups did not reach statistical significance ($p = 0.08$).

Conclusions: Topical imiquimod 5% cream applied five times a week for three months can lead to complete tumor resolution in the majority of cases and the addition of topical tazarotene gel 0.05% did not overcome the failure to completely respond in nineteen percent of patients. However, pre-treatment of LM with topical imiquimod with or without tazarotene can greatly reduce the morbidity of the surgery required to verify negative histologic margins. Roughly eight out of ten patients treated with combined therapy had negative margins beginning with two millimeters of excision as opposed to only forty-eight percent of untreated patients having negative margins beginning with a five millimeter surgical margin in a previous study at our institution. It is our opinion that topical imiquimod can be very useful in decreasing surgical defect sizes as an adjuvant to staged surgical excisions for LM. Five-year follow-up is underway to compare recurrence rates in imiquimod-treated patients followed by conservative two millimeter surgical margins.

3:49 – 3:57 pm

PRESENTER: Robert H. Cook-Norris, MD

TITLE: Complications of Cutaneous Surgery in Patients Who Are Taking Clopidogrel

AUTHORS: Robert H. Cook-Norris, MD; Jason D. Michaels, MD; P. Kim Phillips, MD; M. Amanda Jacobs, MD; Randall K. Roenigk, MD; Clark C. Otley, MD

Purpose: Perioperative management of anticoagulant therapy during surgery remains controversial; however, there is increasing evidence suggesting the risk of severe hemorrhagic complications is not significantly increased in those continuing anticoagulant therapy. Therefore, continuation is recommended given the potential for life-threatening thromboembolic complications associated with perioperative discontinuation of medically necessary aspirin or warfarin. Clopidogrel is an increasingly prescribed anticoagulant for primary and secondary prevention of cardiovascular disease. The frequency of postoperative bleeding and other complications in patients taking clopidogrel at the time of cutaneous surgery has not been established.

Our objective was to determine the frequency and severity of perioperative complications in patients taking clopidogrel and to evaluate if withholding one or more anticoagulant leads to postoperative thromboembolic complications.

Research Abstract Session—Thursday, April 23; 3:30 – 4:30 pm

Design: A search of the master diagnosis index at our institution was queried from 2004 to 2008 to identify patients who underwent Mohs micrographic surgery while taking clopidogrel. A retrospective chart review was conducted to extract the following data: patient demographics, anticoagulant and platelet-inhibiting medications taken or withheld perioperatively as well as indication, indication for surgery, tumor size, type of closure, final size, and post-operative course. Telephone interviews were conducted to ensure accurate follow-up information. Cases were compared to age and gender matched (1:1) controls of two groups, those not on anticoagulants and those taking aspirin.

Summary: (Preliminary Analysis): A total of 245 patients, undergoing 417 procedures on 297 different occasions, met criteria for inclusion. Indications for surgery included basal cell carcinoma (241, 57.8%), squamous cell carcinoma (162, 38.9%), lentigo maligna (9, 2.2%), atypical fibroxanthoma (2, 0.5%), extramammary Paget's disease (2, 0.5%), and trichoepithelioma (1, 0.2%). Initial tumor size ranged from 0.3 to 13.0 cm with a median of 1.2 cm. There were 271 (65%) primary closures, 77 (18.5%) secondary closures, 50 (12%) flaps, and 19 (4.5%) grafts. Final closure size ranged from 0.4 to 21.5 cm with a median of 3.5 cm.

Severe complications were encountered in 8 of 297 operative events. Patients taking clopidogrel were 4.5 times more likely to develop a severe complication following their Mohs procedure than patients taking aspirin only (95% CI, 0.9-21.3, $p=0.060$) and 4.4 times more likely than patients not on anticoagulants (95% CI, 0.9-20.7, $p=0.064$). There were 19 moderate complications and 19 mild complications in patients taking clopidogrel. Patients taking aspirin encountered 2 severe, 3 moderate, and 8 mild complications among 287 operative events. Those not taking anticoagulants experienced 3 severe, 1 moderate, and 10 mild complications among 287 operative events.

At the time of the 297 procedures, 208 (70.0%) were also taking aspirin, 12 (4.0%) were taking warfarin, and 10 (3.4%) were on both aspirin and warfarin. Indications for anticoagulation included cardiovascular stent (126, 42.4%), severe coronary artery disease (97, 32.7%), stroke (59, 19.9%), transient ischemic attacks (40, 13.5%), post myocardial infarction (19, 6.4%), unstable angina (14, 4.7%), atrial fibrillation (13, 4.4%), and history of non-ST-elevation myocardial infarction (12, 4.0%). 59 patients (61 procedures) had one or more anticoagulant withheld prior to surgery, of which, one life-threatening postoperative thromboembolic complication was encountered in a patient who held aspirin therapy 2 days prior to surgery.

Telephone interviews have yet to be finalized; therefore, the aforementioned complication rates in patients taking clopidogrel may be underestimated.

Conclusions: Mohs micrographic surgery in patients receiving clopidogrel is associated with a strong trend of increased risk of severe complications. Given the risk associated with discontinuation of clopidogrel perioperatively, especially in those taking medically necessary dual antiplatelet therapy (i.e. recent coronary artery stent placement) with thrombosis occurring in 29% of patients discontinuing therapy prematurely (7.5% increased mortality rate), continuation is recommended in most situations. Similarly to the perioperative management of aspirin and warfarin, the patient's medical history and risk factors must be considered.

3:57 – 4:05 pm

PRESENTER: Murad Alam, MD

TITLE: Treatment of Rare and Uncommon Non-melanoma Tumors by Mohs Surgery: A Meta-Analysis of 1232 Cases

AUTHORS: Murad Alam, MD; Christopher Wickman, M4; Daniel Danahey, MD; Simon S. Yoo, MD; Natalie Kim, BS Clinical; Alfred Rademaker, PhD

Purpose: Mohs surgery is routinely used for treatment of common non-melanoma tumors, basal cell carcinoma and squamous cell carcinoma. Less often, Mohs is used for the treatment of other non-melanoma skin cancers for which tissue sparing and microscopic margin control may be beneficial. The purpose of this study was to characterize the utility of Mohs in the treatment of uncommon and rare non-melanoma skin cancers of various types.

Design: Meta-analysis of case reports and case series from MEDline, 1950-2007, and older articles obtained from bibliographic searches. Uniform fields, including demographic information (patient age, sex), tumor characteristics (anatomic location, apparent clinical surface area), and treatment-specific variables (treatment type, post-operative defect size, duration of post-treatment follow-up, recurrence, death from disease) were extracted from published reports. Means and variation of descriptive variables were recorded. Association of demographic and tumor characteristics with likelihood of recurrence was assessed.

Summary: Data was extracted for 1232 tumors including (in parentheses after each tumor type: median preoperative size in sq. cm.; ratio of post-operative size to preoperative size, median; % recurring during follow-up period): atypical fibroxanthoma (1.8, 2.8, 13.3); angiosarcoma (5.8, 3.6, 12.5); dermatofibrosarcoma protuberans (7.1, 9.7, 1.5); extramammary Paget's disease (36.7, 2.1, 20.3); eccrine porocarcinoma (1.1, 2.4, 0.0); granular cell tumor (1.2, 1.4, 0.0); lymphoepithelioma-like carcinoma of the skin (2.1, 9.4, 0.0); leiomyosarcoma (7.6, 5.6, 14.3); microcystic adnexal carcinoma (1.7, 6.0, 7.0); Merkel cell carcinoma (1.5, 3.4, 35.4); malignant fibrous histiocytoma (7.1, 11.4, 21.4); primary mucinous carcinoma (0.5, 3.2, 21.1); sebaceous

Research Abstract Session—Thursday, April 23; 3:30 – 4:30 pm

carcinoma (0.6, 4.7, 11.1); trichilemmal carcinoma (1.0, 4.0, 16.7). Overall, mean follow-up in months was 39, by which point 3.6% were alive with disease and 1.4% were dead with disease. However, for Merkel cell carcinoma, after just 27 months of follow-up, 11.3% were alive with disease and 14.4% were dead of disease.

Conclusions: On average, for the tumors studied, preoperative tumor size was 3.6 sq. cm; postoperative tumor size as measured by the final Mohs defect was 4.4 times larger in area. Mean recurrence rate was 9.4% during 3.5 years of follow-up. There was significant variation across tumor types, with some having markedly worse prognosis. For unusual non-melanoma skin cancers, this study provides tumor type specific benchmark data for: (1) the likely size of the post-operative defect as a function of the apparent clinical tumor size before treatment; and (2) the likelihood of medium-term recurrence and mortality after Mohs. This information can be useful in planning surgeries and counseling patients. A high ratio of post-operative to pre-operative tumor size and a low rate of recurrence after removal both suggest the utility of the tissue sparing and microscopic margin control elements inherent in Mohs surgery. Mohs surgery appears to be a useful modality for treatment of uncommon and rare non-melanoma tumors.

4:05 – 4:13 pm

PRESENTER: Jerry D. Brewer, MD

TITLE: Malignant Melanoma in Solid Transplant Recipients, Collection of Database Cases with Comparison to SEER Data for Outcome Analysis

AUTHORS: Jerry D. Brewer, MD; Leslie J. Christenson, MD; Amy L. Weaver; Roger Weenig; Katherine K. Lim, MD; James H. Keeling, MD; Clark C. Otley, MD

Purpose: Malignant melanoma (MM) is considered an immune responsive tumor. There has been concern that MM may have worse outcomes in immunosuppressed hosts compared to the general population. Currently, little is known regarding the outcomes and prognostic factors of MM in immunosuppressed organ transplant recipients (OTRs).

The primary objective of this study was to determine the MM-specific and overall survival in patients diagnosed with MM after receiving an organ transplant and compare with a national sample of patients with MM.

Design: A retrospective review was conducted of OTRs with MM identified from the surgical and medical index databases at the Clinic from 1978 to 2007, the Organ and Procurement and Transplantation Network/United Network for Organ Sharing database (UNOS) from 1999 to 2006, and from the Israel Penn International Transplant Tumor Registry from 1953 to 2005. Demographic and prognostic information

was abstracted on as many cases as possible. Prognostic analyses were conducted by Breslow depth and Clark's level. The subcategory of patients with MM developing as a result of transmission from the organ donor was not evaluated in this study. Among the OTR patients, MM-specific and overall survival following MM diagnosis were calculated using the Kaplan-Meier method. For comparison, overall and MM-specific survival estimates were obtained using the actuarial method for 91,063 cases reported to the NCI SEER program with a diagnosis of MM of the skin between 1988 and 2003.

Summary: Patients were excluded if a confirmed pathology report of MM could not be found, or if there was no documentation regarding transplant history, yielding 703 cases of MM in 633 patients diagnosed after transplant. Among OTRs with MM after transplant, Breslow depth and Clark's level were available in 125 and 152 patients, respectively.

The 5 year overall survival of OTRs who subsequently developed MM with Breslow depths of <0.75, 0.76-1.50, 1.51-3.0, and >3.0mm was 88.1%, 87.1%, 51.1%, and 62.8% respectively. The 5 year MM-specific survival for these patients with the same Breslow depths was 97.3%, 94.7%, 64.1%, and 68.5%, respectively. These 5 year MM-specific survivals were not significantly different ($p>0.05$) from the estimates for MM cases in the SEER database for these same Breslow categories (96.8%, 92.6%, 80.6%, and 61.8% respectively).

The 5 year MM-specific survival for Clark's level I, II, III, IV, and V in OTRs with subsequent MM was 100%, 96.6%, 75.5%, 68.5%, and 88.9%, respectively. The 5 year MM-specific survival for the same Clark's level for SEER patients with MM was 98.6%, 95.1%, 85.2%, 92.4%, and 63.0%, respectively. These 5 year MM-specific survivals for Clark's level were also not significantly different ($p>0.05$) for OTRs with subsequent MM compared to SEER MM cases.

Conclusions: This is the largest report of cases to date in regards to prognostic data in patients with MM who are also OTRs. This retrospective study does not demonstrate an increased tendency towards mortality due to MM in OTRs compared to non-immunosuppressed patients with MM, stratified by Breslow depth and Clark's level. The limitations of this study include the small number of cases analyzed after exclusion criteria were enforced. There may also be bias due to the voluntary nature of reporting from individual institutions. Further work in this area is needed and prospective and collaborative data collection would be beneficial.

Research Abstract Session—Thursday, April 23; 3:30 – 4:30 pm

4:13 – 4:21 pm

PRESENTER: Robert J. MacNeal, MD

TITLE: Mohs Micrographic Surgery for the Treatment of Lentigo Maligna, the University Experience

AUTHORS: Robert J. MacNeal, MD; Christopher J. Arpey, MD; Carrie E. Cera-Hill; Marta J. Van Beek, MD

Purpose: The purpose of this study was to review the clinical characteristics, rate of recurrence and outcomes in lentigo maligna treated with Mohs micrographic surgery (MMS) without the use of adjunctive techniques (e.g. rush permanent sections and immunostaining) at the University Hospitals and Clinics. Additionally, since invasive disease carries a significantly different prognosis than LM, we sought to examine the rate of invasion found in debulking specimens in the patients we examined. This finding has not been widely published in the literature.

Design: We performed a retrospective chart review of 70 consecutive patients from a tertiary care center with a history of lentigo maligna treated with Mohs micrographic surgery from 1998-2008, of these 50 had adequate follow-up and satisfied the criteria of LM, without invasion on initial biopsy, treated with MMS. Variables analyzed include anatomic location, size, age, sex, previous treatment, number of Mohs stages, invasion found in debulking layer, surgical defect size and recurrence rate.

Summary: Lentigo maligna (LM), or melanoma in situ arising in sun-damaged skin, typically presents as a slowly enlarging hyperpigmented patch on the head, neck, or upper extremities of elderly patients. Although melanoma in situ carries a 100% survival rate at 5 years, an estimated 5% of lentigo maligna progresses to invasive melanoma, or lentigo maligna melanoma. Surgical excision with 0.5cm margins remains standard of care for these neoplasms. Treatment of Melanoma in situ, including lentigo maligna type, with Mohs micrographic surgery (MMS) is becoming increasingly common since initially proposed by Dr. Frederic Mohs in 1950 and popularized by Dr. John Zitelli in the 1990's. While recent data shows increased clearance and cure rates when compared to standard excision, its use remains controversial.

Reported recurrence rates of LM treated with MMS have ranged from 0.5-30% in the literature. Immunostaining and rush paraffin sectioning techniques have been developed in hopes of improving clearance rates, however their use results in increased cost and procedure time. Additionally there are no studies, to our knowledge, showing improved outcomes when immunostaining is used. In this study a chart review was performed of all patients treated with Mohs surgery for lentigo maligna (LM) at the University over the past 10 years. 70 charts were identified and 50 cases were verified and ultimately analyzed. The average age was 66.5 years and 57% of patients were women. Average follow up was 24.4 months (range of 3 weeks to 103 months) and there were no recurrences. 3 (6%) patients were found to have invasive (LMM) in the debulking layer with an average Breslow depth of 0.4mm. This rate of invasive disease is similar to what was found (5%) in the only other study in the literature that we found to report this statistic. All tumors were located on the face except 2 which were located on the scalp vertex. 10% of tumors were recurrent at the time of initial MMS. It took 1.4 stages of MMS on average to achieve clearance. The average lesion size was 2.6cm and defect size 3.3cm.

Conclusions: From this data we can gather several important points. First, our data is consistent with the majority of previous reports describing extremely high cure rates using MMS for LM. Also supported is the notion that, in experienced hands, H&E frozen section alone without aid of immunostaining or rush sectioning, is sufficient to achieve this high cure rate. Noteworthy is the finding that 6% of debulking specimens had an invasive component in a tumor originally believed to be LM. We therefore encourage the practice of sending debulking layers for permanent section to examine for invasive disease. This practice has the potential to change both the management and prognosis of the patient. Finally, the difference between the mean lesion and defect size of 1.3cm supports the often espoused notion that the guidelines of 0.5cm margins for LM are too conservative and will likely often result residual tumor being left behind.

Clinical Pearls Abstract Session—Friday, April 24; 3:00 – 4:00 pm

3:03 – 3:11 pm

PRESENTER: Thomas G. Lewis, MD

TITLE: Nasal Valve Repair Using Double Lateral Suture Suspension

AUTHORS: Thomas G. Lewis, MD; Heidi B. Donnelly, MD

Purpose: The nasal valve area is a common site of nasal airway obstruction. Mohs micrographic surgery and reconstruction of the lateral nose may lead to nasal valve impairment. Diagnosis of nasal valve obstruction is made with the classic Cottle test, in which the medial cheek is retracted superiolaterally, opening the nasal valve. If the patient's breathing improves, the test is positive. Numerous techniques have been described to correct nasal valve obstruction, including use of spreader grafts, flaring sutures, butterfly grafts, batten grafts, lateral crus pull-up, alar expansion and reinforcement, and intranasal Z-plasty. Most of these described techniques require an external rhinoplasty approach. Nasal valve lateralization by suspension, in contrast, mimics the Cottle maneuver to improve nasal obstruction without requiring an extensive invasive surgical approach.

Design: A detailed description of a double suture suspension to correct nasal valve obstruction will be provided. Two successful case reports of nasal valve suspension will be used to illustrate the technique. The first is a 66 year-old man who reported decreased airflow on the right following Mohs surgery and nasal reconstruction with a cartilage strut and medially based bilobe flap for a deep right alar groove defect. The second is a 77 year-old woman who complained of persistent unilateral nasal blockage after Mohs surgery and repair with a laterally based spade lobe flap for a lateral nasal tip defect.

Summary: Both patients reported subjective improvement of obstructive symptoms following nasal valve suspension. A common side effect of nasal valve suspension is widening of the middle third of the nose and flattening of the nasofacial sulcus that occurs as the nasal valve is pulled superior laterally. This was an acceptable side effect for each patient, however, the first patient elected to have the suspension performed bilaterally to achieve better facial symmetry. The second patient experienced postoperative erythema and tenderness over the site of the suspension sutures that subsided with oral antibiotics.

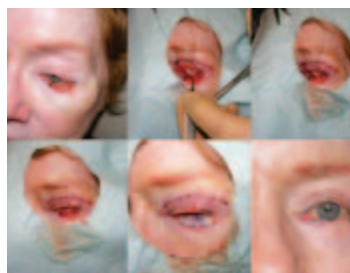Conclusions: While several treatment options for nasal valve obstruction may be effective, nasal valve suspension has the advantage over many other techniques. In general, it is less time consuming, easier to perform, has faster healing times, and does not require a separate donor site for cartilaginous grafts. The use of two suspension sutures on either side better lateralizes the nasal valve and decreases the chance of failure compared to one suture. These two case reports, along with a handful of similar case series in the literature, show that nasal valve suspension can be a reliable, low risk, alternative for the treatment of nasal valve obstruction.

3:11 – 3:19 pm

PRESENTER: Kevin J. Mott, MD

TITLE: The Hughes Tarsconjunctival Flap: A Useful Flap for Repair of Full-Thickness Lower Eyelid Defects Following Mohs Surgery

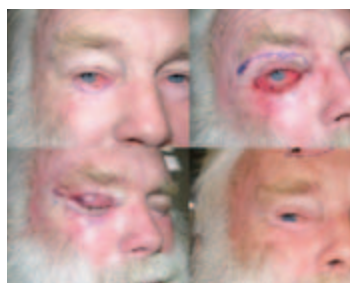AUTHOR: Kevin J. Mott, MD



Purpose: The author believes that this flap is underutilized for full thickness eyelid repair, but well within the skill set of most Mohs surgeons.

Design: The indications, design, and execution of the flap will be presented in a step-by-step format utilizing clinical digital photos of two cases in a power point presentation.

Conclusions: The Hughes tarsconjunctival flap is a useful flap for reconstruction of full-thickness lower eyelid Mohs surgery defects involving 50-75% of the lid margin.



3:19 – 3:27 pm

PRESENTER: Brian C. Leach, MD

TITLE: Revisionary Technique for Alar Rim Notching: The Stair-Step Flap

AUTHORS: Brian C. Leach, MD; Joel Cook, MD

Purpose: The undesirable outcome of alar rim elevation or notching may occur following improperly designed nasal reconstructions or subsequent to overt flap or graft failure at the alar rim. Revision is often difficult and frequently requires multiple procedures or graft donor sites to accomplish, with a highly variable aesthetic outcome. The stair-step flap affords a single stage operative revision for the correction of excessive alar elevation without the need for cartilage grafting.

Design: A case report and review are given, and a thorough explanation of the flap's design and execution is presented.

Summary: The stair-step flap can produce reliable aesthetic and functional revision of the alar rim in a single operative procedure without the need for cartilage batten grafting.

Conclusions: Alar notching, one of the most troublesome aesthetic and functional complications of facial reconstruction, may be corrected with a single operative procedure, the stair-step flap. The stair-step flap is a useful revisionary tool in the armamentarium of any dermatologic or facial reconstructive surgeon.

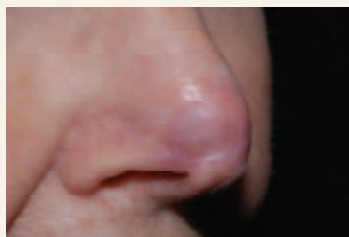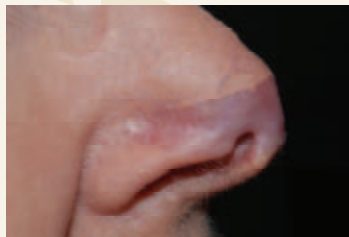
Clinical Pearls Abstract Session—Friday, April 24; 3:00 – 4:00 pm

3:27 – 3:35 pm

PRESENTER: Michael W. Chen, MD

TITLE: Reconstruction Pearl: A Proximally-based Alar Hinge Flap for a Nasal Soft Triangle Defect

AUTHORS: Michael W. Chen, MD; Richard G. Bennett, MD



Purpose: For thru-and-thru soft triangle defects, turnover hinge flaps have been described previously, either based superiorly and flipped inferiorly or based distally in the columella and flipped proximally. Oftentimes, secondary to previous surgery and scar formation, healthy tissue is not available superiorly in the nose tip or distally in the columella. This case report presents a simple and reliable, one-stage procedure for reconstructing defects of the nasal soft triangle with a proximally-based hinge flap.

Design: Two cases of thru-and-thru soft triangle defects following Mohs micrographic surgery and the step-by-step reconstruction are described. In each case, a rectangular flap proximal to the defect is elevated and flipped into the defect to reline the nasal mucosa. The recipient wound comprised of the donor site of the hinge flap and the underside of the hinge flap is then reconstructed with a postauricular skin graft. Follow-up photographs from one patient taken 1 month after the initial defect show the healed repair.

Summary: The proximal alar hinge flap is a simple and reliable technique for recreating the nasal soft triangle in one stage.

Conclusions: The proximal alar hinge flap is a simple and reliable technique for recreating the nasal soft triangle in one stage.

3:35 – 3:43 pm

PRESENTER: Juan-Carlos Martinez, MD

TITLE: Standardized Photography in Facial Reconstructive Surgery: Clinical Pearls to Simplify a Complicated Task

AUTHOR: Juan-Carlos Martinez, MD

Purpose: Accurate and reproducible photographic images are critical for the documentation, comparison, and academic presentation of pre- and post-surgical appearance. The issue of standardized photography has not been discussed in the

dermatologic surgical literature for over 20 years. With the advent of digital photography, the ease and rapidity with which numerous images can be obtained, reviewed, and displayed has vastly increased. As can be observed in many dermatologic publications regarding facial reconstruction, ideal images are seldom obtained. This makes fair and accurate assessment of the techniques or concepts described in the corresponding manuscript difficult, if not impossible. Inconsistencies in the patient's position, inappropriate lighting, or a distracting background commonly lead to sub-par photographs.

Design: Tips for proper patient positioning using anatomic landmarks can aid in the reproducible acquisition of comparable serial images. These pearls are described and demonstrated for head-on, oblique, profile, and swimmer's views. Common pitfalls will be reviewed and demonstrated to highlight their sometimes subtle, though often distracting, effects on the image. In addition, the use of standard camera settings and proper subject framing will be reviewed.

Summary: Accurate, reproducible, and anatomically consistent pre- and post-operative photographs are critical for documentation, comparison, and academic presentations. Digital photography has made the rapid acquisition, download, and review of numerous high resolution photographs easier and less expensive than ever before. Tips for acquiring reproducible images with relatively inexpensive equipment are presented in the hopes that surgeons will strive to obtain more ideal images.

Conclusions: Although clinical photographs of the highest quality may require expensive and elaborate photographic suites and equipment, with some consideration and attention to minor details, modern handheld digital cameras can be used, with impressive simplicity, to provide reliably comparable images.

3:43 – 3:51 pm

PRESENTER: Ravi S. Krishnan, MD

TITLE: Using Rotation Flaps to Repair Large Scalp Defects without the Aid of Tissue Expanders

AUTHOR: Ravi S. Krishnan, MD

Purpose: Large defects of the scalp are commonly encountered by Mohs surgeons after the extirpation of cutaneous malignancies. The repair of such defects can often present the surgeon with a significant challenge. The use of large scalp flaps for the repair of such defects has been described by several authors. Unfortunately, there is a common misperception that these types of reconstructions are too large or complicated for use in a typical Mohs surgery practice. In our view, this is inaccurate. We shall describe our technique for reconstructing large defects of the scalp with multiple rotation flaps, which is

Clinical Pearls Abstract Session—Friday, April 24; 3:00 – 4:00 pm

technically uncomplicated and yields excellent results.

Design: We shall describe the use of this technique in 10 patients with large scalp defects (up to 30 square centimeters). The critical steps of the technique involve the design of very large flaps, anesthesia with a tumescent anesthetic solution, undermining of the entire scalp, and approximation of the flaps with minimal to no “dog-ear” repair.

Summary: In all patients, this technique was performed without difficulty or post-operative complications. All patients tolerated the procedure well and had excellent cosmetic results. Most patients complained of transient numbness and tightness which resolved in approximately six months.

Conclusions: In summary, local rotation flaps are an excellent choice for repairing large scalp defects without the aid of tissue expanders. The reconstructive technique we have described can be readily performed in the office under local anesthesia and offers several advantages over the traditional reconstructive methods: it allows preservation of hair-bearing skin, it provides an excellent color and texture match, it is much less likely to result in a depressed scar, and it reduces the healing time and the patient’s wound care responsibilities. Given the ease with which this technique can be executed and the excellent results it can achieve, we are certain that it will be an excellent addition to the Mohs surgeon’s armamentarium.

Research Abstract Session—Saturday, April 25; 12:00 – 1:00 pm

12:03 – 12:11 pm

PRESENTER: Quenby L. Erickson, DO

TITLE: Can Flash Freezing of Mohs Layers Expedite Slide Turn Around Time and Minimize Sample Distortion (Freezing Artifact)?

AUTHORS: Quenby L. Erickson, DO; Trishina Clark; Kassandra Larson; Tri H. Nguyen, MD; T. Minsue Chen, MD

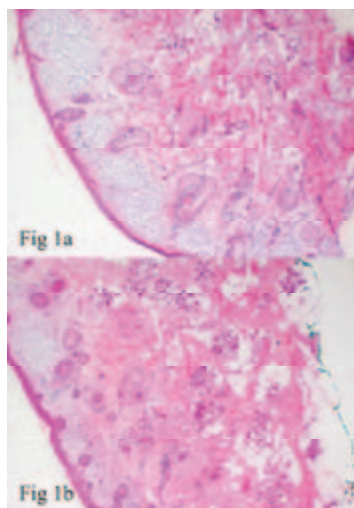


Figure 1. Frozen section histology illustrating sample distortion.

Fig 1a. Cryostat frozen section exhibiting freeze artifact, shrinkage and separation of dermis; note the lost structure of eccrine glands and fat. **Fig 1b.** Histobath frozen section exhibiting normal appearance of epidermis, dermis, fat and eccrine glands.

Purpose: To compare flash freezing to the traditional method of freezing tissue in the cryostat in Mohs micrographic surgery (MMS). In MMS, the tissue is traditionally frozen in the cryostat. This step in tissue processing is time sensitive; a delay in embedding may cause drying artifact and tissue autolysis. It is oftentimes the rate-limiting step to slide turn around time (TAT). Additionally, tissue samples that are slowly frozen in a cryostat have an increased chance of microscopic ice crystal formation, expansion, and sample distortion (freezing artifact). Flash freezing is utilized in frozen section processing of general pathology specimens to expedite slide TAT, as well as, enhance frozen section slide quality by minimizing ice crystal formation.



Fig 2. Histobath. After placing the specimen on the glass slide and covering it in embedding media, the specimen is lowered into the histobath with tongs where it rapidly freezes.

Design: Mohs layers that were divided into at least 2 pieces (set) were enrolled in the study. After tissue flattening on a glass slide with a cryospray, one half was flash frozen in an isobutane histobath (-56 to -62C); the other half was frozen in the cryostat (-27 to -30C). The Mohs histotechnicians evaluated the differences in tissue separation from the embedding media, how the tissue cut, ease of achieving smooth, wrinkle-free sections,

as well as, time required for each method. Physician was blinded to the method of freezing and asked to rate each piece of the set as best and worst or equal in terms of quality of the overall histology.

Summary: A total of 41 sets were enrolled. Freeze time for the histobath method was on average 22 seconds (range 15 to 40 seconds) versus 144 seconds in the cryostat (range 90 to 240 seconds), a difference of 122 seconds. Histobath frozen tissue sections were easier for the Mohs histotechnicians to achieve smooth, wrinkle-free sections in 90% of sets. Physicians strongly favored histology from specimens flash frozen in the histobath the majority of the time over the traditional method of cryostat freezing (Fig 1).

In addition to this technique producing higher quality and more rapid frozen sections the supplies are very inexpensive after the initial purchase of the histobath (\$3600) (Fig 2). The isobutane costs \$68.00 per gallon and lasts 4-6 months in our lab. No other additional supplies are required for this alternative freezing method.

Research Abstract Session—Saturday, April 25; 12:00 – 1:00 pm

Conclusions: Flash freezing in the histobath expedites slide turn around time for Mohs micrographic surgery. It can also produce superior tissue section histology and overall slide quality by minimizing freeze artifact sample distortion.

12:11 – 12:19 pm

PRESENTER: Christian L. Baum, MD

TITLE: Mohs Micrographic Surgery for the Treatment of Atypical Fibroxanthoma

AUTHORS: Christian L. Baum, MD; Marta J. Van Beek, MD; Christopher J. Arpey, MD

Purpose: The purpose of the current study was to review the clinical characteristics and outcome of atypical fibroxanthomas treated with Mohs micrographic surgery at our institution.

Design: We performed a retrospective chart review of 26 consecutive patients with primary atypical fibroxanthoma treated with Mohs micrographic surgery from 1990-2008. Included in our data is the anatomic location of the tumor, tumor size, patient age, number of Mohs layers, size of the surgical defect, and recurrence rate.

Summary: Atypical fibroxanthoma (AFX) is a rare spindle-cell neoplasm that most often presents as a nodule on sun-exposed areas in patients over the age of 50. Although AFX is generally considered a low-grade malignancy, the tumors may be locally aggressive with significant subclinical extension. Furthermore, cases of metastatic AFX have been reported. Optimal treatment of AFX consists of surgical resection. Previous reports have demonstrated decreased recurrence and increased tissue conservation in patients with an AFX treated with Mohs micrographic surgery (MMS) compared to those treated with wide local excision. Recurrence rates of AFX treated with MMS have ranged from 0-6.9%. We present 26 consecutive cases of primary AFX treated with MMS from 1990 to 2008 at our institution. The average age of the patient at the time of diagnosis was 72 years. 100% of the lesions were located on the head and neck. The average size of the clinically-evident lesion was 1.13 cm. The average number of MMS layers was 1.6. The average size of the surgical defect was 2.8 cm. Follow-up was available for 21 patients with an average follow-up period of 30.1 months. The recurrence rate for patients not lost to follow-up was 14.3% (n=3) with recurrence being diagnosed, on average, 8.7 months after MMS. The average size of the surgical defect of tumors that eventually recurred was 4.0 cm compared to 2.8 cm for non-recurrent tumors.

Conclusions: To our knowledge, this is the largest series of primary AFX treated with MMS in the literature. Our data indicate a higher recurrence rate (14.3%) of AFX treated with MMS compared to previously described reports that ranged from 0-6.9%. These results, however, are lower than previously reported recurrence rates of up to 16% with wide

local excision. Together the size of the current series, favorable recurrence rates compared to wide excision and potential for subclinical extension of AFX support the utilization of MMS for the treatment of AFX.

12:19 – 12:27 pm

PRESENTER: John C. Perrotto, DO

TITLE: The Value of Immunohistochemistry in Discriminating Primary from Secondary Extramammary Paget's Disease

AUTHORS: John C. Perrotto, DO; Roger I. Ceilley, MD; Jared Abbott; Ifrikhar Ahmed, MD

Purpose: Extramammary Paget's disease (EMPD) is categorized into two groups: primary EMPD or EMPD secondary to underlying malignancy. Primary EMPD has a better prognosis and the ability to distinguish between the two subsets has clinical relevance. Recent studies have suggested that immunostains including CK7, CK20, and BRST-2 distinguish between the two groups. We analyzed a large series of EMPD patients with an expanded immunohistochemical panel to assess its value in distinguishing primary from secondary disease.

Design: Formalin-fixed, paraffin-embedded sections of 98 EMPD specimens from 61 patients (45 primary /16 secondary) were immunostained with cytokeratins 7 and 20, Her-2/neu, BRST-2, CDX2, and cyclin D1. The study included 44 females and 17 males (median age: 73 years). Median follow-up time was 47 months.

Summary: All EMPD specimens were vibrantly positive for CK7. The frequency of positivity for all EMPD samples was: CK20 (31%), BRST2 (34%), Her-2/neu (64%), CDX2 (10%), and cyclin D1 (69%). For primary EMPD, the frequency of positivity was: CK20 (22%), BRST2 (44%), Her-2/neu (69%), CDX2 (2%), and cyclin D1 (73%). For secondary EMPD, the frequency of positivity was: CK20 (56%), BRST2 (25%), Her-2/neu (50%), CDX2 (31%), and cyclin D1 (56%). Notably, all 7 cases of EMPD secondary to an anorectal adenocarcinoma were Her-2/neu negative and 5 of those seven cases (71%) were CDX2 positive.

Conclusions: The role of CK7, CK20, and BRST-2 in distinguishing between primary and secondary EMPD is limited since CK20 and BRST-2 were positive in large subsets of both groups. An expanded immunohistochemical panel including Her-2/neu and CDX2 may be useful in discriminating primary EMPD from EMPD secondary to anorectal adenocarcinoma but fails to distinguish primary EMPD from EMPD secondary to urothelial or prostatic malignancy. The consistent over expression of Her-2/neu in primary EMPD suggests a role for trastuzumab therapy in patients with recurrent disease.

Research Abstract Session—Saturday, April 25; 12:00 – 1:00 pm

12:27 – 12:35 pm

PRESENTER: Murad Alam, MD

TITLE: Floaters in Mohs Micrographic Surgery: Expert Consensus of Mohs Surgeons and Histotechnologists

AUTHORS: Murad Alam, MD; Sumaira Z. Aasi, MD, FACMS; Ashish Bhatia, MD; Steven J. Goulder, MD; Vivek Iyengar, MD; Nanette Liégeois-Kwon, MD, PhD; Kishwer S. Nehal, MD; Anjali D. Shah, MD

Purpose: Floaters in Mohs surgery are tissue fragments that are dislodged from their in vivo locus during tissue harvesting or preparation. Floaters, typically evident upon microscopic examination of a tissue sample, may be comprised of tumor cells, with this complicating the clearance of tumor by the Mohs technique. The purpose of this study was to elicit expert opinions and develop expert consensus among Mohs surgeons and Mohs histotechnologists regarding the causes, management, and prevention of floaters.

Design: 8 Mohs surgeons and their histotechs were asked via structured interviews to provide their views regarding the causes, management, and prevention of floaters. The same subjects were also asked: (1) to estimate the incidence of floaters in their practice; and (2) select what they considered the most likely causes from an investigator-prepared list of possible causes. For the 5 surgeons in the state, one of the investigators (ADS) visited each Mohs practice, examined the Mohs laboratory, and asked the relevant histotechs to identify equipment or steps in the preparation process that may produce floaters. Finally, glass slides and photomicrographs of representative floaters were obtained from the participating surgeons for illustrative purposes.

Summary: Most surgeons interviewed believe incidence of floaters is affected by tumor histology, with basal cell tumors seen as more friable and thus likely to develop loose tumor fragments. Floaters are generally believed to be native (arising from the same patient) than foreign (arising from a different patient), and the majority of native floaters are thought to arise from surgical technique, curetting, sectioning, and embedding. The incidence of floaters is affected by the quality of the tissue sample, including poor epidermal quality and/or overlying ulceration. The curetting step itself is believed to increase the incidence of floaters by freeing friable fragments. Most surgeons interviewed believe that floaters are more common in bulkier tumor specimens than flat specimens; that floaters are more likely to occur during the first rather than subsequent stages of Mohs; that wiping the microtome blade between cuts does reduce the risk of a floater; and that the surgeons' not changing gloves between curettage and taking of the layer is not likely to be a major factor in floater creation. Most histotechnologists believe that insufficiently clean microtome blades can increase the risk of floaters.

Regarding floater management, most surgeons try to correlate floater histology to tumor histology; assess the tissue section for holes; and take an additional Mohs stage if a floater is found on an otherwise negative stage.

Conclusions: Tissue floaters are a significant complicating feature of Mohs slide processing. Given a growing consensus regarding the possible causes, future directions may include: (1) studies to confirm that these hypothesized causes have a significant effect; (2) interventions to reduce the incidence of floaters.

12:35 - 12:43 pm

PRESENTER: Kyung H. Chang, MD, PhD

TITLE: An Automated 16-Minute Technique for Processing Mohs Sections for Melanoma

AUTHORS: Kyung H. Chang, MD, PhD; Daniel T. Finn, MD; Dennis Lee, MD; Gary S. Rogers, MD

Purpose: The challenge of complete tumor extirpation of melanoma relies on the diagnostic accuracy in the evaluation of surgical margins during Mohs micrographic surgery (MMS). Frozen sections stained by H&E are difficult to interpret. The time consumption and significant variability of staining quality has been the limiting factors in utilizing MART-1 immunohistochemical (IHC) stain for MMS. The goal of the study is to determine if an automated 16-minute protocol for MART-1 stain is a reliable tool during MMS for melanoma.

Design: A novel automated instrument that performs MART-1 staining in 15 minutes 20 seconds was used to stain a total of 40 cases of sun-protected skin, sun-damaged skin, melanoma negative control skin and melanoma positive control skin. The frozen sections were compared to permanent paraffin sections of MART-1 and H&E stains to serve as golden standards. Melanocyte density and distribution were blindly evaluated in each section by a Mohs surgeon. Statistical analysis was performed.

Summary: No statistical difference ($p>0.05$) was observed in the melanocyte density and distribution in automated MART-1 stained frozen sections compared to the paraffin sections. The MART-1 stained melanocytes in frozen and paraffin sections correlated with the H&E stained melanocytes in the paraffin sections. Frozen and paraffin sections stained with MART-1 showed no difference in both sun-protected and damaged skin.

Conclusions: Automated MART-1 IHC stain is a rapid and reliable adjunctive diagnostic method to aid in the interpretation of surgical margins during MMS for melanoma. The technique is superior to frozen or permanent H&E sections alone, and is equivalent to permanent IHC sections. The automated protocol allows rapid and consistent IHC staining with minimal labor, which enhances the accuracy and efficiency of the Mohs procedure.

Research Abstract Session—Saturday, April 25; 12:00 – 1:00 pm

12:43 – 12:51 pm

PRESENTER: Emily P. Tierney, MD

TITLE: Randomized Controlled Trial: Rapid Absorbing Gut Suture Versus Tissue Adhesive in the Closure of Linear Repairs

AUTHORS: Emily P. Tierney, MD; David J. Kouba, MD, PhD; Ronald L. Moy, MD

Purpose: The healing of surgical wounds and the impact of both suturing technique and suture material on cosmetic outcome is of utmost importance to Mohs surgeons. Cyanoacrylate (CA)-based tissue adhesives promote wound closure by self-polymerization to join the two edges of the wound and aid in re-epithelialization. 2-octylethylcyanoacrylate (OCA), a novel epidermal wound closure methodology, has theoretical benefits of elimination of trauma and suture tract marks in surgical scars. While OCA has been utilized as a wound closure technique over the past decade, there are few evidence-based trials comparing its efficacy to standard suturing techniques. The purpose of this study was to compare aesthetic outcomes and wound healing of OCA and rapid absorbing gut suture in skin closures.

Design: During the surgery, all wounds were closed using a linear, bilayered closure method, where the buried intradermal absorbing sutures (4-0 polyglactin 910) were placed along the length of the incision. The majority (75%) of these wounds were the closure of donor sites from skin graft harvesting. Patients were randomized for epidermal closure with one half of the wounds with fast absorbing gut suture and on the other half with OCA. Patients were seen for evaluation at post-operative visits at both 1 week and 3 months after the procedure. Incidence of wound dehiscence and itching, bleeding and pain were assessed at 1 week. Patient preference of closure technique and side effects were assessed at 3 months. Cosmetic outcome of wound closure technique (dyspigmentation, scar thickness, wound approximation, overall cosmetic outcome) were assessed by 2 blinded physicians at 3 months.

Summary: At 3 months, a blinded physician performed an analysis of scar healing and cosmetic outcome utilizing 4 variables: dyspigmentation, scar thickness, wound approximation and overall cosmetic outcome on a quartile scale (1-4, 1=poor scar wound healing, does not match surrounding skin, 4=excellent wound healing, scar matches surrounding skin). In terms of dyspigmentation, the half of each scar treated with fast absorbing gut had an improved outcome (mean value, 3.50) relative to that treated with OCA (2.75, $p < .05$). In terms of scar thickness, the two closure techniques had highly equivalent values at 3 months post-wound closure (mean value, 3.88, fast absorbing gut, 3.75, tissue adhesive, $p > .05$). Similarly, for wound approximation the results were equivalent between the two closure techniques (3.75, fast absorbing gut, 3.63, tissue adhesive, $p > .05$). In terms of differences in overall cosmetic

outcome between the two closure techniques, the half of each scar treated with fast absorbing gut (mean value 3.56) had an improved overall outcome relative to that treated with OCA (mean value 3.19, $p = .05$).

At 3 months post-wound closure, patients were also questioned as to their preference of wound closure method and the overall cosmetic outcome of each half of their scar (Table 2, Figure 2). Half of the patients ($n = 4/8$, 50.0%), reported that they had no preference in closure technique method. An equivalent proportion of the remaining patients reported a preference for fast absorbing gut ($n = 2/8$, 25.0%) and OCA ($n = 2/8$, 25.0%). In terms of patient scores for cosmetic outcome of the resultant scar at 3 months post-wound closure, there was no significant difference detected between the two methods, where OCA received an average score of 3.56, whereas fast absorbing gut received an average score of 3.50 ($p > .05$).

Conclusions: We found slightly higher cosmetic outcomes for the half of the wound treated with fast absorbing gut suture relative to OCA. Interestingly, the only variable in scar outcome which was greater for tissue adhesive relative to suture was incidence of dyspigmentation. In 3/8 wounds (37.5%), greater incidence of dyspigmentation was noted on the side treated with OCA, likely representing a greater inflammatory reaction to tissue adhesive in the adjacent skin relative to suture. The incidence of dyspigmentation correlated with an overall lower cosmetic outcome score in these patients. Both OCA and suture were highly equivalent in terms of approximation of wound edges and wound edge eversion. Likely the uniform placement of deep sutures in all wounds by the same surgeon allowed for equivalent approximation and wound edge. In conclusion, it is clear from the data reported herein as well as from the surgical literature that cyanoacrylate derivatives, such as octyl-2-cyanoacrylate, are safe and effective when used for closure of wounds in dermatologic surgery, varying from Mohs defects, lacerations and cosmetic surgery. Based on this study, it appears that OCA may not be as effective in achieving optimal cosmesis for defects after Mohs on the trunk and extremities in follow-up at 3 months.

12:51 – 12:59 pm

PRESENTER: Aerlyn G. Dawn, MD, MBA

TITLE: Subclinical Spread of Amelanotic vs. Pigmented Melanomas: Amelanotic Tumors Require More Stages of Mohs Surgery

AUTHORS: Aerlyn G. Dawn, MD, MBA; Christopher J. Miller, MD

Purpose: Melanomas in situ (MIS) are often clinically ill-defined. Prior studies have demonstrated that the standard recommended surgical margin for MIS of 5 mm around the clinically visible tumor is frequently inadequate. Accurate clinical assessment of tumor extent is particularly challenging for amelanotic melanomas. Authors have increasingly advocated Mohs micrographic surgery (MMS) for MIS on sun-damaged skin;

Research Abstract Session—Saturday, April 25; 12:00 – 1:00 pm

however, there are no published case series describing MMS for amelanotic melanomas. The purpose of this study was to evaluate the characteristics of amelanotic melanomas treated by MMS to determine the number of stages required and the size of surgical defects compared to pigmented melanomas.

Design: Cases of amelanotic melanomas treated by Mohs surgery at our institution, including amelanotic MIS and amelanotic malignant melanoma (MM), were retrospectively analyzed. For comparison, all cases of pigmented MIS, lentigo maligna melanoma, or pigmented malignant melanoma treated by Mohs surgery over the same 2 year period at our institution were also evaluated. For all tumors, rapid MART-1 immunostaining was used to enhance frozen section examination of tissue and to facilitate margin assessment. Data collected included patient age, anatomic site, clinical dimensions of the tumor when examined under surgical lighting and Wood's lamp, number of stages of MMS required to achieve clear margins, and dimensions of the resulting surgical defect.

Summary: Five cases of amelanotic melanomas treated by MMS were identified (see Table 1), and 91 cases of pigmented melanomas treated by MMS over the same 2 year period were

identified. The mean patient age for amelanotic melanomas was 70.8 years (range 48 – 81) vs. 65.4 years (range 29 – 93) for pigmented melanomas (see Table 2). The mean number of MMS stages required to achieve clear margins for amelanotic cases was 4.8 stages (range 2 to 7 stages) vs. 1.3 stages (range 1 to 3 stages) for pigmented melanomas. The mean ratio of surgical defect to clinical size was 12.1 for amelanotic tumors vs. 4.0 for pigmented melanomas. For amelanotic melanomas, a mean margin of at least 3.6cm would have been required to achieve tumor clearance vs. a margin of at least 1.2cm for pigmented melanomas.

Conclusions: Amelanotic melanomas treated by Mohs surgery in this series demonstrated substantial subclinical spread. The number of MMS stages required to achieve clear margins and the size of resulting surgical defects was much greater for amelanotic melanomas than for pigmented melanomas. Surgical excision with standard recommended margins would clearly have been grossly inadequate for these amelanotic tumors. This data demonstrates the advantages of MMS over other treatment modalities for amelanotic melanomas.

Poster Presentation List

Posters will be displayed in the Austin Grand Ballroom Lobby, outside the Exhibit Hall and session rooms. Posters will be displayed from 12:00 pm Thursday through 2:00 pm Saturday.

102 Single Cell Cutaneous Squamous Cell Carcinoma (CSCC): A Clinical Case Review

David E. Geist, MD; Dori Goldberg, MD; Mary E. Maloney, MD

103 Solid Organ Transplant Recipients Undergoing Mohs Micrographic Surgery: A Review of Patient Characteristics and Case Load

Edward Upjohn, MD; R. Stan Taylor, III, MD; Sarah B. Weitzul, MD; Jennifer B. Perone, MD; Erin Welch, MD

104 A Blinded Comparison of Nylon vs. Braided Polyglactin-910 Suture for Epidermal Wound Closure following Mohs Micrographic Surgery

Jason Givan, MD; Scott W. Fosko, MD; Summer R. Youker, MD

105 Ezrin Expression in Basal Cell and Squamous Cell Carcinoma

Adam Ingraffea, MD; Todd Voinovski, MD; Vincent Falanga, MD; Satori Iwamoto, MD, PhD

106 Is 45-Degree Angle Beveling Necessary for Mohs Micrographic Surgery?

Ravi S. Krishnan, MD; Jenna Gross; Morgan Vanderhorst

107 Interpreting Discordances Between Frozen and Permanent Sections in Mohs Surgery

Susan Butler, MD; Scott W. Fosko, MD

108 Clinical Accuracy of Mohs Surgeons as Compared with Dermatopathologists on Frozen Section Diagnoses at an Academic Center

J. Suzanne Mosher, MD; Suzanne Olbricht, MD

109 The Tissue Efficiency of Common Reconstructive Design and Modification

James O. Barlow, MD

110 Resistance to Microbial Penetration by Acellular Dermal Matrices

Murad Alam, MD; Elizabeth Fahrenbach; John Y. Kim; Chao Qi, MD

Poster Presentation List

- 111** Optimizing the Conditions for Bone Marrow Stem Cell Mobilization during Wound Healing
Satori Iwamoto, MD, PhD; Kendra Kobrin; Tatyana Yufit; Ina Zak; Jisun Cha, MD; Nicola Koultab, PhD; Polly Carson; Vincent Falanga, MD
- 112** Predetermining the Surgical Margin of High Risk Basal Cell Carcinomas through the Use of Clinical Predictors and Mohs Micrographic Surgery: A Validated, Model-Based Approach
Hillary Johnson-Jahangir, MD, PhD; David A. Lee, MD; Manisha Desai; Désirée Ratner, MD
- 113** The Use of High Frequency High Resolution Ultrasound Prior to Mohs Surgery
Ellen S. Marmur, MD; Eric Z. Berkowitz, MD; Brian S. Fuchs, MPH; Giselle K. Singer, BS; Jane Y. Yoo, MPP
- 114** One-Stage Earlobe and Cartilage Defect Flap Reconstruction
Kristin Herring, BS; Rachael Moore; Anna A. Bar, MD
- 115** Mucosal Advancement without Undermining in the Repair of Vermilionectomy Defects of the Lower Lip
Rupert Barry, MB, BCh, BAO; James Langtry, MD
- 116** Inexpensive Alternative to Surgical Markers that Remains Effective after Contact with Moisture: Gentian Violet, Toothpick, Microcentrifuge Tube
Teris M. Chen, MD; Rungsima Waniiphakdeedecha, MD; Tri H. Nguyen, MD
- 117** The Novel Use of a Bovine Triple Helix Collagen Micro-scaffold Wound Dressing in the Guided, Second Intention Healing of a Large and Deep Lower Extremity Mohs Defect
Quenby L. Erickson, DO; Tri H. Nguyen, MD
- 118** Localized Phaeohyphomycosis Caused by *Exophiala* Treated with Mohs Micrographic Surgery
Margaret A. Collins, MD; Juliet L. Gunkel, MD; Molly Hinshaw, MD
- 119** The Management of Parotid Fistulas after Mohs Surgery
Monika Srivastava, MD; Divya Srivastava, MD; Gangaram Ragi, MD
- 120** The First Report of Transient Peroneal Nerve Palsy in Dermatologic Surgery
Erica Lee, MD; Robin Ashinoff, MD; Vicki J. Levine, MD
- 121** Trichoblastic Carcinoma: Case Report of a Rare Entity
Parrish Sadeghi, MD; Allison T. Vidimos, MD; Michael Fritz, MD
- 122** Treatment of Primary Mucinous Carcinoma of the Skin: Meta-Analysis of 189 Cases
Murad Alam, MD; Renata Trela; Natalie Kim; Simon S. Yoo, MD; Alfred Rademaker
- 123** Sandwich Graft in the Repair of a Small Through and Through Defect on the Nose
Dori Goldberg, MD; Gary Fudem; Jeremy S. Bordeaux, MD, MPH; Mary E. Maloney, MD
- 124** Surgical Pearl: Percutaneous Suspension Suture
Antonio P. Cruz, MD; Ross Campbell, MD; Raymond G. Dufresne, Jr., MD
- 125** Closure Pearls for Defects Under Tension
Deborah J. Yang, MD; Ida F. Orengo, MD
- 126** Closure of Large Surgical Defects on the Cutaneous Upper Lip Using an Island Pedicle Flap
Theresa L. Ray, MD; Christine H. Weinberger, MD; Peter K. Lee, MD, PhD
- 127** The Use of Imatinib Mesylate as an Adjuvant Therapy to Mohs Surgery in a Child with Dermatofibrosarcoma Protuberans
Christina Wahlgren, MD; Peter Shaw; Shao Jiang; Doug Kress; Robin Gehris; Drazen Jukic; Hakeem Sam, MD, PhD
- 128** Defining Prognosis for Transected Melanomas
Jeremy S. Bordeaux, MD, MPH; Kathryn J. Martires; Ashok Panneerselvam;
- 129** A Comparison of Four Mohs Tissue Processing Methods using Procine Skin
William Lear, MD; Daniel Berg, MD; Norma Andersen
- 130** Refractory Aggressive Keratoacanthoma Centrifugum Marginatum of the Scalp Controlled with Epidermal Growth Factor Receptor Inhibitor Erlotinib
Aleksandar L.J. Kronic, MD, PhD; John Villano; Aaron Cetner, MD; Tanya K. Bulj
- 131** Algorithm for Approaching a Patient with a Newly Diagnosed Sebaceous Neoplasm
Daniel Michael, MD, PhD; Daniel B. Eisen, MD

Poster Presentation Summaries

102

PRESENTER: David Geist, MD

TITLE: Single Cell Cutaneous Squamous Cell Carcinoma (CSCC): A Clinical Case Review

AUTHORS: David E. Geist, MD; Dori Goldberg, MD; Mary E. Maloney, MD

Purpose: To assess the classification and clinical implications of single cell CSCC.

Design: Several cases of CSCC with predominately single cell features and of poorly differentiated CSCC with single cell features are reviewed for histology, clinical course and management implications.

Summary: CSCC consisting of predominately single cells or with single cells lying free from the tumor mass is a rare variant with uncertain biologic potential. Prior reports discuss single cell tumors as variants of spindle cell or desmoplastic CSCC (1, 2). A more recent report identified non-desmoplastic single cell tumors and emphasized the difficulty in recognizing these tumors histologically. Special staining with CK MNF11 and p63 aided in identification (3). In the scant prior literature, it remains unclear whether single cell tumors should be classified as a separate histologic subtype, and whether their biologic potential makes them a variant of poorly differentiated CSCC. The data presented here illustrate that these tumors tend to recur and that curative procedures are difficult. In one case, the tumor recurred after Mohs micrographic surgery (MMS). MMS with permanent staining of an additional peripheral margin then reveal persistent positive margins. Sequential overnight permanent en face sectioning ("slow Mohs") was required to achieve clear margins.

Conclusions: Single cell CSCCs are difficult to interpret on both frozen and permanent sections. Our cases series suggests that these tumors have a similar or greater risk of recurrence and metastasis than poorly differentiated CSCCs. Aggressive clinical management may be considered including wider margins, adjunctive radiotherapy or sentinel lymph node biopsy. Larger prospective series are needed to further define the biologic potential of these tumors.

(1) Cassarino DS et al. Cutaneous squamous cell carcinoma: a comprehensive clinicopathologic classification, part one. *J Cutan Pathol* 2006;33:191–206.

(2) Cassarino DS et al. Cutaneous squamous cell carcinoma: a comprehensive clinicopathologic classification, part two. *J Cutan Pathol* 2006;33:261–279.

(3) Ko CJ et al. Squamous cell carcinomas with single cell infiltration: a potential diagnostic pitfall and the utility of MNF116 and p63. *J Cutan Pathol*. 2008;35:353–357.

103

PRESENTER: Edward Upjohn, MD

TITLE: Solid Organ Transplant Recipients Undergoing Mohs Micrographic Surgery: A Review of Patient Characteristics and Case Load

AUTHORS: Edward Upjohn, MD; R. Stan Taylor, III, MD; Sarah B. Weitzul, MD; Jenifer B. Perone, MD; Erin Welch, MD

Purpose: Mohs micrographic surgery is recommended for organ transplant recipients who are immunosuppressed. Whilst the increased incidence of non-melanoma skin cancer in transplant recipients is well documented the characteristics of these patients and their tumors when treated by Mohs surgery has received less attention.

Design: A retrospective review of solid organ transplant recipients presenting to a university dermatologic surgery clinic for Mohs micrographic surgery was undertaken. Data relating to patient age, sex, tumor type, size (pre and postoperatively) and frequency of representation for further Mohs surgery was gathered and analyzed.

Summary: 27 transplant patients (25 males, 2 females) underwent Mohs surgery for 148 tumors over the course of 34 months (7 Nov 2005 to 30 Sep 2008). The mean duration of attendance of Mohs patients was 15 months (for those attending over a time span of more than 1 month) and the mean number of tumors treated per transplant patient over that time was 5.5. The ratio of SCC to BCC was 3.5:1.

There was one atypical fibrous xanthoma and one Merkel cell tumor treated. There were 13 patients with cardiac transplants, 6 with renal, 5 lung and 3 hepatic.

Conclusions: Solid organ transplant patients produce a significant and recurrent case load for a Mohs surgery unit. The most common transplant patient encountered were those with cardiac transplants, perhaps reflecting a higher level of immunosuppression usually required by these patients as compared to other organ transplant recipients. The ratio of SCC to BCC is consistent with previous studies showing a reversal in the usual ratio of BCC to SCC.

Poster Presentation Summaries

104

PRESENTER: Jason Givan, MD

TITLE: A Blinded Comparison of Nylon vs. Braided Polyglactin-910 Suture for Epidermal Wound Closure following Mohs Micrographic Surgery

AUTHORS: Jason Givan, MD; Scott W. Fosko, MD; Summer R. Youker, MD

Purpose: The use of absorbable suture for closure of epidermal wound edges is fraught with controversy. Opponents cite concerns of wound infection and suboptimal cosmetic outcomes. Proponents of absorbable suture consider these risks to be overstated, especially when sutures are removed in a timely fashion. Advocates acclaim cost reduction by maximizing the use of previously opened suture and patient preference for undyed suture material.

The purpose of this prospective, side-by-side, evaluator-blinded study was to compare the wound healing process and aesthetic outcome of surgical wounds repaired with monofilament nylon verses those repaired with absorbable braided polyglactin-910 for epidermal closure.

Design: Patients with surgical wounds of at least one centimeter in final length were evaluated. Wounds requiring flap closure were excluded. The deep portion of each wound was closed in usual fashion using polyglactin-910 dermal sutures. Each wound was then subjectively divided into two equal portions. One half of the epidermal wound was randomly closed with monofilament nylon suture. The remaining half was closed with braided polyglactin-910 of equal caliber. Wound care instructions were not altered by study participation.

Patients returned for suture removal at post-operative day five to seven and completed a questionnaire rating each half of the wound regarding suture appearance and wound symptomatology. Following removal of all epidermal suture material, a blinded evaluating physician rated each half of the wound with respect to erythema, edema, and evidence of dehiscence.

Patients returned at post-operative week six to eight to complete a second questionnaire rating each half of the scar regarding overall cosmetic appearance. A single blinded evaluating physician rated each portion of the scar with respect to overall cosmesis as well.

The primary outcome of the study was to determine if an increased risk of wound infection/complication was associated with braided polyglactin-910 suture for epidermal closure. Secondary outcomes included patient preference with regard to suture appearance and cosmetic result, as well as physician evaluation regarding cosmetic result.

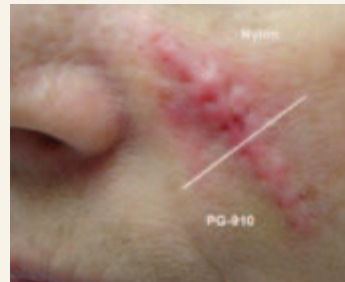Summary: Thirty-one patients with thirty-five wound repairs were enrolled. The majority of wounds were closed in complex linear fashion and all sites were located on the head or neck.

We found no increased risk of wound infection associated with braided polyglactin-910 suture for epidermal closure as there were no documented wound infections of either portion of any of the surgical sites.

Contrary to our hypothesis, we found no difference ($p=0.454$) between suture types with regard to patient perceived appearance. As expected, we found no difference with regard to patient perception of "Pain/Tenderness/Itching" ($p=0.873$) or "Redness/Swelling" ($p=0.124$). There was no difference with regard to dehiscence ($p=0.317$). In contrast to conventional dogma, we found a statistically significant reduction in peri-operative site edema ($p=0.007$) and a trend of reduced erythema ($p=0.059$) with polyglactin-910 suture closure.

Fourteen of sixteen (87.5%) subjects with at least six weeks post-operative follow-up returned for evaluation and questionnaire completion. As anticipated, we found no difference between groups with regard to patient-assessed scar cosmesis ($p=0.564$) and a single blinded evaluating physician ($p=1.00$).

Conclusions: We found no increased risk of wound infection/complication with the use of braided polyglactin-910 suture for epidermal wound closure.



Surgical wound; edema/erythema of the nylon suture portion.

Interestingly, our results show a significant reduction in peri-operative site edema with superficial closure utilizing braided polyglactin-910 suture. Reduced erythema with polyglactin-910 suture closely approached significance. Subjects failed to report a preference regarding suture material. There was no difference regarding scar cosmesis at

six to eight week post-operative follow-up. Although our numbers are small, results indicate that polyglactin-910 may be used with confidence in-lieu of nylon suture for epidermal wound closure.

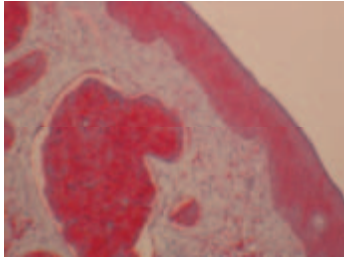
Poster Presentation Summaries

105

PRESENTER: Adam Ingraffea, MD

TITLE: Ezrin Expression in Basal Cell and Squamous Cell Carcinoma

AUTHORS: Adam Ingraffea, MD; Todd Vinovski, MD; Vincent Falanga, MD; Satori Iwamoto, MD, PhD



Increased ezrin immunoreactivity in basal cell carcinoma.

Purpose: Ezrin is a member of the Merlin-Ezrin-Radixin-Moesin group of proteins that link the cytoplasmic membrane to the actin cytoskeleton. Ezrin binds to the cell membrane through interactions with a variety of proteins, including CD 44 and ICAM-1 and -2. Through its interactions with the cell membrane and f-actin cytoskeleton, ezrin is believed

to help regulate cell to cell adhesion and migration. Ezrin also has an important role in several signaling pathways involved in cell survival and proliferation, including the Rho-GTPase and PI-3/Akt pathways. Several recent studies have indicated that increased ezrin expression is associated with aggressive behavior and metastatic spread in a variety of human cancers, including breast carcinomas, osteosarcomas, malignant fibrous histiocytomas, and malignant melanomas. Little is known about the function of ezrin in the skin and in non-melanoma skin cancers. In this study we investigated ezrin immunoreactivity in cases of cutaneous basal cell carcinoma and squamous cell carcinoma.

Design: Surgical specimens from a total of eight patients with non-melanoma skin cancers, which included five basal cell and three squamous cell carcinomas, were evaluated for ezrin expression. All examples were from surgical excisions and included margins of uninvolved skin, which served as internal controls. The tissues were analyzed by immunostaining after standard processing and paraffin embedding. Four micron sections were baked overnight at 37 degrees Celsius and then deparaffinized and re-hydrated. They were then blocked for peroxidase activity with 1% hydrogen peroxide in methanol for thirty minutes and washed under running water for five minutes. After antigen retrieval, the sections were incubated with purified ezrin rabbit anti-human antibody overnight at 4 degrees Celsius. The secondary antibody was goat anti-rabbit. All incubations were carried out in a humid chamber at room temperature. The slides were then developed using permanent red as a substrate and counter stained with Mayer's hematoxylin. The slides were then reviewed for ezrin expression.

Summary: Ezrin was expressed in the normal human epidermis, and was most prominent in the stratum basale and spinosum. As expected from its reported functions, ezrin is expressed strongly around the cytoplasmic membrane of human keratinocytes. It is also strongly expressed in sebaceous glands, hair follicles, eccrine glands and the endothelial lining of vessels. It was also strongly expressed by inflammatory cells around blood vessels and tumors but not in dermal fibroblasts. Ezrin immunoreactivity was dramatically prominent in basal cell and squamous cell carcinomas. In basal cell carcinomas ezrin immunoreactivity spared the peripherally palisading cells of tumor islands and was increased in the cells forming the bulk of the tumor.

Conclusions: Ezrin is a component of the normal human epidermis and appendageal structures. Ezrin immunoreactivity is increased in basal cell and squamous cell carcinomas. This early report suggests that ezrin expression may help in delineating the extent and margins of basal cell carcinoma and may be a useful marker for cutaneous carcinomas. More work is needed to determine whether this molecule plays a role in the pathogenesis of these tumors.

106

PRESENTER: Ravi S. Krishnan, MD

TITLE: Is 45-Degree Angle Beveling Necessary for Mohs Micrographic Surgery?

AUTHORS: Ravi S. Krishnan, MD; Jenna Gross; Morgan Vanderhorst

Purpose: Traditionally, when taking a Mohs layer, the surgeon excises the tumor with a 45-degree bevel instead of the 90-degree angle which is employed when performing an ordinary surgical excision. The 45-degree angle is used in order to make tissue mounting and slide preparation easier for the histotechnician, so that the entire margin of the specimen can be examined microscopically. However, the 45-degree angle carries with it one great disadvantage: in order to be able to excise the tumor with a 45-degree bevel, the surgeon must take the layer slightly further from the clinically apparent margin of the tumor than he would with a 90-degree excision to avoid cutting into the tumor (Figure 1). This can potentially result in the unnecessary excision of unaffected tissue.

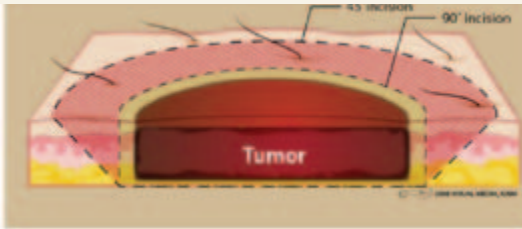
Design: In 50 consecutive patients, we took Mohs layers in such a way that one half of the layer was excised with a 45-degree bevel and the other half was excised without beveling (i.e., at 90-degrees). Slides were prepared by blinded, novice (< 2 months experience) histotechnicians. We then evaluated the slides that were produced, paying specific attention to the number of sections necessary for the entire margin to be fully visualized for each type of beveling.

Summary: There was no statistically significant difference in the mean number of sections needed to visualize the entire

Poster Presentation Summaries

margin of the excised specimen (entirety of the epidermis and deep tissue) for each technique. The mean number of sections needed at a 90-degree cut was 3.4 (SD=1.8), and the mean number of sections needed at a 45-degree cut was 3.2 (SD=1.7). Based on the paired t-test, there was no significant difference in the mean number of sections needed between the two angles ($p=0.29$). When subgroup analyses were performed, we also found no difference between the techniques related to body site, tumor type, thickness of specimen, or size of specimen.

Conclusions: High quality slides, which will allow the Mohs surgeon to examine the entire margin, can be easily produced without beveling. Avoiding beveling will allow the Mohs surgeon to preserve healthy tissue without sacrificing slide quality.



107

PRESENTER: Susan Butler, MD

TITLE: Interpreting Discordances Between Frozen and Permanent Sections in Mohs Surgery

AUTHORS: Susan Butler, MD; Scott W. Fosko, MD

Purpose: When performing Mohs surgery, it is common practice for some surgeons to submit a case for permanent sections for various reasons, such as confirming clear margins or perineural invasion seen on frozen sections. Occasionally, the permanent sections and frozen sections obtained during the Mohs case are discordant. The etiology of this discordance and how often it occurs is not clear. A possible explanation is that the frozen section was not of sufficient quality for the tumor to be recognized. Alternatively, the tumor may not have been present on the frozen section but appeared only on the permanent sections which were cut from deeper into the block.

Previous studies in the pathology literature have shown frozen/permanent concordance rates as high as 98.6% with regards to diagnosis, though these studies often excluded cases in which the intent was to examine the margin, because the permanents may not represent the true margin as they are obtained from deeper into the block. Considering this limitation of permanent sections, it is difficult to determine the significance of this discordance in Mohs surgery where the primary focus is to obtain clear margins. It is unclear whether the tumor seen on permanent sections in these situations should be treated as a false positive or clinically relevant.

This same phenomenon can be involved when obtaining additional frozen sections during Mohs cases to adequately assess the margin. If that one additional section cuts into tumor in an area that was clearly tumor-free on previous sections, the clinical relevance of that "positive margin" is in question. Exploring current practices of fellowship-trained Mohs surgeons in the scenarios outlined above may be helpful when faced with these difficult situations.

Design: An e-mail was sent to all of the members of the American College of Mohs Surgery with an e-mail address published in the ACMS 2007 membership list, inviting them to participate in an electronic survey. All data collected was de-identified, encrypted and transmitted over a secure network. The survey collected information regarding demographic data, frequency and experience obtaining permanent sections, and concordance rates between frozen and permanent sections.

Summary: A total of 791 e-mails were sent. Approximately 137 of those e-mails did not reach the intended participant due to an invalid address or full mailbox. At the time of submission of this abstract, 100 participants had responded to the survey. Seventy percent were in private practice.

Most (55%) surgeons submit for permanent sections 1-3 times/year, though 31% submit at least once/month. The most common reason to submit at case for permanent sections was confirming negative margins after clear on frozens (73%), followed by confirming a new separate diagnosis seen on frozens, obtaining special stains, and finally evaluating for perineural/intravascular involvement.

Nearly half (47%) had submitted a case to confirm negative margins and had permanent sections show tumor. When respondents went back to review the frozen sections in that scenario, tumor was still not appreciated on the frozen sections always (51%) or most often (36%). Just over half (52%) conclude that tumor seen on permanent sections but not frozens is a result of cutting further into the block and not clinically significant, though just over half still remove more tissue (51%).

Regarding the technical aspect of their practice, 68% of surgeons report orienting the tissue in the Mohs fashion when submitting for permanents. Most often (64%), the histotech inks and grosses the specimens while other lab personnel embed it in cassettes, cut sections, and stain the tissue.

When examining multiple slides for a Mohs stage, most (67%) report that they would not take another stage if only one slide shows tumor and it clears by the slide most representative of the margin. Those in an academic setting were significantly more likely to take another stage than those in private practice ($p=.02$). Most (65%) obtain an additional section off the block to further evaluate the margin on a stage at least once/week. While 94% have had the additional re-cut slide show tumor where it had been negative on previous slides, most (57%) do not take another stage because the tumor was clear on previous slides.

Poster Presentation Summaries

Conclusions: A large percentage of Mohs surgeons frequently submit cases for permanent sections, and most have experienced discordant results. Frequently they believe tumor seen on permanent sections may not have clinical significance, however most still take additional tissue based on that information.

Though a similar situation is experienced by most surgeons who see tumor show up in additional slides obtained to evaluate the margin during Mohs cases, most surgeons do not remove more tissue based on these frozen sections. Exploring practices of Mohs surgeons can offer insight into the relevance of positive margins obtained on permanent and frozen sections.

108

PRESENTER: J. Suzanne Mosher, MD

TITLE: Clinical Accuracy of Mohs Surgeons as Compared with Dermatopathologists on Frozen Section Diagnoses at an Academic Center

AUTHORS: J. Suzanne Mosher, MD; Suzanne Olbricht, MD

Purpose: The purpose of this study is to assess the agreement between frozen section diagnoses by Mohs surgeons and dermatopathologists at an academic center.

Design: We performed a retrospective chart review of 2000+ cases of frozen sections performed in our Mohs surgery practice from January, 2003 through October, 2008. For each section, comparison was made between the frozen section diagnoses by the Mohs surgeon who performed the case, along with the permanent section evaluated by the dermatopathologist. During this period of time, 7 Mohs surgeons and 4 dermatopathologists were employed by our clinic. Our primary outcome measures included the correlation between diagnoses of "benign" versus "malignant" lesions and the correlation between diagnoses of actinic keratoses versus squamous cell carcinoma in-situ. Both endpoints were selected for their relevance to clinical practice, in that increased accuracy determines the appropriate implementation of the Mohs procedure, and the latter specifically highlighting the importance of distinguishing this subtle spectrum as it relates to that decision. For any discrepancies in the data, or conflicting reports (e.g. tumor found on frozen section but not permanent section or vice-versa), we will pull the old slides and compare the two in a blinded fashion with 2 board certified Mohs surgeons. Finally, we will evaluate for any significant or recurrent discrepancies between the diagnoses of Mohs surgeons and dermatopathologists and determine whether any relevant conclusions can be drawn that might impact clinical practice.

Summary: Preliminary results show that Mohs surgeons and dermatopathologists agreed in approximately 80% of cases in distinguishing benign versus malignant lesions (e.g., there was upwards of a 20% false positive rate for the Mohs surgeons,

with considerable variability across individual Mohs surgeons (range 6-30% false positive rate). In addition, Mohs surgeons agreed with dermatopathologists in approximately 80% of diagnoses of AK versus SCCIS, with Mohs surgeons overcalling these lesions in 15% of cases and under calling them in approx 5% of cases. These numbers may change with final review, as we have not yet removed conflicting data (e.g. where tumor was only found on frozen section and not permanent section, leading to a temporary discord that we can resolve only after pulling the slides for a blind review). Our current data includes these discrepancies as counting against the Mohs surgeons.

Conclusions: We will need to continue to analyze our data before drawing more specific conclusions.

109

PRESENTER: James O. Barlow, MD

TITLE: The Tissue Efficiency of Common Reconstructive Design and Modification

AUTHOR: James O. Barlow, MD

Purpose: To analyze the quantity and potential variability of redundant tissue loss, i.e. burrows triangles, encountered during the use of conventional reconstructive techniques through the calculation of tissue efficiency.


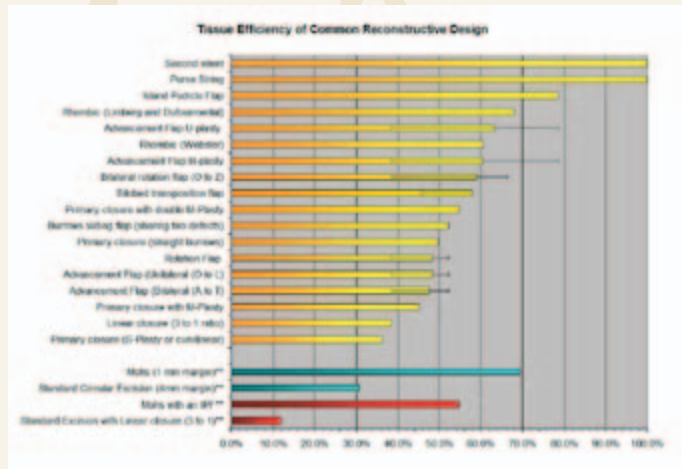
Design: Conventional reconstructive designs were applied to a standard circular defect using computer aided drafting (CAD) software to determine the surface area of each closure design. Tissue efficiency was defined as the surface area of the defect divided by the total surface area of tissue loss after reconstruction.

$$\text{Tissue Efficiency} = (\text{SA}_{\text{defect}}) / (\text{SA}_{\text{defect}} + \text{SA}_{\text{burrows}})$$

Summary: The CAD designs of the reconstructive techniques demonstrate that the island pedicle flap (78.5%) and rhombic flap (68.0%) are the two most tissue efficient reconstructive designs commonly used to reconstruct wounds following skin cancer removal. Many of the traditional reconstructive designs and novel design modifications improve both tissue recruitment and tissue efficiency when compared with the simple linear closure.

Conclusions: Reconstructive techniques consume a highly variable amount of additional normal tissue when used to reconstruct surgical wounds following skin cancer removal. The classical elliptical linear closure actually removes a greater amount of normal tissue than the size of the original surgical defect. Tissue efficiency is a significant advantage that most flaps have in repairing wounds in critical anatomic locations. Many modifications of classical reconstructive designs can further improve tissue efficiency through additional tissue recruitment and the elimination of secondary burrows triangles. Tissue conservation, applied to the choice and design of reconstructive techniques, can further reduce the morbidity of cutaneous tumors.

Poster Presentation Summaries



110

PRESENTER: Murad Alam, MD

TITLE: Resistance to Microbial Penetration by Acellular Dermal Matrices

AUTHORS: Murad Alam, MD; Elizabeth Fahrenbach; John Y. Kim; Chao Qi, MD

Purpose: Acellular dermal matrices are skin and subcutaneous substitutes that are used for skin repair and surgical reconstruction. Compared to autologous grafts, acellular materials do not require creation of a donor site defect and enable the coverage of large defects. Since such acellular dermal substitutes may be implanted permanently, their susceptibility to infection is a relevant feature. The purpose of this study is to investigate how commercially available dermal matrices compare to one another in their ability to act as barriers to microbial penetration in vitro.

Design: A pilot study was performed to determine the appropriate microbial concentrations for an in vitro comparison of the ability to serve as a barrier to microbial penetration of 4 commercially available dermal matrices: Alloderm (LifeCell), FlexHD (MTF), Neoform (Mentor Corp), and Strattice (LifeCell).

Twenty 1 x 2 cm pieces of each dermal substitute were placed on top of blood agar culture medium, yielding 80 plates. As our pilot study identified 106 CFU/ml as the appropriate bacterial dose, four solutions of this concentration were created for *Staphylococcus aureus*, *Pseudomonas aeruginosa*, *Streptococcus pyogenes*, and *Candida albicans*. For each of the 4 acellular dermal materials, 5 plates were inoculated with 1 microliter of 106 CFU/ml each for each of the 4 bacterial solutions; thus 20 plates were prepared for each acellular dermal material.

The 80 plates were then incubated for 3 days in air at 37 degrees C. After the incubation period, the patches were carefully peeled away from the blood agar plate, and a 3 mm punch biopsy was obtained of the culture medium below the piece of acellular dermal material. The punch specimens were placed in separate tubes with 5 ml of BHI broth and shaken for 2 hours at 37° C. For each sample of broth a blood agar plate was inoculated with a 0.001 ml calibrated loop in the way that is done for quantitative urine culture. One colony from 0.001 loop streaking represents 1000 CFU/ml. These plates were incubated overnight and a colony count was performed the following day.

Summary: Alloderm acted as the best barrier to bacterial penetration. *S. aureus* and *S. pyogenes* were unable to penetrate Alloderm, and *P. aeruginosa* penetrated two out of five pieces of Alloderm. Flex HD followed Alloderm, functioning as a good barrier to penetration by *S. aureus* and *S. pyogenes*. However Flex HD was not able to prevent penetration of *P. aeruginosa*. Strattice performed well against the gram positive organisms, preventing penetration of *S. pyogenes*, and allowing penetration of relatively few organisms of *S. aureus* (185 colonies counted on Strattice plate #1 and 208 counted on plate #5). However, unlike Alloderm, Strattice was not able to prevent penetration of *P. aeruginosa*. Neoform exhibited the least ability to act as a barrier to bacterial penetration as uncountable numbers of bacterial colonies were obtained for *S. aureus*, *P. aeruginosa*, and *S. pyogenes*. That *P. aeruginosa* was able to penetrate the most pieces of acellular material may be due to its motility as a flagellated organism. As for the ability of acellular dermal substitutes to act as a barrier to *Candida* penetration, the results of this study are inconclusive. The cultures showed no evidence of *Candida* penetration for any of the dermal substitutes studied, with this outcome possibly secondary to an inappropriately low concentration of *Candida* in the inoculum.

Conclusions: There appear to be differences among commercially available acellular dermal matrices regarding their microbial barrier function. While the structural and performance characteristics of a given acellular material may impact its relevance for a specific clinical use, microbial resistance information may be one factor taken into account by practitioners selecting appropriate materials. Further studies are needed to assess the fungal resistance of these materials.

Poster Presentation Summaries

111

PRESENTER: Satori Iwamoto, MD, PhD

TITLE: Optimizing the Conditions for Bone Marrow Stem Cell Mobilization during Wound Healing

AUTHORS: Satori Iwamoto, MD, PhD; Kendra Kobrin; Tatyana Yufit; Ina Zak; Jisun Cha, MD; Nicola Kouttab, PhD; Polly Carson; Vincent Falanga, MD

Purpose: Wound healing is a process common to each of the reconstructive options following Mohs micrographic surgery, whether the reconstruction is by secondary intention, linear closure, flap closure, skin graft or composite graft. There are data showing that stem cells can accelerate wound healing and diminish scarring. We have recently shown that stem cells accelerate healing both in animal models and in human acute (post-Mohs surgery) and chronic wounds. The purpose of this study was to optimize conditions that stimulate stem cells, using granulocyte colony stimulating factor (GCSF) to mobilize stem cells from the bone marrow to the peripheral blood. Such mobilization would facilitate the use of stem cells in wound healing.

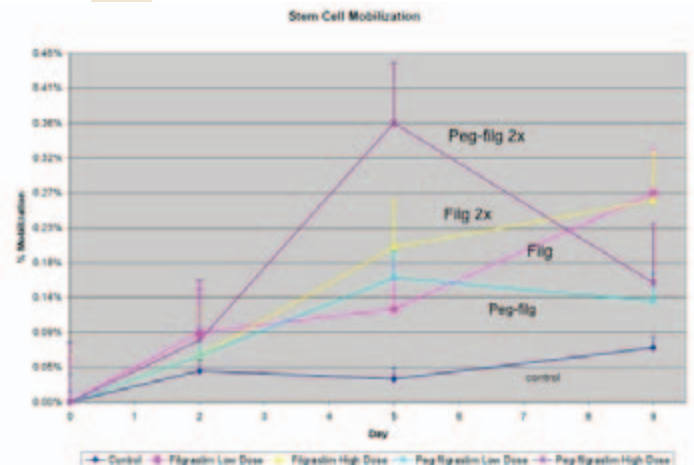
Design: There are two main approaches to deploy bone marrow-derived stem cells in order to accelerate wound healing. The first approach, which our group recently reported (Falanga, Iwamoto, et al, Tissue Engineering, 2007, 13:1299-1312) is to aspirate stem cells from the bone marrow, expand them in vitro, and then physically transfer them to the wound site using a fibrin spray. We found this approach to be very feasible after Mohs surgery and when secondary intention healing is desirable or necessary. However, this approach is not possible in the healing of post-Mohs surgical defects or reconstructions that are no longer open—i.e., those wounds closed by linear closures, flap closures, skin grafts, or composite grafts. For those closed wounds, a second approach involving coaxing stem cells out of the bone marrow into the peripheral blood, using approved cytokines such as GCSF, to be recruited to the wound site may be a better option. Moreover, identifying ways to make this approach feasible in Mohs surgery would have potential benefits in situations where healing is likely to be a problem. Previous work from our group has also shown that the topical application of stem cells to the wound can decrease scarring. Hence, stem cell mobilization may have this additional and desirable benefit in Mohs surgery or other surgical procedures.

However, as we began to investigate bone marrow stem cell mobilization, we realized that surprisingly little has been reported about the optimal conditions and parameters for mobilizing stem cells from the bone marrow, either in humans or animal models. To fill this deficiency, we now report our results using bone marrow stem cell mobilization by GCSF in mice. It is our intent to ultimately determine the best conditions that can work in humans and adopt them for use in wound healing.

To this end, C57BL/6 mice were injected with filgrastim (recombinant human GCSF) at daily doses of either 250 mcg/kg or at 500 mcg/kg, or peg-filgrastim (a long lasting GCSF formulation) injected with a single dose of either 250 mcg/kg or 500 mcg/kg, at various time points. Five mice were used in each group, and the results were compared to five control mice injected with phosphate buffered saline. Stem cell mobilization was monitored by flow cytometric measurements of cells expressing the standard stem cell markers sca-1 and c-kit, as well as by the measurement of total white blood count.

Summary: Our results showed maximal and statistically significant stem cell mobilization from the bone marrow into the peripheral blood by day 5 of the cytokine treatment, with either filgrastim or peg-filgrastim showing a convincing dose response (see graph).

Conclusions: These data indicate that there are optimal conditions to achieve bone marrow stem cell mobilization. Once further optimized and tested in a wound healing situation, these parameters could be used to accelerate the healing of human acute wounds after Mohs surgery and, possibly, to reduce scarring.



Time course and dose response of GCSF-mediated stem cell mobilization.

112

PRESENTER: Hillary Johnson-Jahangir, MD, PhD

TITLE: Predetermining the Surgical Margin of High Risk Basal Cell Carcinomas through the Use of Clinical Predictors and Mohs Micrographic Surgery: A Validated, Model-Based Approach

AUTHORS: Hillary Johnson-Jahangir, MD, PhD; David A. Lee, MD; Manisha Desai; Désirée Ratner, MD

Purpose: A standard surgical margin for removal of basal cell carcinoma (BCC) has never been firmly established. Our goal was to develop a simple model that accurately predicts the number of millimeters required for clearance of high risk BCC.

Poster Presentation Summaries

Design: We prospectively evaluated 513 patients with biopsy-proven BCCs who underwent Mohs micrographic surgery over a 26 month period. We measured the preoperative and final defect sizes and the amount of tissue stretch occurring after specimen removal. Potential predictors were age, gender, race, tumor site, and primary versus recurrent status. Additionally, a subset of the patients with BCCs was further studied to assess the role of histologic subtype as a predictor. Biopsy specimens of BCCs from 217 patients were characterized for histologic subtype including superficial, nodular, micronodular, morpheiform, infiltrative, or combinations thereof. We used standard linear regression and cross-validation tools to develop and validate a predictive model. The number of millimeters required for tumor clearance was defined as the difference between the final defect size, after accounting for tissue stretch, and preoperative tumor size.

Summary: When evaluating the predictors simultaneously, race, age, tumor size, and tumor site demonstrated strong predictive ability. Validation tools indicated our model predicts the number of millimeters required for clearance with a median absolute prediction error of 1.75 mm for BCCs regardless of histologic subtype. Evaluation of histologic subtype as a predictor and its role in our model is underway.

Conclusions: Using race, age, tumor size and location as predictors, we have developed a model that predicts the number of millimeters required for clearance of high risk BCCs. Despite being a practical tool, this model should not circumvent the need for Mohs surgery, as BCCs may grow asymmetrically and therefore require careful examination of all margins to achieve maximal cure rates and tissue conservation.

113

PRESENTER: Ellen S. Marmur, MD

TITLE: The Use of High Frequency High Resolution Ultrasound Prior to Mohs Surgery

AUTHORS: Ellen S. Marmur, MD; Eric Z. Berkowitz, MD; Brian S. Fuchs, MPH; Giselle K. Singer, BS; Jane Y. Yoo, MPP

Purpose: The objective of the study was to explore the clinical application and use of high frequency, high resolution ultrasound (HRUS) in Mohs micrographic surgery; to evaluate its ability to determine lesion borders; to determine if HRUS provides a clinical advantage when planning a Mohs procedure with regard to determining the width and length of lesions; and to evaluate whether the use of an ultrasound can reduce the number of Mohs stages necessary to be clear of tumor.

Design: This was an IRB approved single-center study of twenty six patients scheduled for Mohs surgery with lesions on flat surfaces (chest, back, extremities and face). The investigator demarcated and documented clinical estimation of the first stage. Ultrasound images were then taken and length and

width were documented. Extirpation of tumor and histological analysis was performed using standard Mohs technique. Statistical analysis was performed with Stata 8 (Stata Corp, College Station, Tex).

Summary: A paired-samples t-test revealed no significant difference between clinical and US widths ($t=-1.324$, $p=0.201$). Similarly, there was no significant difference between the lengths found from clinical assessment vs. ultrasound ($t=-1.093$, $p=0.289$). Among different tumor types, there was no significant difference between clinical and US widths or lengths for BCC ($t=-1.307$, $p=0.228$; $t=-1.389$, $p=0.202$) or SCC ($t=-0.342$, $p=0.734$; $t=0.427$, $p=0.679$), respectively.

Conclusions: There is a diagnostic role for high resolution ultrasound in Mohs surgery, especially regarding the delineation of surgical margins. This feature may assist in the preoperative evaluation of skin tumors particularly in areas where there is a need to preserve normal skin. However, the limitations of this technology preclude its practical adoption at this time.

114

PRESENTER: Kristin Herring, BS

TITLE: One-Stage Earlobe and Cartilage Defect Flap Reconstruction

AUTHORS: Kristin Herring, BS; Rachael Moore; Anna A. Bar, MD

Purpose: Many surgical earlobe repair techniques require complicated flap designs and multiple-stage reconstructions. In this poster presentation, we present a one-stage flap repair of a large earlobe defect that extends into the surrounding cartilage which provides a donor site that is well-matched to earlobe skin in texture, hair growth, and color.

Design: A 60-year-old man presented with a left earlobe basal cell carcinoma measuring 1.0 x 1.0 cm. Mohs micrographic surgery was indicated based on the location and poorly-defined margins. A six-stage procedure achieved tumor free margins, resulting in a 2.6 x 2.0 cm full thickness earlobe defect (Fig 1). Portions of the inferior helical and anti-helical cartilage were also removed.

Summary: A tunneled island pedicle flap to repair earlobe defects involves a two-stage repair and may leave the earlobe with an anterior pull requiring a third corrective procedure. Also, it has not been described for defects extending beyond the lobule. Similarly, Limberg and bilobar postauricular transposition flaps are two-stage procedures and have only been described for the reconstruction of defects confined to the lobule. A bilayered banner transposition flap from the preauricular and mandibular skin is a one-stage procedure used to reconstruct lobule defects involving portions of the auricular cartilage. However, the donor sites are often hair-bearing. Earlobe reconstruction with double-crossed skin flaps is a single-

Poster Presentation Summaries

stage repair, but can require a future corrective procedure to deepen the pre-lobular notching and requires incisions in the pre-auricular and the infra-auricular skin.

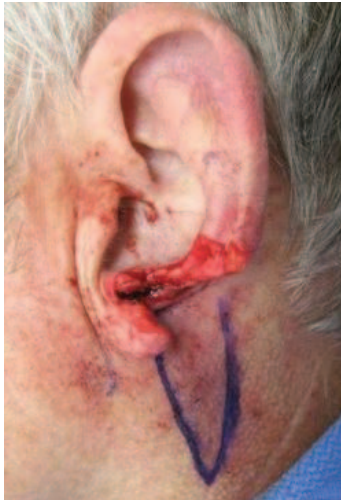

Fig 1. Primary defect following Mohs surgery with the donor site outlined.

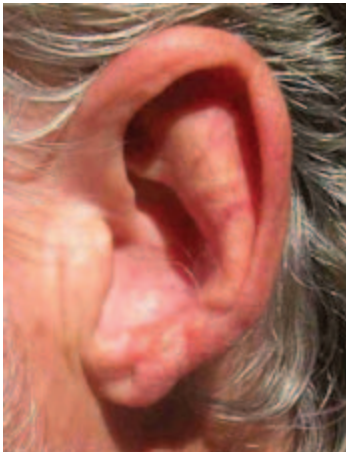

Fig 2. Surgical site seven months post-operatively.

necrosis. At seven months follow-up, the earlobe was healed and the patient was satisfied with the cosmetic appearance (Fig 2). The helical rim had slightly less bulk due to scar contracture. Designing the flap slightly larger would have reduced this asymmetry.

Conclusions: When considering how to repair our patient's particular defect, we considered several factors: it was full-thickness involving earlobe and cartilage, the patient requested a one-stage repair, and we wanted the best cosmetic outcome. The primary defect was repaired using a one-stage V-shaped infra-auricular transposition flap (Fig 1). It was a good match for the earlobe in color and consistency. The width of the flap equaled the width of the primary defect, and the length was estimated based on the need to cover both the anterior and posterior portions of the defect, with the addition of a few millimeters to compensate for the length lost in flap rotation. Final flap dimensions were 5.3 x 2.0 cm. The donor flap was excised and the secondary defect was closed. Donor tissue was overlapped on itself, thinned in areas to form the helical and anti-helical contours, and sutured into place. Redundant tissue was removed behind the ear. At two weeks follow-up, the wound was healing well without evidence of flap

115

PRESENTER: Rupert Barry, MB, BCh, BAO

TITLE: Mucosal Advancement without Undermining in the Repair of Vermilionectomy Defects of the Lower Lip

AUTHORS: Rupert Barry, MB, BCh, BAO; James Langtry, MD

Purpose: We present a case series of nine patients who underwent labial mucosal advancement, post-vermilionectomy, without undermining of either the labial mucosa or the cutaneous lip.

Design: Previous reports of the operative technique of labial mucosal advancement have described undermining of the labial mucosa at a level deep to the minor salivary glands as well as undermining of the cutaneous lip so that irritating beard hairs may be removed. We present a series of nine patients with mucosal advancement without undermining. We discuss the surgical technique, outcomes and discuss the literature.

Summary: Nine patients underwent vermilionectomy of the lower lip between 2006-2008 in a university hospital based Mohs unit. All operations were performed by the same surgeon. The indication for treatment was squamous cell carcinoma in six patients and severe actinic cheilitis in three. Five patients were male. The age range was between thirty-one and eighty-one. Two were cigarette smokers. All patients were reconstructed with labial mucosal advancement. Undermining was not performed on the mucosal or cutaneous wound margins. The labial mucosa was sutured directly to the cutaneous lower lip with either absorbable or non-absorbable sutures. Postoperatively, wound margin crusting was seen in five cases and transient lip tenderness in one patient. Six months on, one patient reported a band of numbness below the vermilionectomy scar and another patient gave a history of intermittent paraesthesiae of the lower lip and mild labial scar tension. A good cosmetic outcome was obtained and full lower lip function was preserved in all cases.

Conclusions: A follow-up study of fifty-two vermilionectomy patients reported that ninety per cent had postoperative symptoms which included paraesthesiae, pruritus and tenderness as well as anaesthesia of the cutaneous lip below the scar-line¹. These symptoms persisted in one-third of cases for up to one year postoperatively and in this series, up to one-third of patients reported significant labial scar tension three months after surgery though this had improved by six months. Although our series is smaller, postoperative symptoms were relatively few. We propose that this may be due to the lack of undermining in our technique.

1 Sanchez-Conejo-Mir J, Perez Bernal A.M., Moreno-Gimenez J.C., Camacho-Martinez F. Follow-up of vermilionectomies: Evaluation of technique. *J Dermatol Surg Oncol* 1986;12(2):180-184.

Poster Presentation Summaries

116

PRESENTER: Teris M. Chen, MD

TITLE: Inexpensive Alternative to Surgical Markers that Remains Effective after Contact with Moisture: Gentian Violet, Toothpick, Microcentrifuge Tube

AUTHORS: Teris M. Chen, MD; Rungsima Waniphakdeedechea, MD; Tri H. Nguyen, MD

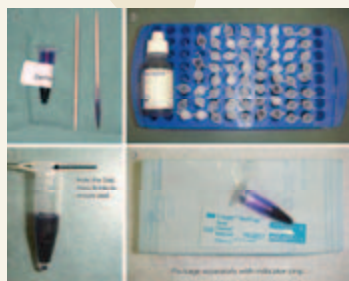

Fig 1. Gentian violet marking system. Labeled microcentrifuge tube and two round, wood toothpicks. Cotton tip applicators with wood end shaved to a fine point may also be used (A). Microcentrifuge tube rack may be used to facilitate preparation of multiple tubes for autoclaving (B). The cap should be pressed firmly to ensure a tight seal (C). The tube may be packaged separately (D), for autoclaving in case a spill does occur.

Purpose: Surgical site infections have been caused by gentian violet (GV) marking solutions that were contaminated with *Mycobacterium chelonae*. GV solution is commercially available as a solution that may not have been prepared under sterile conditions. The authors describe a skin marking method that is sterile, effective, and economical.

Design: GV solution, microcentrifuge tubes, and round, wood toothpicks are used as an alternative to the standard surgical marker. GV (4 drops) is dispensed into a microcentrifuge tube. After capping, the tube is autoclaved. The toothpick is used as the writing instrument and dipped into the gentian violet as needed

for intraoperative skin marking. Unlike commercially available skin markers, skin moisture will not cause the writing implement (toothpick) to become ineffective; merely dry the skin before skin marking.

Summary: Autoclaving the commercially available shelved GV solution ensures sterility. The cost of the gentian violet, toothpicks, and microcentrifuge tubes is approximately \$0.07 to \$0.10 per operation. In contrast, commercially available surgical markers range in cost from \$0.79 to \$3.89 per pen (MSRP), a 7- to 55- fold difference.

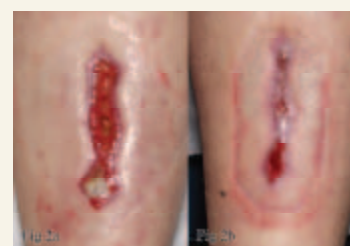
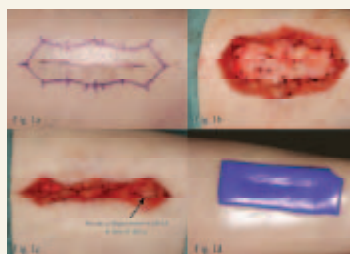
Conclusions: Infectious precautions should be taken with surgical site marking. Marking solutions should be prepared under sterile conditions in a pharmacy. Alternatively, commercially available non-sterile solutions can be autoclaved to ensure sterility.

117

PRESENTER: Quenby L. Erickson, DO

TITLE: The Novel Use of a Bovine Triple Helix Collagen Micro-scaffold Wound Dressing in the Guided, Second Intention Healing of a Large and Deep Lower Extremity Mohs Defect

AUTHORS: Quenby L. Erickson, DO; Tri H. Nguyen, MD



Purpose: Defects on the lower extremities routinely present wound-healing challenges. Prolonged healing time and unsightly scars with contour abnormalities are common. Our novel use of a bovine collagen micro scaffold wound dressing in the guided, second intention healing of a large lower extremity defect resulted in a relatively short healing time and an excellent overall result without contour abnormalities. Infection and venous stasis

were prevented by the use of gentian violet- and methylene blue-impregnated dressing, cephalexin 2mg preoperatively and 500mg four times daily for 10 days postoperatively and a compression garment. This case highlights multimodal approach required for the management of large lower extremity tumors.

Design: A 40-year-old woman presented for Mohs micrographic surgery with an incompletely-excised, 6.2cm indeterminate fibrohistiocytic tumor of unclear classification on the left anterior lower extremity. The tumor was cleared using the Angulated Mohs technique in one stage of 8 sections (Fig 1a). The final defect size was 8.0 cm x 4.8 cm and extended to the fascia (Fig 1b). The wound was partially narrowed with buried pulley sutures, resulting in a 8.0 cm x 1.5 cm defect (Fig 1c). A purified, bovine triple helix collagen micro scaffold biodegradable dressing was placed over the fascia in the base of the wound to act as a protective, absorptive dermal scaffold which facilitated fibroblasts migration (Fig 1c). The wound was then dressed with gentian violet and methylene blue impregnated polyvinyl alcohol foam sponge and covered with a transparent semipermeable adhesive film (Fig 1d), and a compression stocking providing 20-30mmhg of pressure. The collagen micro-scaffold was left in the base of the wound while the gentian violet and methylene blue dressing was changed every third day. Greater than 90% of the wound had healed via secondary intent by post-operative day 14 with minimal erythema, purulence, and fibrinous exudate (Fig 2a). By the fifth post-operative week, the wound had only a 7mm distal erosion and had regained its normal, pre-operative contour (Fig 2b).

Poster Presentation Summaries

Summary: We observed more rapid healing and better contour restoration when compared to similar wounds on the lower extremity.

Conclusions: This case highlights a highly effective, multimodal approach of the management of a large lower extremity tumor which employed purified bovine collagen micro scaffold as a filler agent and the use of an antibacterial dressing with compression. These measures resulted in healing and cosmesis that in our experience with lower extremity wounds, was unusually rapid with minimal morbidity.

This result demonstrates the need for further investigation in the use of collagen micro scaffold in large deep defects where delayed healing is common. Further study is also needed to compare efficacy of the wide variety of post surgical dressings currently available.

118

PRESENTER: Margaret A. Collins, MD

TITLE: Localized Phaeohyphomycosis Caused by *Exophiala* Treated with Mohs Micrographic Surgery

AUTHORS: Margaret A. Collins, MD; Juliet L. Gunkel, MD; Molly Hinshaw, MD

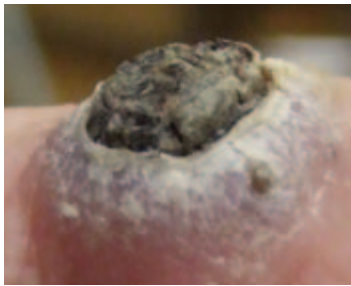


Fig 1: Clinical presentation resembling keratoacanthoma.

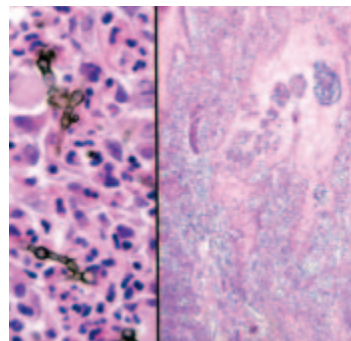


Fig 2: Pseudoepitheliomatous hyperplasia with pigmented spores and septate hyphae.

Purpose: We present a case of a renal transplant patient with a keratoacanthoma-like presentation of phaeohyphomycosis caused by *Exophiala* which failed to respond to systemic therapy and subsequently underwent Mohs micrographic surgery for definitive treatment of the lesion.

Design: The patient initially presented with a rapidly growing, tender, clinically exophytic, keratotic lesion on the medial aspect of the hand (Fig 1). The clinical differential diagnosis included squamous cell carcinoma, specifically keratoacanthoma. Biopsy revealed pseudoepitheliomatous hyperplasia with a suppurative and granulomatous infiltrate as well as pigmented spores and septate hyphae (Fig 2).

Phaeohyphomycosis is a rare opportunistic infection caused by dematiaceous fungi which include *Exophiala*, *Alternaria*,

and *Phialophora* species. Infection may manifest as primary cutaneous lesions, typically cystic, and rarely as systemic infection with secondary cutaneous involvement particularly in the immunocompromised, although evaluation for systemic involvement was negative in our patient. Tissue culture revealed *Exophiala* which was sensitive to posaconazole and itraconazole. The patient was started on oral posaconazole 400mg twice daily by another provider, but after over three months of continuous treatment, there was no improvement in the lesion; in fact, the lesion expanded in size. Surgical intervention was considered. A review of the literature found a report by Bogle et al. (Ref. 1), and the decision was made to proceed with Mohs surgery with the goal of clearing the infection. At the time of surgery, a biopsy was obtained that again revealed pigmented hyphae consistent with *Exophiala* thus proving persistent infection despite 3 months of antifungal therapy. The surgery was completed in two stages, and final permanent processing of the tissue confirmed clearance of the fungus. The wound was allowed to heal by secondary intention, and the patient continues to do well without evidence of recurrence at one month post procedure.

Conclusions: This case not only displays an atypical presentation of an unusual infection in a transplant patient, it also illustrates the critical role of surgical intervention in cases of phaeohyphomycosis.

(Ref. 1. Bogle MA, Rabkin MS, Joseph AK. Mohs micrographic surgery for the eradication of phaeohyphomycosis of the hand. *Dermatol Surg* 2004 Feb;30(2 Pt 1):231-3.)

119

PRESENTER: Monika Srivastava, MD

TITLE: The Management of Parotid Fistulas after Mohs Surgery

AUTHORS: Monika Srivastava, MD; Divya Srivastava, MD; Gangaram Ragi, MD

Purpose: Parotid fistulas are a rare complication following routine Mohs surgery. We report two cases of parotid fistulas which developed 2-4 weeks postoperatively following Mohs surgery for basal cell carcinomas. These case reports highlight several important pearls: 1) Aggressive basal cell carcinomas can involve the parotid gland. 2) It is necessary to understand the normal anatomy of the parotid gland, as well as recognize aberrant parotid tissue in atypical locations. 3) The development of small parotid fistulas after Mohs surgery for basal cell carcinomas involving the parotid gland can complicate postoperative courses. 4) These small parotid fistulas can be noninvasively managed and treated with daily pressure dressings for 2-3 weeks.

Design: Parotid fistulas are a rare complication following routine Mohs surgery. We report two cases of parotid fistulas which developed 2-4 weeks postoperatively following Mohs surgery for basal cell carcinomas. The first case occurred in a

Poster Presentation Summaries

74 year old man who presented with a basal cell carcinoma in the right postauricular area. Mohs surgery was completed in 4 stages. The deep margins revealed aberrant parotid gland tissue. The defect was repaired with an advancement flap. Approximately 3 weeks after surgery the patient complained of saliva draining from the wound. Examination revealed a 2 mm fistula. The patient was treated with daily pressure dressings for 3 weeks. At follow-up, the fistula had closed and the patient had no further complications. The second case occurred in an 80 year old woman with a basal cell carcinoma involving the right preauricular area. Mohs surgery was completed in 2 stages. The deep margins involved the parotid gland. The defect was repaired with an A-T advancement flap. Sutures were removed 2 weeks after surgery without complication. Approximately 4 weeks after surgery, the patient complained of saliva draining from the surgery site. On exam, there was a 1 mm fistula. Saliva was produced with gentle compression. The patient was treated with daily pressure dressings for 2 weeks. At follow-up, the fistula had healed with no further complications.

Conclusions: In conclusion, parotid fistulas can complicate the postoperative course of Mohs surgery for basal cell carcinomas involving the parotid gland. These small fistulas can be managed with daily pressure dressings for 2-3 weeks.

120

PRESENTER: Erica Lee, MD

TITLE: The First Report of Transient Peroneal Nerve Palsy in Dermatologic Surgery

AUTHORS: Erica Lee, MD; Robin Ashinoff, MD; Vicki J. Levine, MD

Purpose: Dermatologic surgeons commonly perform procedures on the lower extremity with minimal adverse effects. We present two cases of transient peroneal nerve paresis, a rare but potentially serious complication after dermatologic surgery.

Design: Case #1 is a healthy 55 year old male referred to Mohs surgery for a nodular basal cell carcinoma on the left calf, several centimeters below the popliteal fossa. After infiltrative anesthesia with 4ml of 1% lidocaine and epinephrine (1:200,000), one stage of Mohs surgery and a layered closure were performed. Shortly thereafter, the patient stated his entire left leg was paralyzed. Clinical exam showed loss of sensation from the left knee to dorsal foot and a left foot drop. After 5 hours, full function and sensation returned.

Case #2 is a 51 year old healthy female referred for removal of a severely dysplastic nevus on the lateral right leg. The lesion was anesthetized with 6ml of 1% lidocaine and epinephrine (1:200,000), excised to the mid subcutaneous fat and closed in layers. The patient was able to ambulate a short distance to a chair, however when attempting to put

on pants while wearing shoes, she fell to the floor. On exam, decreased sensation from the right lateral knee to dorsal foot and incomplete foot eversion were appreciated. This resolved following 7 hours.

Summary: The common peroneal nerve courses close to the skin surface on the outer, lower portion of the knee to supply the tibialis anterior, foot everter muscles and the extensors of the toes. It also provides sensation to the skin over the anterolateral aspect of the lower leg and the dorsal foot. Infiltration of local anesthesia in the vicinity of the peroneal nerve and its branches, notably the superficial peroneal nerve can in rare instances, lead to temporary peroneal nerve paralysis manifesting as a foot drop, anesthesia or decreased foot eversion. While this is an uncommon adverse effect of local anesthetics, when it occurs, is alarming to the patient and surgeon.

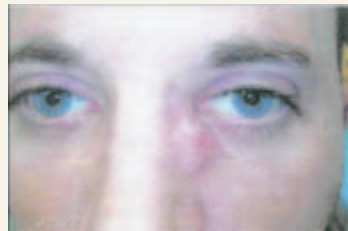Conclusions: To our knowledge, transient peroneal nerve palsy after cutaneous surgery has not been reported. Dermatologic surgeons should be aware of this phenomenon to appropriately inform, assess and manage patients.

121

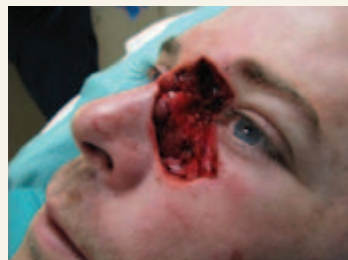PRESENTER: Parrish Sadeghi, MD

TITLE: Trichoblastic Carcinoma: Case Report of a Rare Entity

AUTHORS: Parrish Sadeghi, MD; Allison T. Vidimos, MD; Michael Fritz, MD



Original lesion.



Defect after Mohs micrographic surgery.

Purpose: Trichoblastic carcinoma is a rare malignant adnexal tumor, capable of metastasis. To our knowledge, only 9 cases have been reported in the literature.

Design: This is a case of a 32 year-old Caucasian man with a 6 year history of an enlarging asymptomatic pink nodule on the left nasal sidewall. An incisional biopsy was consistent with a trichoblastic carcinoma.

Work up included a CT scan showing a soft tissue mass measuring 7x16x18 mm on the left side of the nose, involving the pre-septal region of the medial left orbit without extension to the orbital

septum. PET scan was negative for metastatic disease.

Poster Presentation Summaries

Mohs micrographic surgery was performed and negative margins were achieved after 6 stages. Reconstruction was performed with excellent cosmesis.

Conclusions: Trichoblastic carcinoma is a malignant epithelial adnexal neoplasm arising from the external root sheath of the hair follicles. It is a rare entity; however, misdiagnosis and inadequate treatment can lead to metastasis. To our knowledge, only 9 cases have been reported in the literature. Of these, three involved the lip, one on the nose and ear, and the rest on the trunk and extremities. In two of the cases (trunk and upper extremity), the patients expired secondary to metastasis.

Microscopically, many irregularly shaped confluent plump cell nests, often in a ribbon-like or cribriform arrangement are visualized. Mid-size to large pleomorphic epithelial cells, often with atypical mitoses, are present. The stroma is often cell poor and sclerotic. Necrosis, calcification and bone formation may be seen.

Treatment includes adequate surgical removal by Mohs surgery or wide excision. Role of radiation therapy has not been established. Metastatic work-up and close post-operative follow-up is essential.

122

PRESENTER: Murad Alam, MD

TITLE: Treatment of Primary Mucinous Carcinoma of the Skin: Meta-Analysis of 189 Cases

AUTHORS: Murad Alam, MD; Renata Trela; Natalie Kim; Simon S. Yoo, MD; Alfred Rademaker

Purpose: Primary mucinous carcinoma is an uncommon sweat gland tumor with varied clinical presentation. While generally considered an indolent lesion, the prognosis after treatment is poorly understood. The purpose of this study was to estimate the likelihood of recurrence and metastasis after treatment of primary mucinous carcinoma by various methods. A secondary objective was to provide demographic data regarding incident cases.

Design: Meta-analysis of case reports and case series from MEDline, 1950-2008. Uniform fields, including demographic information (patient age, sex, race), tumor characteristics (anatomic location, apparent clinical surface area), and treatment-specific variables (months prior to treatment when lesion was first noticed, treatment type, duration of post-treatment follow-up, recurrence, metastasis) were extracted from published reports. Means and variation of descriptive variables were recorded. Association of demographic and tumor characteristics with likelihood of recurrence and metastasis was assessed.

Summary: Average patient (mean) was 64 years old, female (51.6%) and white (53.2%; 22.1% black, 23.4% Asian). Lesions were first noticed 37.2 months (mean) before presentation for treatment, and occurred most frequently on the eyelid/eyebrow (44.4%), and also often on the scalp (21.2%), and face/ear/neck (20.1%). Most lesions were treated by excision (94%), with a minority by Mohs (5%), or other methods (1%: eye exenteration, radiation, chemotherapy, liquid nitrogen). Mean size prior to treatment was 5.1 sq. cm., and after treatment was 9.8 sq. cm. (medians, 1.6, and 4.7, respectively). Mean follow-up after treatment was 39.6 months, during which time 19.6% of lesions recurred, and 5.8% metastasized. At the end of follow-up, 80.3% of patients were alive without disease, 1.5% were alive with disease, 2.9% were dead of disease, and 15.3% were dead of other causes. Anatomic site was associated with risk of metastasis ($p=0.002$), with 40% of axillary lesions, 18% of trunk and extremity lesions, and fewer than 5% of lesions at all other locations developing metastases. The association between treatment type and risk of recurrence approached significance ($p=0.06$) with recurrence after Mohs or excision (3.4%) being nominally much less than recurrence after non-surgical modalities (33%). Similarly, the association between lesion size and risk of metastasis was near-significant ($p=0.08$), with lesions that did not metastasize having a mean surface area of 3.88 sq. cm, and lesions that did of 18.87 sq. cm.

Conclusions: Primary mucinous carcinoma is amenable to surgical resection, which provides a good outcome, with approximately 20% risk of recurrence and 5% risk of metastasis during 3 years of follow-up. Axillary tumors account for a small proportion (5.3%) but are much more liable (40%) to metastasize than tumors at other locations. Most lesions are relatively small, but the distribution is skewed, with some very large lesions that are associated with higher risk of metastasis. Non-surgical therapy for primary mucinous carcinoma is rarely undertaken and is contraindicated given the poor response.

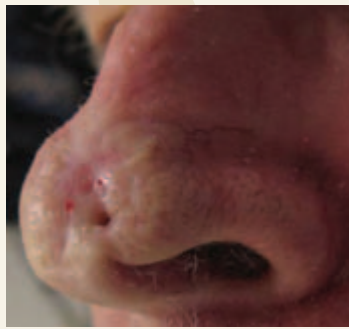Poster Presentation Summaries

123

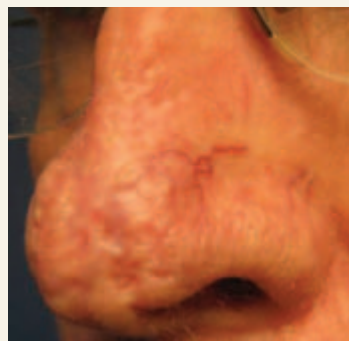PRESENTER: Dori Goldberg, MD

TITLE: Sandwich Graft in the Repair of a Small Through and Through Defect on the Nose

AUTHORS: Dori Goldberg, MD; Gary Fudem; Jeremy S. Bordeaux, MD, MPH; Mary E. Maloney, MD



Through and through defect of the nasal tip.



Healed defect 1 month following sandwich graft.

Purpose: We describe the case of a 76 year-old man with a persistent 1 mm through and through defect of the nasal tip resulting after Mohs surgery that was successfully repaired with a sandwich graft from the scaphoid fossa of the ear. There is one report of using a sandwich graft from the earlobe for repair of a full-thickness defect of the nose in the plastic surgery literature; however, this has not been reported in the dermatologic literature to our knowledge.

Design: A 76 year-old man presented to the Mohs surgery clinic with a nodular and infiltrative basal cell carcinoma on the nasal tip. The lesion was cleared in three stages resulting in a 2.1 x 1.9 cm wound that was repaired with an island pedicle flap. At one week follow-up, the patient

had superficial epidermal necrosis of the flap. The area was debrided and the wound gradually granulated in. At 5 week follow-up the wound was healing well but there was now a 1 mm through and through defect at the inferior margin. The wound edges were freshened and the edges re-sutured with 5-0 prolene cutaneous suture. At 2 week follow-up the defect persisted. Despite subcutaneous hinge flap repair on 2 separate occasions, the through and through defect remained. The wound was successfully repaired eleven months after his Mohs surgery using a 3-layer composite graft from the left ear (skin-cartilage-skin) harvested using a 4 mm punch biopsy. The donor site was closed primarily. A 4 mm punch biopsy was used to freshen the edges of the re-epithelialized defect on the nasal tip. The sandwich graft was then sutured in place at the epidermal and mucosal aspects using 4-0 chromic suture in an interrupted fashion.

Summary: The defect has not recurred after 5 months of follow-up.

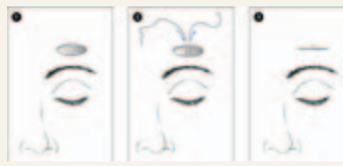Conclusions: A 3-layer sandwich graft can easily be harvested from the ear and provides an effective option for repair of small, persistent through and through defects on the nasal tip.

124

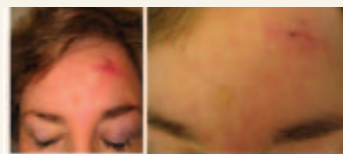PRESENTER: Antonio P. Cruz, MD

TITLE: Surgical Pearl: Percutaneous Suspension Suture

AUTHORS: Antonio P. Cruz, MD; Ross Campbell, MD; Raymond G. Dufresne, Jr., MD



The percutaneous suspensions suture.



1. Note the dimpling created immediately upon placement of the percutaneous suture.

2. After 1-2 weeks at suture removal, the dimpling has faded.

Purpose: The suspension suture can be beneficial in a primary linear closure by fixing the closure line at the junction of cosmetic units, and preventing distortion of free margins this technique of utilizing a buried suture can be limited by access from underlying subcutaneous structures of the advancing tissue and security of the suture placement.

Design: Materials: One tissue hook, one pair of undermining scissors, absorbable 3.0 or 4.0 polyglactic suture material, and one needle driver.

Summary: We describe a technique of placing the first segment or advancing arm of the suture in a percutaneous manner thus allowing added support, distant position and less risk of tissue tearing for this tension-bearing suture.

Conclusions: The percutaneous technique gives greater support to the classic suspension suture, relieves tension on the repair preventing tissue ischemia, and decreases spreading of the scar. Over time, patients heal well with no dimpling effect. This is a simple, highly effective technique to allow primary linear closures, fix defects at the junction of cosmetic units, and prevent distortion of facial features.

Poster Presentation Summaries

125

PRESENTER: Deborah J. Yang, MD

TITLE: Closure Pearls for Defects Under Tension

AUTHORS: Deborah J. Yang, MD; Ida F. Orengo, MD

Purpose: There are often defects that can be closed but are under tension. We present three clinical pearls to aid in closure of such defects.

Design: We present the following clinical pearls to aid in closing defects under high tension: the far-near-near-far pulley suture, the tension-dispersed horizontal mattress suture, and the tug-of-war technique.

Summary: 1. Placing several far-near-near-far pulley sutures in a defect under tension allows placement of buried dermal sutures to appose the defect margins. After the defect is closed the pulley sutures can be left in place or removed depending on skin tension observed after placement of remaining sutures.

2. The tension-dispersed horizontal mattress suture is a modification of the horizontal mattress suture with the free end of the suture placed within the horizontal suture on the opposite side to help displace the tension.

3. Placement of the first buried dermal suture within a site of tension often leads to difficulty in apposition without breaking the suture. If one applies a tug-of-war type technique in which the suture ends in each hand are alternately pulled, suture breakage is minimized.

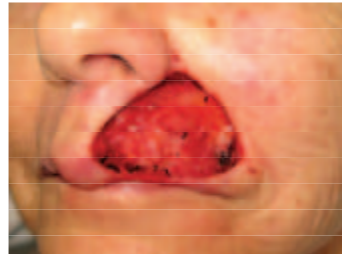Conclusions: These three clinical pearls provide ideas for closure of defects under tension.

126

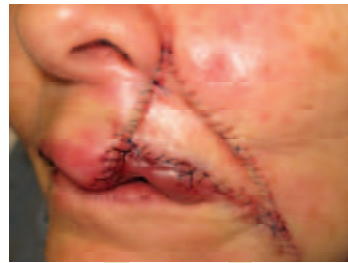PRESENTER: Theresa L. Ray, MD

TITLE: Closure of Large Surgical Defects on the Cutaneous Upper Lip Using an Island Pedicle Flap

AUTHORS: Theresa L. Ray, MD; Christine H. Weinberger, MD; Peter K. Lee, MD, PhD



Original Mohs surgical defect before reshaping.



Finished island pedicle flap on the day of surgery.

Purpose: Closure of large defects on the cutaneous upper lip is quite challenging. While small defects may be closed within the cosmetic subunit of the lip, large defects often require flaps that distort the melolabial fold or move glabrous skin into the defect. We report our experience using an island pedicle flap for closure of large defects on the cutaneous upper lip in 20 patients.

Design: All defects were the result of Mohs micrographic surgery. The defects were sometimes extended to the full height of the lip for closure along cosmetic boundaries. The primary defect was frequently reshaped to allow appropriate match to the

square shape of the flap. The island pedicle flap was harvested from the mandible in the area of the marionette lines, extending past the jaw line if necessary. This provided a well vascularized flap consisting of hair-bearing skin similar to that of the cutaneous upper lip. Because island pedicle flaps are advancement flaps, the direction of hair growth was preserved. The area around the secondary defect was extensively undermined in the plane of the deep subcutaneous fat to give the flap appropriate mobility.

Summary: All 20 patients had successful reconstruction with good cosmetic results. We experienced no cases of trapdoor deformity and no flaps required secondary debulking procedures. Complications experienced include paresthesias and one case of minimal alopecia at the flap's leading edge. If transected, the orbicularis oris muscle was repaired prior to closure; therefore, we experienced very little asymmetry of facial movement or smile.

Conclusions: In our experience, the island pedicle flap is an excellent option for closure of large defects on the cutaneous upper lip. Enough tissue can be mobilized to cover large defects using similar, hair-bearing skin. Undermining in the deep subcutaneous fat allows good flap mobility while maintaining the flap's blood supply and follicular units.

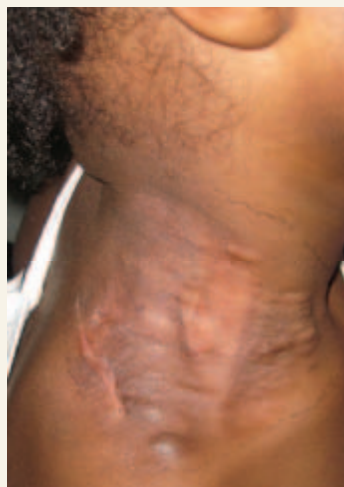Poster Presentation Summaries

127

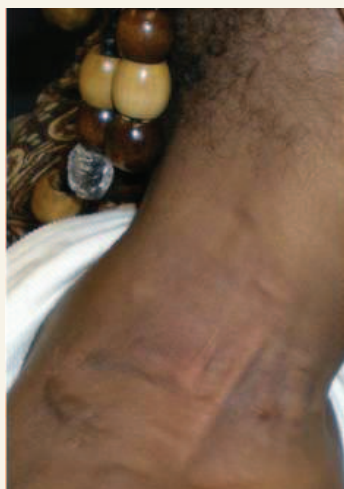PRESENTER: Christina Wahlgren, MD

TITLE: The Use of Imatinib Mesylate as an Adjuvant Therapy to Mohs Surgery in a Child with Dermatofibrosarcoma Protuberans

AUTHORS: Christina Wahlgren, MD; Peter Shaw; Shao Jiang; Doug Kress; Robin Gehris; Drazen Jukic; Hakeem Sam, MD, PhD



DFSP prior to treatment with imatinib mesylate.



DFSP after 3 months of imatinib mesylate therapy.

Purpose: The purpose of this case report is to describe successful treatment of a child with a pigmented dermatofibrosarcoma protuberans (DFSP) with imatinib mesylate. To our knowledge, this is only the second report of a child treated with imatinib mesylate for a DFSP in the literature to date.

Design: DFSP is a rare soft tissue tumor that infrequently metastasizes, but has a high rate of local recurrence due to infiltration of the subcutaneous tissue. As a result, excision via Mohs micrographic surgery has become the standard of care. Treatment of DFSPs in the pediatric population has not been well studied and guidelines are based upon studies in the adult population. DFSPs are characterized by chromosomal abnormalities involving the platelet derived growth factor beta chain locus (PDGFB). Imatinib mesylate is a tyrosine kinase inhibitor with activity against the PDGFB receptor and has been reported to be effective in treating adult patients and one child with DFSP.

Herein we describe a three year-old African American female with a pigmented DFSP measuring 9 cm by 9 cm on the right shoulder. Given the extent of the tumor, its proximity to the spinal accessory nerve and the possibility of a poor functional or cosmetic outcome, Mohs micrographic surgery was not

considered the optimal first-line therapy. She was consequently treated with imatinib mesylate in an attempt to make the tumor more amenable to resection. After 3 months of daily oral imatinib mesylate at a dose of 13mg/kg, we noted a dramatic clinical response with a significant reduction in the tumor size. The patient's only toxicity was intermittent leg pain managed with acetaminophen.

Conclusions: Treatment of DFSPs in the pediatric population is challenging. Surgical excision of the lesion is the gold standard; however, this is not always feasible as in the case presented here. Our case report in conjunction with the current body of published evidence suggests that imatinib mesylate should be considered as an adjuvant therapy to those children with DFSPs who are not good candidates for Mohs micrographic surgery at diagnosis. Ideally a prospective clinical trial could test the efficacy of this therapy but is hindered by the rarity of this tumor in the pediatric population.

128

PRESENTER: Jeremy S. Bordeaux, MD, MPH

TITLE: Defining Prognosis for Transected Melanomas

AUTHORS: Jeremy S. Bordeaux, MD, MPH; Kathryn J. Martires; Ashok Panneerselvam

Purpose: The prognosis and therapy of melanoma is directly related to depth of cutaneous invasion at initial removal. This is referred to as "Breslow's depth" and is measured in millimeters (mm). When melanomas are transected at diagnosis, true Breslow's depth is difficult to ascertain. If residual melanoma is present on re-excision, the Breslow's depth of the residual tumor is added to that of the original transected tumor. If no residual melanoma is present on re-excision, only the depth of the transected tumor (original Breslow's depth) is available to guide prognosis and therapy. The purpose of this study is to determine the frequency of melanoma transection at diagnosis, to describe risk factors associated with poorer survival, and to compare survival rates of patients with transected melanomas that have no additional tumor on re-excision with that of melanomas of the same Breslow's depth that are not transected.

Design: This is a cohort study of patients diagnosed with melanoma at the University Medical Center between 1996 and 2007 who had corresponding survival data available from the University Medical Center Tumor Registry. The study was conducted at an academic medical center with a multidisciplinary melanoma clinic that draws patients from the academic setting and the surrounding community. A total of 625 patients were included for analysis. The study examined the number of transected melanomas, the proportion of transected melanomas without residual tumor, risk factors for poor survival, and relative survival rates of transected tumors found to have no residual tumor compared with non-transected tumors of similar Breslow's depth.

Poster Presentation Summaries

Summary: The study found that 178 of 625 (28.5%) melanomas were transected at diagnosis. Of the transected melanomas, 59.0% revealed no residual tumor on re-excision. In the multivariate analysis, advanced age ($p=0.0011$), higher Breslow's thickness ($p=0.0032$), and presence of ulceration ($p=0.0112$) each independently predicted poorer survival, while male sex (0.0981) and positive sentinel node (SN) status (0.0666) trended toward poorer survival. Univariate analysis demonstrated that patients with transected melanomas with no residual tumor had poorer survival than patients with no transection ($p=0.0479$). The multivariate analysis trended toward this result as well ($p=0.0887$).

Conclusions: A high number of melanomas are transected at diagnosis, making appropriate staging and therapy difficult. In agreement with other studies in the literature, factors found to predict poorer survival include advanced age, thicker Breslow's thickness, presence of ulceration, male sex, and positive SN status. Patients with transected melanomas with no residual tumor on re-excision may have poorer survival, and as a result, more aggressive diagnostic and therapeutic procedures may be appropriate for them.

129

PRESENTER: William Lear, MD

TITLE: A Comparison of Four Mohs Tissue Processing Methods Using Porcine Skin

AUTHORS: William Lear, MD; Daniel Berg, MD; Norma Andersen

Purpose: To evaluate, in a randomized and standardized manner, the time and depth into the block required to get a complete en face section of epidermis, dermis and fat for the following four Mohs tissue processing methods: cryoEMBEDDER®, slide, float and heat sink methods. We also evaluated, for each method, a one-piece versus two-piece approach to processing standardized samples of tissue.

Design: We used pig bellies as the source of tissue to give us a large surface with relatively uniform physical properties. We coordinated our study with other University researchers who were using pigs to study spinal anesthesia. The fresh pig bellies were excised as one large specimen and kept on ice during our experiment. Circular samples of 1.0 cm diameter and a depth to the fat were excised from the pig belly in a standard Mohs fashion (i.e. beveled) and randomly allocated to one of the four methods and to either one- or two-piece approach to processing. Three samples were processed for each method and approach, thus having us excises a total of 24 circular discs of 1.0 cm diameter. One-piece samples were processed whole, while two-piece samples were divided along the diameter of the circular disc and processed as two separate pieces.

The time required to get the initial section of tissue was measured from the time the inked specimen was given to the technician until the first section of tissue was obtained from the block. Sections were then obtained every 60 microns into the block. These sections were processed and stained using H&E. The sections were examined microscopically to determine the lowest depth into the block at which a complete section of epidermis, dermis and fat was present.

Summary: For all methods, the one-piece approach to process the specimen usually required more depth into the block to get a complete section and more time to get the initial section. (Fig. 1 and 2).

The slide and cryoEMBEDDER® methods required the least amount of depth into the block to get a complete section (Fig. 1). In addition to required more depth to get a complete section, the heat sink and float methods also suffered from a high variability in depth required. This tendency could be inopportune for very thin specimens.

The slide and cryoEMBEDDER® methods required more time to get complete sections. For one-piece processing, the time required to get the initial section for the slide method was 698 +/- 64 seconds versus 364 +/- 312 seconds for the heat sink method (Fig. 2), which would amount to over five minutes less time required using the heat sink method. The heat sink and float methods did not have significant differences in processing times. There was a trend to the cryoEMBEDDER® being slightly faster than the slide method for one-piece samples.

Conclusions: Each method and approach has its own set of unique advantages and disadvantages, as outlined in Fig. 1 and 2. We did not evaluate the fidelity (i.e. ability to detect tumor) of the methods/approaches in our study.

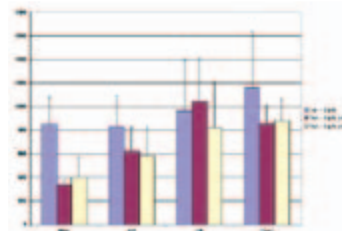


Fig. 1 Depth in microns required to cut into block to get complete section.

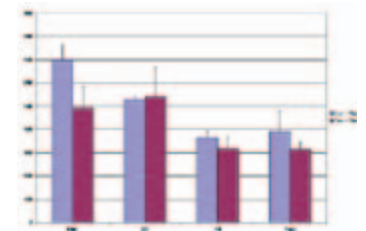


Fig. 2 Processing time in seconds required to get initial section.

Poster Presentation Summaries

130

PRESENTER: Aleksandar L.J. Kronic, MD, PhD
TITLE: Refractory Aggressive Keratoacanthoma Centrifugum Marginatum of the Scalp Controlled with Epidermal Growth Factor Receptor Inhibitor Erlotinib
AUTHORS: Aleksandar L.J. Kronic, MD, PhD; John Villano; Aaron Cetner, MD; Tanya K. Bulj

Purpose: To evaluate the efficacy of Epidermal Growth Factor Receptor inhibitor (EGFRi) erlotinib (Tarceva) in the treatment of recalcitrant, aggressive Keratoacanthoma Centrifugum Marginatum (KCM) of the scalp.

Design: A case presentation.

Summary: This is a 74 year old Caucasian female with a five year history of refractory KCM. Prior to presentation in 2006 she had undergone unsuccessful surgical excision, Mohs surgery, chemotherapy, radiation, systemic retinoids, and full-thickness debridement of the scalp and bilateral helices. Despite aggressive surgical therapy new nodules continued to develop at the edges of the scalp contributing to further destruction of the skin and subjacent structures. She received a 6 month course of oral methotrexate (15mg weekly) which led to partial plaque resolution until systemic methotrexate was stopped due to concerns about toxicity. Intralesional methotrexate failed to produce significant control of the new appearing tumors. Even with her extensive skin involvement, on multiple occasions she failed to demonstrate metastatic disease on positron emission tomography, computed tomography or magnetic resonance imaging. Keratoacanthomas are squamous cell neoplasms known to be abundant in EGF receptors. Special stains of typical crater-like neoplastic architecture of her lesions confirmed diffuse presence of EGF receptors in the tumor. The patient was placed on oral erlotinib 150 mg daily. This therapy produced efficient control of the development of the new lesions and almost complete regression of the pre-existing ones after 2 months. Upon initiation of therapy patient experienced typical EGFRi-associated papulopustular rash on the trunk and upper extremities which resolved in the due course.

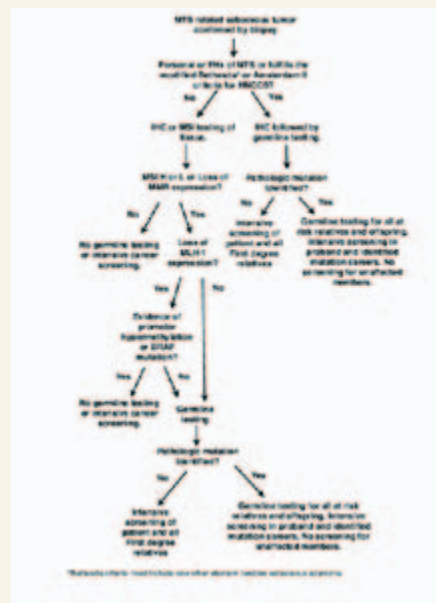Conclusions: EGF regulates growth and development of several cell lines including keratinocytes. EGFRi are tyrosine kinase inhibitors which were shown to control the growth of different internal neoplasms, including metastatic squamous cell carcinoma of the skin. The expansion of the use of EGFRi to control other very well differentiated EGF dependent squamous neoplasms of the skin may open a new field for therapy in cutaneous oncology especially when dealing with recalcitrant, multiple or surgically non-resectable lesions.

131

PRESENTER: Daniel Michael, MD, PhD
TITLE: Algorithm for Approaching a Patient with a Newly Diagnosed Sebaceous Neoplasm
AUTHORS: Daniel Michael, MD, PhD; Daniel B. Eisen, MD

Purpose: To provide a comprehensive algorithm to identify patients with sebaceous neoplasms who will benefit from germline testing and intensive cancer screening.

Design: A literature search was conducted using keywords including: Muir-torre, Lynch syndrome, immunohistochemistry, microsatellite, and sebaceous. Previous algorithms for patients with Muir-Torre and Lynch syndrome were identified and their short comings assessed. Few comprehensive algorithms were identified in the literature regarding Muir-Torre syndrome, so a new algorithm was created using information primarily regarding Lynch syndrome.



Summary: Muir-Torre syndrome (MTS) is an autosomal dominant phenotypic subset of hereditary nonpolyposis colorectal cancer syndrome (Lynch syndrome). It is manifested by the development of sebaceous neoplasms or keratoacanthomas in conjunction with visceral malignancies, most often colorectal carcinoma.

Sebaceous neoplasms are rare, but many dermatologic surgeons will encounter them. Up to 42% of these lesions are associated with MTS. Who and how to screen patients for MTS has been a source of confusion. We provide an algorithm that should simplify the approach to these complex lesions.

Conclusions: Intensive cancer screening of patients at risk for this syndrome has been found to decrease mortality in patients with Lynch syndrome. Early identification of these patients and screening of their first degree relatives can improve outcomes.

Exhibitor Floor Plan

FOOD & BEVERAGE

117 - CryoEmbedder, Inc.	116 - MTI Medical Technology Industries	216 - Elsevier (Saunders/ Mosby)	217 - O'Dell Jarvis Mandell, LLC
115 - Fallene, Ltd.			
113 - Nikon Instruments, Inc.	112 - Mohs Histology Consulting Services	212 - ACMS	215 - Microsurgery Instruments, Inc.
111 - NextGen Healthcare Information Systems, Inc.	110 - Ellis Instruments, Inc.	210 - Celerus Diagnostics	211 - derm.md
109 - ProPath			209 - Leica Microsystems
107 - Midmark Corporation	108 - Wiley-Blackwell	208 - EltaMD Skincare	207 - Mohs Technical Consulting
105 - Travel Tech Mohs Services, Inc.	106 - American Academy of Dermatology	206 - VersaSuite	205 - MedNet Technologies, Inc.
103 - Expeditor Systems, Inc.	102 - Tiemann Surgical		203 - DUSA Pharmaceuticals, Inc.
101 - Global Pathology Laboratory Services			201 - Designs For Vision, Inc.

ENTRANCE

Exhibit Hall hours are:

Thursday, April 23 12:00 – 6:30 pm
 Friday, April 24 12:00 – 6:00 pm
 Saturday, April 25 8:30 am – 2:00 pm

Exhibitor Listing

American Academy of Dermatology 106

930 East Woodfield Road
Schaumburg, IL 60173
Phone: (866) 503-7546
Fax: (847) 240-1859
Email: mrc@aad.org
Website: www.aad.org

The AAD offers a wide variety of professional and public education products for dermatologists. Browse our latest Continuing Medical Education resources, Practice Management publications, and patient education pamphlets. Stop by our booth to view all of our products and ask how the AAD can lower your practice expenses!

Austin Convention and Visitors Bureau Austin Grand Ballroom Lobby

301 Congress Avenue, Ste. 200
Austin, TX 78701
Phone: (800) 926-ACVB [2282]
Email: JFoster@austintexas.org
Website: www.austintexas.org

Visit the Austin Convention and Visitors Bureau (ACVB) to find out all about Austin's sights and sounds!

American College of Mohs Surgery (ACMS) 212

555 East Wells Street, Suite 1100
Milwaukee, WI 53202
Phone: (414) 347-1103; (800) 500-7224
Fax: (414) 276-2146
Email: info@mohscollege.org
Website: www.mohscollege.org

The American College of Mohs Surgery (ACMS) will be available during Exhibit Hall hours to answer questions and provide information regarding the Annual Meeting or general ACMS-related queries. Pick up an order form and view our selection of ACMS merchandise, from Fellow Plaques to ACMS travel mugs, there will be much to see!

Celerus Diagnostics 210

1005 Mark Avenue
Carpinteria, CA 93013
Phone: (805) 684-2009
Fax: (805) 684-2088
Email: info@celerusdiagnostics.com
Website: www.celerusdiagnostics.com

The Celerus Wave™ System provides Mohs micrographic surgeons with a rapid and reliable diagnostic method to aid in the interpretation of surgical margins for melanoma. By delivering high-quality immunohistochemistry (IHC) results in as few as 15 minutes, surgeons can make decisions on Mohs sections with speed and confidence.

CryoEmbedder, Inc. 117

3434 E. 7800 S., Ste. 131
Salt Lake City, UT 84121
Phone: (800) 447-0718
Fax: (801) 453-0187
Email: jackie@cryoembedder.com
Website: www.cryoembedder.com

The CryoEmbedder® System is a simple and extremely fast, embedding process for frozen sectioning. This unbreakable instrument has no disposable parts. It adapts to all makes of cryostats and provides an eye-level view while freezing specimens. It's efficient, fast, accurate, economical, indestructible, and it works. Learn more at www.cryoembedder.com.

derm.md 211

223 N. Route 21, Suite 4
Gurnee, IL 60031
Phone: (847) 999-5110
Fax: (707) 982-1044
Email: monique@derm.md
Website: www.derm.md

derm.md has provided innovative solutions to the dermatology community for over a decade. MARS is the leading professional software designed specifically for the needs of your Mohs practice. MARS provides user-friendly features that allow you to instantly generate op notes, letters, reports, and more!

Designs For Vision, Inc. 201

760 Koehler Avenue
Ronkonkoma, NY 11779
Phone: (800) 345-4009
Fax: (631) 585-3404
Email: info@designsforvision.com
Website: www.designsforvision.com

Just See It™ with Designs for Vision's lightweight custom-made Surgical Telescopes – now available with Nike® frames. These Telescopes improve visual acuity and reduce back and neck pain. See It Even Better™ with the L.E.D. Daylite™ or Twin Beam™ L.E.D. providing the brightest and safest un-tethered illumination.

Exhibitor Listing

- | | | | |
|---|------------|--|------------|
| DUSA Pharmaceuticals, Inc. | 203 | Expeditor Systems, Inc. | 103 |
| 25 Upton Drive
Wilmington, MA 01887
Phone: (978) 657-7500
Fax: (978) 909-1020
Email: customerservice@dusapharm.com
Website: www.dusapharma.com
<i>DUSA Pharmaceuticals, Inc. is an integrated, dermatology specialty pharmaceutical company focused primarily on the development and marketing of its Levulan® Photodynamic Therapy (PDT) technology platform. Levulan Kerastick® plus blue light illumination using the BLU-U® blue light photodynamic therapy illuminator is currently approved for the treatment of Grade I or II AKs of the face or scalp. DUSA also markets ClindaReach™ which targets patients with acne.</i> | | 4090 Nine McFarland Drive
Alpharetta, GA 30004
Phone: (800) 843-9651
Fax: (770) 644-5214
Email: expeditor1@expeditor.com
Website: www.expeditor.com
<i>Expeditor Systems, Inc. provides patient flow light systems used to increase productivity, maximize room utilization, reduce patient waiting time, and improve office communication.</i> | |
| Ellis Instruments, Inc. | 110 | Fallene, Ltd. | 115 |
| 21 Cook Avenue
Madison, NJ 07940
Phone: (973) 593-9222
Fax: (973) 593-9277
Email: cellis@nac.net
Website: www.ellisinstruments.com
<i>Complete line of surgical instrumentation for dermatologic, Mohs and hair restoration surgery.</i> | | 2555 Industry Lane
Norristown, PA 19403
Phone: (610) 630-6800
Fax: (610) 630-6202
Email: info@totalblock.com
Website: www.totalblock.com
<i>Fallene, Ltd. offers a comprehensive multi-product line providing full spectrum sun protection. Each product is specifically designed for the unique needs of individuals concerned with blocking the full light spectrum. Nano-particle technology utilizing titanium, zinc, and iron, creates a complete reflective barrier against harmful UVB/UVA radiation.</i> | |
| Elsevier (Saunders/Mosby) | 216 | Global Pathology Laboratory Services | 101 |
| 25607 Singing Rain
San Antonio, TX 78260
Phone: (210) 497-3198
Fax: (210) 497-3198
Email: g.dixon@elsevier.com
Website: www.gdixon.com
<i>Saunders, Mosby, Churchill Livingstone, Butterworth Heinemann and Hanley Belfus, a combined premier worldwide health science publishing company, now under the umbrella of Elsevier, Inc., proudly presents our latest titles. Come visit us at our booth and browse through our complete selection of publications including books, periodicals and software. Elsevier Inc., building insights, breaking boundaries.</i> | | 16250 NW 59th Ave., Ste. 201
Miami Lakes, FL 33014
Phone: (305) 825-4422
Fax: (786) 639-0712
Email: patty@globalpathlab.com
Website: www.globalpathlab.com
<i>Providing personal, precise Dermatopathology services by Board Certified Dermatopathologists. 24 hour turn around time to all physicians throughout the United States. Toll free: 866-825-4422.</i> | |
| EltaMD Skincare | 208 | Leica Microsystems | 209 |
| 2055 Luna Rd. #126
Carrollton, TX 75006
Phone: (800) 633-8872
Fax: (972) 385-7930
Email: info@eltamd.com
Website: www.eltamd.com
<i>EltaMD™ offers a variety of sunscreens, moisturizers, and post-procedure products. EltaMD™ applies the innovation of medical technology to change the way skin care products treat people. EltaMD™ products are formulated using proven science, backed up by clinical testing designed to accomplish three goals: prevent damage, heal problems, and maintain skin health.</i> | | 2345 Waukegan Road
Bannockburn, IL 60015
Phone: (800) 248-0123
Fax: (847) 405-0147
Email: info@leica-microsystems.com
Website: www.leica-microsystems.com
<i>Visit the Leica Microsystems booth to see the latest technology in cryosectioning for Mohs surgery. On display is the Leica CM1950 cryostat with exemplary safety standards, capable of fulfilling the needs of even the busiest dermatologic practice. Also on display will be the latest in pathology imaging for Mohs surgery.</i> | |

Exhibitor Listing

MedNet Technologies, Inc.

205

1975 Linden Blvd, Ste. 407
Elmont, NY 11003
Phone: (516) 285-2200
Fax: (516) 285-1685
Email: info@mednet-tech.com
Website: www.mednet-tech.com

MedNet Technologies, Inc. offers website development, management and visibility services for various medical specialties ranging from medical offices to teaching hospitals to medical societies. Developing and promoting your web presence on the Internet is our goal.

Microsurgery Instruments, Inc.

215

7211 Regency Square Blvd, Ste. 223
Houston, TX 77036
Phone: (713) 664-4707
Fax: (713) 664-8873
Email: microusa@microsurgeryusa.com
Website: www.microsurgeryusa.com

Microsurgery Instruments, Inc. is one of the leading suppliers of instruments and surgical loupes. Our new instruments include: titanium Super-Cut Scissors, Olsen-Hegar needle holders, Bishop-Harmon forceps, and microsurgery instruments. Our scissors are the sharpest scissors in the market, and our newly designed expanded wide-field loupes offer up to 130mm field of view.

Midmark Corporation

107

60 Vista Drive
Versailles, OH 45380
Phone: (800) 643-6275
Fax: (800) 526-8286
Email: info@midmark.com
Website: www.midmark.com

Midmark Corporation is a leading manufacturer of the most user-and patient-friendly examination and procedure equipment available. Headquartered in Versailles, Ohio, Midmark provides a full line of power and manual examination tables, sterilizers, casework, seating, lighting, ECG's and accessories for use in healthcare systems and facilities worldwide.

Mohs Histology Consulting Services

112

2507 S. Manito Boulevard
Spokane, WA 99203
Phone: (509) 954-7134
Fax: (509) 624-3926
Email: mickie25@netzero.net
Website: www.mohshistotemp.com

Mohs Histology Consulting Services provides comprehensive Mohs and Dermopath laboratory consulting, laboratory set-up and technician training services. We provide complete CLIA manuals, certified technician training and training manuals. We also provide emergency, maternity and vacation relief services. Our many years of experience and our integrity insure you of turn-key Mohs and Dermopath laboratory solutions. Please see our references and more details at: www.mohshistologyconsulting.com

Mohs Technical Consulting

207

894 Buck Falls Road
Highlands, NC 28741
Phone: (866) 235-2476
Fax: (828) 369-3174
Email: histobarb@msn.com
Website: www.mohstechnicalconsulting.com

Mohs Technical Consulting, training techs to be a cut above the rest. Available for extensive technical assistance with little or no experience. Training is done at your office for your staff to be proficient in cutting Mohs sections. Consulting services are available from lab layout, to full training of new techs with little or no experience. For improved turnaround time and or trouble shooting. Training includes laboratory regulations for CLIA/OSHA, and all documentation for your office to become CLIA compliant. We have a zero deficiency rating with CLIA inspections in all our labs. A complete procedure manual is designed specifically for your office.

MTI Medical Technology Industries

116

3655 West Ninigret Drive
Salt Lake City, UT 84104
Phone: (801) 887-5114
Fax: (801) 952-0548
Email: info@mti-inc.us
Website: www.mti-inc.us

MTI exhibits their premium line of surgery tables for routine treatments, and minor/major surgeries. All of the surgery tables and exam chairs are powered by the industry leading low-voltage technology DC motors. These new low-voltage competitive chairs are more reliable, powerful, quieter, and inherently safer than traditional high voltage competitive chairs and tables.

NextGen Healthcare Information Systems, Inc.

111

795 Horsham Road
Horsham, PA 19044
Phone: (215) 657-7010
Fax: (215) 385-7693
Email: sales@nextgen.com
Website: www.nextgen.com

NextGen Healthcare is a leading provider of practice management and electronic health records software for all medical specialties. Ideal for the solo practitioner or the multi-provider enterprise, our award-winning, CCHIT-certified, DOQ-IT approved solutions are proven to improve the quality of patient care and increase operational efficiencies while delivering a healthy return on investment.

Exhibitor Listing

- Nikon Instruments, Inc.** 113
1300 Walt Whitman Road
Melville, NY 11747
Phone: (631) 547-8500
Fax: (631) 547-8652
Email: microscopysales@nikon.net
Website: www.nikoninstruments.com
Nikon Instruments Inc., a global leader in the development of advanced optical technology for microscopy, will exhibit: Eclipse 55i, the ultimate in comfortable microscopy operation with an incredible view and new LED light source; Digital Sight Camera Systems and Coolscope II, two unique yet distinct stand-alone instruments for easily capturing, storing, and sharing digital images. Coolscope II, an economical all-in-one digital microscope, may be operated in-house or remotely. Both instruments offer image processing technology enabling true natural color representation and are network addressable through firmware for image sharing and consultation. Please visit Nikon at <http://www.nikoninstruments.com> or call 800-52-NIKON.
- O'Dell Jarvis Mandell, LLC** 217
901 South Mopac Expressway
Barton Oaks Plaza One, Suite 300
Austin, TX 78746
Phone: (512) 329-1951
Fax: (888) 527-8476
Email: jarvis@ojmgroup.com
Website: www.ojmgroup.com
O'Dell Jarvis Mandell focuses on advanced asset protection, tax management, and financial consulting for high-income and high-liability medical specialists. Our principals have delivered CME seminars to over 100 medical groups and our clients are in all 50 states. Please stop by our booth for a free copy of our book, 'For Doctors Only: How to Work Less & Build More', a \$75 value.
- ProPath** 109
8267 Elmbrook Drive
Suite 100
Dallas, TX 75247
Phone: (800) 258-1253
Fax: (214) 237-1731
Email: crc@propath.com
Website: www.propath.com
ProPath Dermatopathology, led by Terry L. Barrett, MD, is the premier team of dermatopathologists providing diagnostic expertise to physicians nationwide. We offer a broad range of services including in-house immunohistochemistry and immunofluorescence, and consultative review of difficult or unusual cases. Call 1.800.258.1253 or visit www.propath.com to find out more about ProPath.
- Tiemann Surgical** 102
25 Plant Avenue
Hauppauge, NY 11788-3804
Phone: (800) 843-6266
Fax: (800) 577-6050
Email: sales@georgetiemann.com
Website: www.georgetiemann.com
Manufacturers of quality surgical instruments since 1826. Specializing in instruments and accessories for Dermatology, Mohs, Liposuction, Dermabrasion and Hair Transplant Surgery.
- Travel Tech Mohs Services, Inc.** 105
2341 W. 205 Street, Ste. 112
Torrance, CA 90501
Phone: (888) 872-8832
Fax: (310) 328-0690
Email: deborah@gotmohs.com
Website: www.gotmohs.com
TRAVEL TECH Mohs Services, Inc. is a technician service specializing in Mohs micrographic surgery. Our team of technicians has been providing the highest quality Mohs frozen sectioning available for the past 15 years. We provide all the machinery as well as a skilled professional in Mohs histology.
- VersaSuite** 206
13401 Pond Springs Road
Austin, TX 78729
Phone: (512) 250-8774
Fax: (512) 249-8774
Email: sales@versasuite.com
Website: www.versasuite.com
VersaSuite is a CCHIT-certified enterprise strength software system designed to improve the efficiency and quality of patient care. VersaSuite accommodates any size organization and all medical disciplines. VersaSuite adapts to clinicians' workflow, rather than forcing the healthcare providers to change their medical practices. 800-903-8774/sales@versasuite.com.
- Wiley-Blackwell** 108
350 Main Street
Malden, MA 02148-5018
Phone: (781) 388-8255
Fax: (781) 388-8255
Email: tgoggin@wiley.com
Website: www.wiley-blackwell.com
Wiley publishes an enormous range of top quality consumer, professional, educational and research material. Wiley-Blackwell, the scientific, technical, medical and scholarly publishing business of John Wiley & Sons, is the leading society publisher and offers libraries peer-reviewed primary research and evidence based medicine across 1250 online journals, books, reference works and databases. For more information, visit www.wiley.com.

ASMH Program-at-a-Glance



ASMH

15th Annual Meeting Scientific Program

April 24 – 25, 2009

Thursday, April 23

7:00 am – 5:00 pm	Visit Mohs Slide Library (Room 602 – 6 th Floor)
2:00 – 5:00 pm	Exhibit Setup (Salon G – 6 th Floor)
2:00 – 5:00 pm	Meeting Registration (Austin Grand Ballroom Lobby – 6 th Floor)
5:00 – 7:30 pm	Board of Directors' Meeting (Room 408 – 4 th Floor)

Friday, April 24

7:00 am – 5:00 pm	Visit Mohs Slide Library (Room 602 – 6 th Floor)
7:30 – 8:30 am	Continental Breakfast in ASMH Exhibit Area (Salon G – 6 th Floor)
7:30 am – 4:30 pm	Meeting Registration/Information (Austin Grand Ballroom Lobby – 6 th Floor)
7:30 am – 6:00 pm	Visit ASMH Exhibits (Salon G – 6 th Floor)
8:30 – 10:00 am	General Session 1 (Salon F – 6 th Floor)
8:30 am	Opening Remarks/Welcoming - Barbara Beck, HT (ASCP), ASMH President
8:45 am	The Anatomy of the Face – Paul Bowman, MD
9:30 am	2009 Abstract Award Winner – Trishina Clark, "Can Flash Freezing of Mohs Layers Expedite Slide Turn Around Time and Minimize Sample Distortion (Freezing Artifact)?"
9:45 am	Break – ASMH Exhibit Area (Salon G – 6 th Floor)
10:00 am – 2:15 pm	Informal Training for Mohs Fellows and Surgeons in Exhibit Hall (Salon G – 6 th Floor)
10:00 – 11:45 am	General Session 2 (Salon F – 6 th Floor)
10:00 am	The Background of the Chemistry and Technique of Staining – Mickie Johnson
11:00 am	A "Typical" Day in the Mohs Lab – Deborah DeMarko, Sara Haun, Gina Marie Ackley, HT (ASCP)
11:45 am – 1:00 pm	Lunch on Your Own
1:00 – 2:30 pm	General Session 3 (Salon F – 6 th Floor)
1:00 pm	Dealing with Repetitive Motion Injuries – Barbara Beck, HT (ASCP)
1:30 pm	ASMH Membership Meeting
2:00 pm	Non-melanoma Skin Cancer: A Review of Treatment Options and the Benefits of the Mohs Procedure – Kurt Mueller, MD
2:30 – 4:30 pm	Workshops <ul style="list-style-type: none"> • Beginner's Cryostat Workshop (Salon G – 6th Floor) • Intermediate Cryostat Workshop (Salon G – 6th Floor) • Slide Troubleshooting Workshop (Room 408 – 4th Floor) • MART 1 Immuno Staining Workshop (Room 410 – 4th Floor)
4:30 – 6:00 pm	Networking Reception in ASMH Exhibit Hall (Salon G – 6 th Floor)
6:00 pm	Dinner on Your Own

ASMH Program-at-a-Glance



ASMH

15th Annual Meeting Scientific Program

April 24 – 25, 2009

Saturday, April 25

7:00 am – 2:00 pm	Visit Mohs Slide Library (Room 602 – 6 th Floor)
8:00 am – 4:00 pm	Meeting Registration/Information (Austin Grand Ballroom Lobby – 6 th Floor)
8:30 am – 4:00 pm	Visit ASMH Exhibits (Salon G – 6 th Floor)
8:30 – 9:00 am	Continental Breakfast in ASMH Exhibit Area (Salon G – 6 th Floor)
9:00 – 10:30 am	General Session 4 (Salon F – 6 th Floor)
9:00 am	Opening Remarks – Barbara Beck, HT (ASCP), ASMH President
9:15 am	A Not-so-Typical Day in the Mohs Lab – Kristin Cox, HT
9:45 am	High Risk SCC – Marc Brown, MD
10:15 am	Break – ASMH Exhibit Area (Salon G – 6 th Floor)
10:30 am – 2:00 pm	Informal Training for Mohs Fellows and Surgeons in Exhibit Hall (Salon G – 6 th Floor)
10:30 – 11:30 am	General Session 5 (Salon F – 6 th Floor)
10:30 am	Uncommon Tumors – R. Stan Taylor, III, MD
11:00 am	Troubleshooting Open Forum – Beth Uri, HT (ASCP)
11:30 am – 12:45 pm	Lunch on Your Own
12:45 – 2:00 pm	General Session 6 (Salon F – 6 th Floor)
12:45 pm	CLIA Session – Barbara Beck, HT (ASCP)
1:15 pm	Getting an Office Ready for AAAHC Inspections and CLIA Audits – Pat Ferrigno
2:00 – 4:00 pm	Workshops <ul style="list-style-type: none"> • Intermediate Cryostat Workshop (Salon G – 6th Floor) • Advanced Cryostat Workshop (Salon G – 6th Floor) • Slide Troubleshooting Workshop (Room 408 – 4th Floor) • MART-1 Immuno Staining Workshop (Room 410 – 4th Floor)
4:00 pm	Meeting Adjourned

www.mohscollege.org/asmh

Total Solutions Now MOHS Surgery Laboratory Set Up



TBS can provide a Turn-Key Operation Including:

- Financial feasibility analysis
- Laboratory design
- Consultation, service and advice
- Equipment, reagent and supplies selection

One Source for All Your Laboratory Needs

Triangle Biomedical Sciences is the one source for GI, Urology, MOHS & Dermatology Laboratory Instrumentation, Reagents, Supplies and New Lab Consulting Services.

For more than 25 years, TBS has been providing pathology laboratories a comprehensive package of equipment, reagents and supplies; training in the use of products; and ongoing service of the equipment. With the emergence of enhanced patient services provided by in-house physician - practice laboratories, TBS is ideally positioned to assist practice management with turnkey solutions.

Triangle Biomedical Sciences, Inc.

3014 Croasdaile Drive
Durham, North Carolina 27705
phone 919.384.9393
fax 919.384.9595
Email: tbs@trianglebiomedical.com

To learn more about TBS please visit us at
www.trianglebiomedical.com

SAVE THE DATE

Mohs College 43rd Annual Meeting
THURSDAY, APRIL 28–SUNDAY, MAY 1, 2011

FOUNTAINBLEAU LAS VEGAS, NV

