A Survey of Mohs Tissue Tracking Practices

Jessica B. Dietert, MD* and Deborah F. MacFarlane, MD, MPH†

BACKGROUND There are little data regarding error within the multistep process of Mohs micrographic surgery (MMS).

OBJECTIVE A survey of Mohs surgeons was performed to evaluate variation in tissue handling and processing within the MMS process.

METHODS AND MATERIALS A 9-question electronic survey was distributed to members of the American College of Mohs Micrographic Surgery. A total of 97 responses were analyzed.

RESULTS Most surgeons personally transport the tissue (71.1%), most frequently in a specimen container (54.6%). Method of tissue identification during transportation varied significantly. Most surgeons personally hand-draw the map (77.1%). A diagram was most commonly used to convey tissue orientation to the histotechnician (65.4%). Only 31.3% of histotechnicians used labeling of blocks to identify tissue within the cryostat. Most respondents (72.2%) are the only surgeon processing tissue in the laboratory at one time; however, 28.9% reported performing 10 or more cases per day.

CONCLUSION Most respondents are responsible for tissue transport and mapping, which likely reduces potential error. However, the method of transport and labeling, as well as identification by the histotechnician, was more variable. Ultimately, having a consistent process and clear communication with personnel will help reduce potential error during Mohs surgery.

The authors have indicated no significant interest with commercial supporters.

In recent years, there has been an increased awareness among physicians of the significance of quality control and the steps that are needed to monitor medical error and adverse outcomes. This is a result of publications citing a high rate of hospital mortality directly related to errors in management.[1] Patient safety studies are lacking within the dermatologic surgery literature, particularly with respect to protocol during Mohs micrographic surgery (MMS). In this survey, the authors sought to identify potential problems within the MMS process in an effort to reduce medical error.

Although MMS is an efficient, tissue-sparing technique commonly used for the removal of cutaneous malignancies, the process involves many steps that introduce the possibility for multiple errors. Potential sources of error may include but are not limited to: wrong site/wrong patient, incorrect specimen labeling, tissue transport, orientation errors, sample mislabeling during histologic processing, and final interpretation of patient tissue (Figure 1). Each subsequent tissue layer further increases the risk of error. Similarly, as the volume of cases increases, so does the potential for possible errors in specimen handling, labeling, and consequently interpretation. To help minimize error, many dermatology departments have implemented standardized specimen handling protocols.[2,3]

The authors chose to survey dermatologic surgeons to assess current Mohs surgery tissue-handling practices and thereby identify areas for potential patient safety improvement.

Division of Dermatology, Washington University in Saint Louis School of Medicine, St. Louis, Missouri; †Department of Dermatology, MD Anderson Cancer Center, Houston, Texas

© 2018 by the American Society for Dermatologic Surgery, Inc. Published by Wolters Kluwer Health, Inc. All rights reserved.
ISSN: 1076-0512 • Dermatol Surg 2019;45:514–518 • DOI: 10.1097/DSS.0000000000001723

© 2018 by the American Society for Dermatologic Surgery, Inc. Published by Wolters Kluwer Health, Inc. Unauthorized reproduction of this article is prohibited.

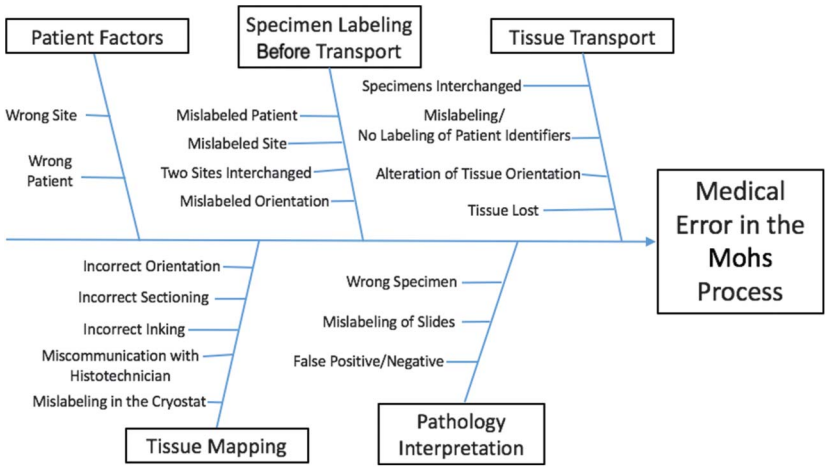

Figure 1. A fishbone diagram depicting the potential sources of error in the Mohs process.

Methods

An electronic survey (using SurveyMonkey.com) of 9 questions (Table 1) was distributed to all members registered with the American College of Mohs Surgery through e-mail directly from the organization. There were 1,396 members at the time the e-mail was sent. Responses were collected from March 2016 to April 2016. A total of 97 responses were obtained. All received responses were included and analyzed. SurveyMonkey.com collects and reports responses as a percentage of the total number of responses, which is reported in Table 1. An institutional review board approval was neither required nor obtained.

Results

Responses represented by percentage are depicted in Table 1.

Discussion

Tissue Transportation

In this survey, tissue transport from bedside to laboratory was most frequently performed by the Mohs surgeon (71.1%), and less often nursing staff (9.3%), the histotechnician (7.2%), or a training physician (1.0%). Furthermore, 11.4% of responding Mohs surgeons reported that transportation method can vary depending on the circumstance. Tissue transport was most often accomplished by placing the specimen in a container (54.6%) and less frequently on a piece of Telfa or card (25.8%), by hand (4.1%), or a combination thereof. The majority of the "Other" responses (15.5%) reported using a gauze, surgical sponge, Mohs map, tray, or clipboard for tissue transport.

Tissue Identification

Various methods of identification were used to accompany the specimen during transport, including patient label (22.7%), preprinted map (27.8%), or hand-drawn picture (21.7%). "Other" responses (27.8%) included a combination of these methods, as well as simply patient name and birth date.

To the authors' surprise, no responders used digital photography as a form of identification to accompany the specimen. This is an accurate, inexpensive, efficient, and objective method of both specimen identification and orientation relative to the patient. Photography has been widely reported to be commonly used for confirming biopsy sites by Mohs surgeons,[4–6] with a previous 2010 survey of 325 Mohs surgeons reporting that 89% preferred photograph for biopsy site identification.[7] There have also been numerous reports of Mohs surgeons using Polaroid or printed digital images of the actual tissue specimen as a Mohs map.[8–13] This method provides an accurate depiction of the tissue shape, orientation, inking, and sectioning that can be drawn onto the photograph of the specimen (digitally or by hand once printed). Recently, Kantor[14] reported a method of creating a fully digital photographic Mohs map using a handheld tablet or smartphone and simple photo-editing software.

© 2018 by the American Society for Dermatologic Surgery, Inc. Published by Wolters Kluwer Health, Inc. Unauthorized reproduction of this article is prohibited.

TABLE 1. Tracking of Mohs Tissue Survey Results

1. Who is responsible for transferring the Mohs specimen from the bedside into the Mohs laboratory?
   - The Mohs surgeon (71.1%)
   - Other MD; resident, fellow (1.0%)
   - Nursing staff (9.3%)
   - Histotechnician (7.2%)
   - Other (11.4%)
2. How is the specimen transferred?
   - By hand (4.1%)
   - On a piece of Telfa/card (25.8%)
   - In a container (54.6%)
   - Other (15.5%)
3. What method of identification accompanies the specimen into the laboratory?
   - Patient label (22.7%)
   - Preprinted map or cartoon (27.8%)
   - Hand-drawn picture (21.7%)
   - Digital image (0%)
   - Other (27.8%)
4. Who draws out the Mohs map before tissue processing?
   - Surgeon (77.1%)
   - Other MD; resident, fellow (2.1%)
   - Nursing staff (5.2%)
   - Histotechnician (15.6%)
5. How does your histotechnician identify orientation of tissue?
   - Photograph (1.6%)
   - Diagram (66.3%)
   - Direct communication with Mohs surgeon (32.5%)
6. How does your histotechnician identify embedded tissue on the chuck within the cryostat?
   - Memory (7.3%)
   - By a label (31.3%)
   - By position within the cryostat (35.4%)
   - By color of embedding medium (13.5%)
   - Other (12.5%)
7. What is the nature of your Mohs practice?
   - Academic (29.9%)
   - Private practice (60.8%)
   - Other (9.3%)
8. On average, how many Mohs surgeons process tissue in your laboratory at the same time?
   - 1 (72.2%)
   - 2 (23.7%)
   - 3 or more (4.1%)
9. How many cases are performed on a typical Mohs day?
   - 5 or less (16.5%)
   - 6–8 (33.0%)
   - 8–10 (21.6%)
   - 10 or more (28.9%)

The authors support the practice of using photography for specimen identification and orientation. The senior author's preference is a printed color photograph to accompany the specimen during all stages of processing, printed with a portable photograph printer. Previous reports suggest photographing the tumor preoperatively, the surgical defect immediately postoperatively, or simply the specimen alone. The authors prefer to photograph the tissue specimen adjacent to the immediate postoperative defect

© 2018 by the American Society for Dermatologic Surgery, Inc. Published by Wolters Kluwer Health, Inc. Unauthorized reproduction of this article is prohibited.

(similar to the method reported by Jih and colleagues).[9] Mapping can then be drawn onto the photograph of the specimen itself (similar to traditional hand-drawn Mohs mapping). The cost of a digital camera and photograph printer (Figure 2) is minimal and dispenses of the hand-drawing of a Mohs map, helping both the Mohs surgeon and the histotechnician. Photographed Mohs maps have not objectively been shown to improve accuracy and outcomes in Mohs surgery; however, they have proven useful, inexpensive, and time efficient in the senior author's 20-year experience with this method. Based on a growing body of literature supporting the use of digital photography for Mohs mapping, this practice is becoming more widely accepted. Barriers to implementation of this technique may include the need to acquire new equipment, training of medical staff, the perception of possible time delays (although this has not been the senior author's experience), and familiarity with hand-drawing of maps.

The traditional Mohs map may be drawn at bedside or after transport to the histopathology laboratory. The majority of responding Mohs surgeons draw the map themselves (77.1%), and less frequently have the histotechnician (15.6%), nursing staff (5.2%), or training physician (2.1%) perform this task. "Other" responses, which constituted 11.4%, indicated that the surgeon, fellow, nurse, and/or histotechnician all may draw the Mohs map depending on the scenario. This is consistent with previous data from Silapunt and colleagues,[15] where 66.5% of 310 survey respondents report that the Mohs surgeon prepares the map.

Once the Mohs map is prepared, the tissue is then transferred to the histotechnician, which introduces an additional source of potential error. It is essential that the histotechnician properly orient the tissue before tissue processing. The majority of physicians surveyed (65.4%) use a diagram to convey tissue orientation, while less (32.5%) use direct communication with the histotechnician. Numerous participants added that they place ink or hatch marks at 12 o' clock on the specimen as well.

Once within the cryostat, various methods are used by the histotechnician to identify embedded tissue. A significant proportion of histotechnicians used tissue position within the cryostat (35.4%) as a means of tissue identification. With multiple Mohs specimens in the cryostat, this could be a potential source of error. The remaining respondents identify embedded tissue by a label (31.3%), the color of the embedding medium (13.5%), or surprisingly, by memory alone (7.3%).

Of interest, 23.7% of respondents reported that 2 or more Mohs surgeons processed tissue in the laboratory at the same time. In addition, 28.9% of respondents reported performing 10 or more cases daily. Logically, the potential for errors in tissue processing increases as the volume of tissue increases.



Figure 2. An inexpensive digital camera and photo printer can be used for convenient printing of photographs within the Mohs laboratory.



Figure 3. Bedside photography of specimen orientation adjacent to the Mohs defect can aid in tissue mapping.

© 2018 by the American Society for Dermatologic Surgery, Inc. Published by Wolters Kluwer Health, Inc. Unauthorized reproduction of this article is prohibited.

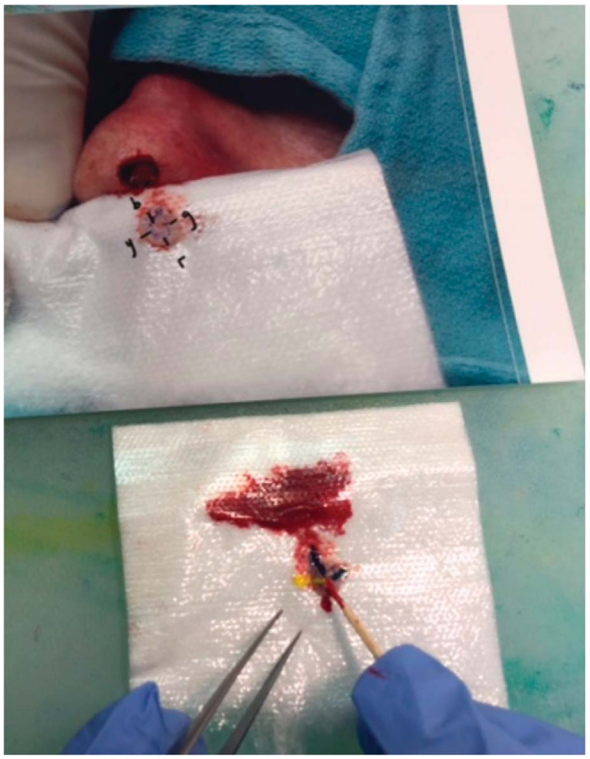

Figure 4. Mapping of the specimen inking and orientation can be drawn directly onto the photograph of the surgical defect.

Conclusion

Although it is acknowledged that the survey was of a small size, some generalizations may be drawn. Consistency in performance of the multiple steps occurring between obtaining the Mohs specimen and interpretation of the final pathology result is crucial to minimizing the potential for error. Routinely transporting, labeling, orienting, and conveying this information to the histotechnician in a methodical and clear manner fosters such consistency. The authors suggest that photography of the Mohs specimen may replace the drawing of a map and facilitate specimen identification and orientation. Photographs of specimen orientation adjacent to the patient defect can be printed using a photo printer (Figure 3) and used for mapping purposes (Figure 4) once the tissue is transported to the laboratory. Consistency in the histologic processing of the Mohs specimen will also minimize error. Tissue position within the cryostat in particular needs to be methodically documented to avoid confusion.

In an effort to reduce potential error in the multistep Mohs surgical process, it is suggested that both physicians and histotechnicians alike constantly evaluate their practices for efficiency, safety, and areas for potential improvement. Transparency, accountability, and continual evaluation for quality improvement within the medical community are critical to reduce human error.

References

1. Kohn LT, Corrigan JM, Donaldson MS, editors. *To Err is Human: Building a Safer Health System. Institute of Medicine (US) Committee on Quality of Health Care in America*. Washington, DC: National Academies Press (US); 2000.
2. Reeder VJ, Gustafson CJ, Mireku K, Davis SA, et al. Trends in Mohs surgery from 1995 to 2010: an analysis of nationally represented data. Dermatol Surg 2015;41:397–403.
3. Kim JK, Dotson B, Thoms S, Nelson KC. Standardized patient identification and specimen labeling: a retrospective analysis on improving patient safety. J Am Acad Dermatol 2013;68:53–6.
4. Zhang J, Rosen A, Orenstein L, Van Voorhees A, et al. Factors associated with biopsy site identification, postponement of surgery, and patient confidence in a dermatologic surgery practice. J Am Acad Dermatol 2016;74:1185–93.
5. Rossy KM, Lawrence N. Difficulty with surgical site identification: what role does it play in dermatology? J Am Acad Dermatol 2012;67: 257–61.
6. Alam M, Lee A, Ibrahimi OA, Kim N, et al; Cutaneous Surgery Consensus Group. A multistep approach to improving biopsy site identification in dermatology: physician, staff, and patient roles based on a Delphi consensus. JAMA Dermatol 2014;150: 550–8.
7. Nemeth SA, Lawrence N. Site identification challenges in dermatologic surgery: a physician survey. J Am Acad Dermatol 2012;67:262–8.
8. Papa CA, Ramsey ML. Surgical pearl: digital imaging for mapping Mohs surgical specimens. J Am Acad Dermatol 2000;43:712–3.
9. Jih MH, Goldberg LH, Friedman PM, Kimyai-Asadi A. Surgical pearl: the use of polaroid photography for mapping Mohs micrographic surgery sections. J Am Acad Dermatol 2005;52:511–3.
10. Lin BB, Taylor S. Digital photography for mapping Mohs micrographic surgery sections. Dermatol Surg 2001;27:411–4.
11. Moriarty B, Seaton ED, Deroide MD. Use of digital photographic maps for Mohs micrographic surgery. Dermatol Surg 2014;40:349–51.
12. Alcalay J. Digital computerized mapping in Mohs micrographic surgery. Dermatol Surg 2000;26:692–3.
13. Sprockel MD, Munte K, Plak P, Van Den Bos RR. How we do it: digital photomapping in Mohs micrographic surgery. Dermatol Surg 2016;42: 1384–98.
14. Kantor J. Fully digital Mohs map for micrographic surgery. J Am Acad Dermatol 2018;78:e65–e66.
15. Silapunt S, Peterson SR, Alcalay J, Goldberg LH. Mohs tissue mapping and processing: a survey study. Dermatol Surg 2003;29: 1109–12.

Address correspondence and reprint requests to: Jessica B. Dietert, MD, 505 W Louis Henna Blvd, Suite 200, Austin, TX 78728, or e-mail: nikkidietert@gmail.com

© 2018 by the American Society for Dermatologic Surgery, Inc. Published by Wolters Kluwer Health, Inc. Unauthorized reproduction of this article is prohibited.

Original article

CED
Clinical and Experimental Dermatology

An international survey characterizing Mohs tissue processing techniques and Mohs margin thresholds: how close is too close?

William T. N. Hunt[1] and **Toby G. Nelson**[1]

[1]*Mohs Surgery Unit, Department of Dermatology, Rowan House, University Hospitals Plymouth NHS Trust, Plymouth, UK*

doi:10.1111/ced.15178

Downloaded from academic.oup.com/ced/article/47/8/1472/6692976 by University of Basel user on 21 October 2026

Abstract

Background. From practice, we identified heterogeneity in Mohs micrographic surgery (MMS) specimen tissue processing techniques and specifications, and in the Mohs surgeons' assessment of MMS specimen histological tumour clearance.

Aim. By surveying an international cohort of Mohs surgeons, we determined to characterize variation in margin threshold assessment (number of wafers/sections free of tumour to declare tumour clearance).

Methods. An online questionnaire was distributed to Mohs surgeons in the UK, European countries, Australia and New Zealand, assessing the background demographics of the surgeons and the technical factors involved in MMS tissue processing and posing three MMS scenarios to define margin thresholds.

Results. In total, 114 consultant/attending-level Mohs surgeons responded, giving a response rate of 33.5% from 20 countries (including UK nations). The first scenario posed was a 20-mm cheek basal cell carcinoma (BCC) excised by MMS with a fully complete first wafer (7 μm) clear of tumour and the second wafer (after trimming interval of 50 μm) demonstrating a small dermal focus of nodular BCC; of the 58 surgeons, 16 (27.6%) would not take another stage. With a follow-up question, 16 of the 58 (27.6%) surgeons specified wanting three clear sections to declare tumour clearance. When the same scenario had a change to a 20-mm infiltrative BCC, 84.2% (48 of 57 surgeons) required a second MMS stage, with a follow-up question clarifying that a third (19 of 57) wanted three clear sections to determine clearance. For a well-differentiated 15-mm squamous cell carcinoma with the same factors there was no majority consensus, with the same proportion of surgeons (22.6%; 12 of 53) calling tumour clearance after one, two and three clear section(s) respectively. For MMS specimen processing specifications, routine sections/wafers of 5–10 μm were reported by 77.4% of respondents (48 of 62) and for trimming interval values, 78.6% (48 of 61) specified a range between 20 and 200 μm.

Conclusion. By surveying international Mohs surgeons, we highlight surgeon background characteristics, peer-compare assessment of margin thresholds for tumour clearance across three scenarios, and delineate tissue processing and intraoperative approaches.

Introduction

Ensuring accuracy in tumour clearance assessment within Mohs micrographic surgery (MMS) facilitates the exceptionally low recurrence rates seen after MMS surgery on both primary and recurrent keratinocyte cancers.[1–3] However, margin clearance assessment has been demonstrated to be complex, dynamic and multifactorial.[4] Confirmation of tumour clearance using the number of tumour-free sections (or distance in μm) has been described as the 'margin threshold'.[4] This assessment is further complicated in practice by large variations in tissue processing of MMS specimens.[4–6]

Correspondence: Dr William T. N. Hunt, Mohs Surgery Unit, Department of Dermatology, Rowan House, University Hospitals Plymouth NHS Trust, Derriford Rd, Plymouth, PL6 8DH, UK
E-mail: huntwtn@doctors.org.uk

Accepted for publication 9 March 2022

© 2022 British Association of Dermatologists.

We have noticed significant regional and national variation both margin thresholds and tissue processing. Similarly, nearly 10 years ago Cartee and Monheit[4] assessed 'margin thresholds' from an American cohort of Mohs surgeons, and noted substantial heterogeneity in practice. We aimed to describe margin thresholds using an international cohort of Mohs surgeons from the UK, European countries, Australia and New Zealand. Using survey methodology, we characterized more than one-third of Mohs surgeons from four surgical organizations. The survey captures the differential MMS specimen tissue processing approaches and intraoperative preferences, and highlights the margin thresholds used by Mohs surgeons on a selection of commonly encountered tumours.

Methods

Study design

An online questionnaire was developed, which was responsive to the answers given by the respondents; the maximum number of questions was 20. Only attending/consultant Mohs surgeons were eligible. A brief questionnaire introduction stated that the respondent might require the discussion with their MMS technician for survey completion. The questionnaire established background characteristics and then elucidated technical factors on tissue processing with definitions (Table 1, Fig. 1a–e). Three scenarios were then presented to establish the MMS margin thresholds the surgeon would use (Fig. 2). The questionnaire concluded with two questions regarding intraoperative preferences.

Study population

From January 2021, the survey was circulated to the British Society of Dermatological Surgery (BSDS), the European Society of Micrographic Surgery (ESMS), the Australian Mohs Group of The Australasian College of Dermatologists (ACD) and The New Zealand Society of Mohs Surgery (NZSMS). Follow-up reminders were undertaken to improve response rates.

Table 1 Definitions used in survey: scenario factors and margin threshold questions.

Definitions used in the survey
Section: a wafer of tissue that is placed on a slide for diagnosis
Level: a single section or a series (ribbon) of sections taken from the same depth in the block with a trimming interval between them. Also known as a step
Trimming interval: the distance (in μm) between levels

Scenarios

Respondents were provided the following hypothetical MMS laboratory scenario:

You have operated on a primary tumour and the following parameters are in place when the tissue specimen has been processed in one piece (not divided).

Each section is 7 μm thick. Each level consists of a single section. The distance between each level is 50 μm (trimming interval). No facing of the block (trimming of the block before sectioning commences) is undertaken. The first section off (true surgical margin) is fully complete with 100% epidermal and deep tissue present. Slides are haematoxylin and eosin only.

You have operated on: (Scenario 1): a 20-mm *nodular* basal cell carcinoma (BCC; Scenario 2) a 20-mm *infiltrative* BCC; and (Scenario 3) a 15-mm well-differentiated squamous cell carcinoma (SCC), on the medial cheek. The first section is clear. The second section has a tiny nest of BCC/SCC in the dermis, which is seen throughout the later sections. Would you take another MMS stage?

If Yes: if so, given the same scenario how many sections free of tumour would you require before you call it clear (margin threshold)?

Statistical analyses

Statistical analyses were undertaken using GraphPad Prism (V9.2.0; GraphPad, San Diego, CA, USA). Proportions were analysed with Fisher exact test and χ^2 test. Post-hoc testing used the manual Bonferroni correction. P values were two-tailed with $P < 0.05$ considered statistically significant.

Results

Participants and baseline characteristics

There were 114 eligible responses with at least a proportion of the survey completed. The overall response rate was 33.5% (114 of 340) from the confirmed consultant/attending Mohs surgeons from the total society/group rosters. The overall baseline characteristics are summarized in Fig. 1(a–e). Responses were received from 20 countries (including UK nations). The number of cases undertaken per year was a mode of < 250, reported by 61.4% (70 of 114

Downloaded from academic.oup.com/ced/article/47/8/1472/6692976 by University of Basel user on 21 October 2026

© 2022 British Association of Dermatologists.

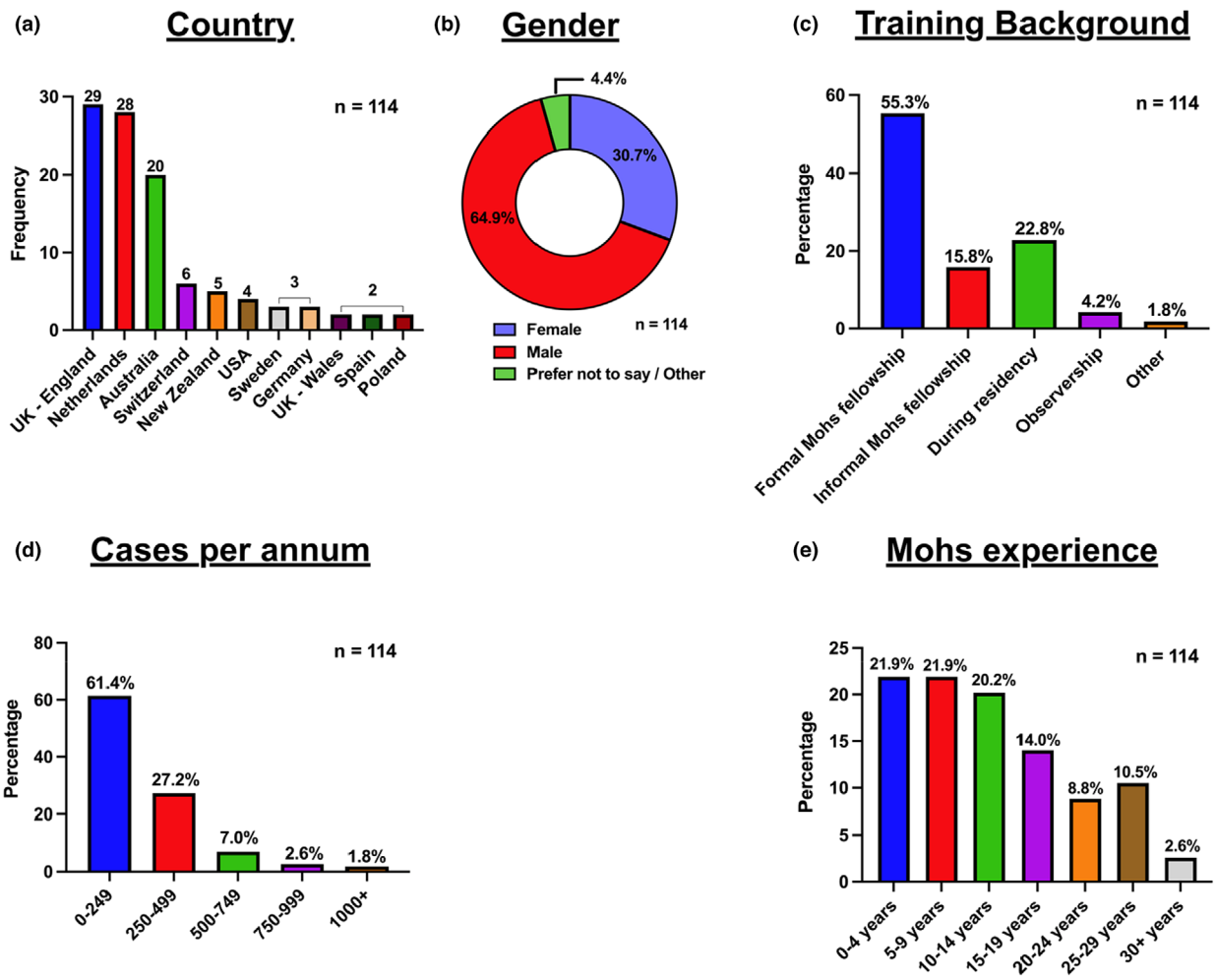

Figure 1 Baseline characteristics of the survey respondents. (a) The top 10 countries by respondents. With England, the Netherlands and Australia representing the top three countries by responses, and making up 67.5% (77 of 114) of the total number. (b) Of the 114 respondents, 35 of 114 (30.7%) were female, and 64.9% (74 of 114) were male, while 4.4% (5 of 114) responded 'other' or 'prefer not to say'. (c) Over half (55.3%; 63 of 114) of respondents had been trained in Mohs micrographic surgery in a formal fellowship and 22.8% (26 of 114) had been trained in their registrar/residency years in dermatology. (d) Most respondents (70 of 114; 61.4%) undertook 0–249 cases per year. (e) The joint mode responses for years of MMS experience were 0–4 and 5–9 years (each 25 of 114; 21.9%).

surgeons), with another 27.2% of respondents undertaking 250–499 cases per year. Regarding the MMS experience of respondents, the ranges 0–4 and 5–9 years both had a mode of 21.9% (25 of 114), while there were a handful (2.6%; 3 of 114) of veteran Mohs surgeons with 30+ years of experience. The highest number of respondents was from England (29 of 114; 25.4%), followed by the Netherlands (28 of 114; 24.6%) and Australia (20 of 114; 17.5%). Overall baseline characteristics demonstrated that 63 of 114 respondents (55.3%) had undertaken a formal MMS fellowship and 18 of 114 (15.8%) an informal fellowship, while 26 of 114 (22.8%) had trained in MMS during dermatology residency/registrar training (Fig. 1a–e).

Comparison of the UK, Dutch and Australian responses

Given that 80 of 114 (70.1%) respondents were from the UK, the Netherlands, and Australia, their baseline characteristics were compared (Table 2). One of the notable findings was that the gender composition of the respondents was significantly different, with more female Mohs surgeons in the Netherlands (70.1%), compared with the UK (25%) or Australia (0%) ($\chi^2 = 29.34$; $P < 0.001$). There was a

Downloaded from academic.oup.com/ced/article/47/8/1472/6692976 by University of Basel user on 21 October 2026

 © 2022 British Association of Dermatologists.

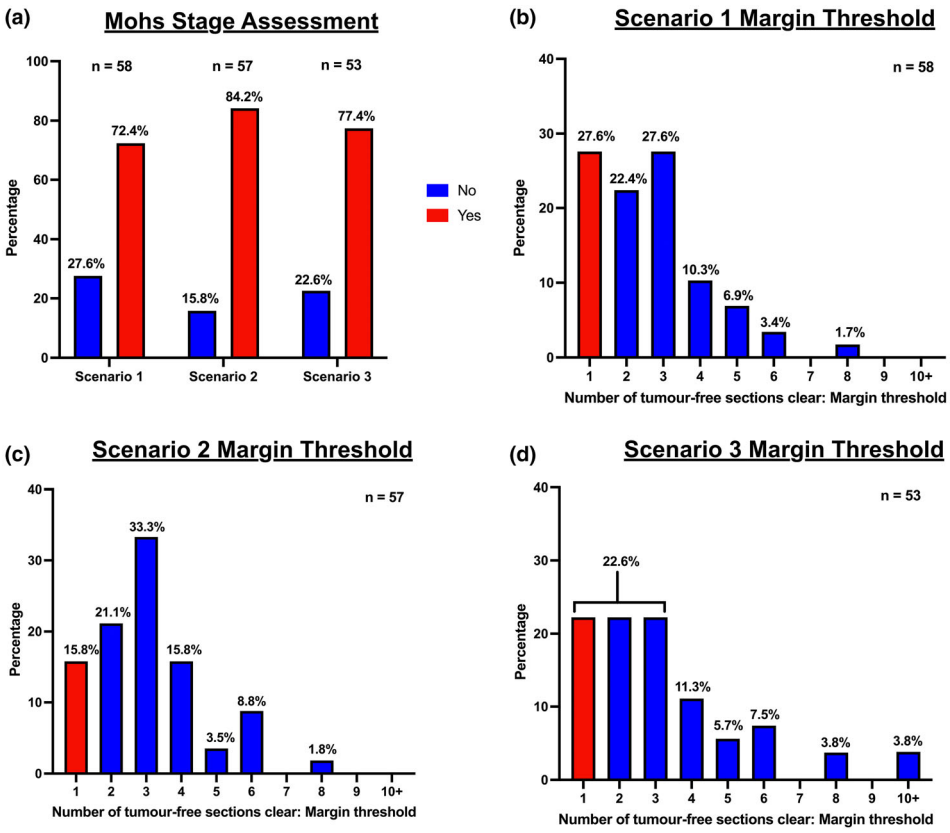

Figure 2 Mohs micrographic surgery (MMS) margin threshold assessments across three scenarios; respondents were provided with hypothetical MMS laboratory scenarios (see Methods). (a) Results from the initial question across the three scenarios as to whether the clinician would take another stage. (b) Scenario 1, combining the responses from the initial (red column) and follow-up questions (blue columns); this graph highlights the margin threshold for the respondents. Of the 58 responses, 16 respondents (27.6%) would be satisfied with one tumour-free section with the described parameters to call the tumour clear. The joint mode response was three tumour-free sections (16 of 58; 27.6%). (c) Scenario 2, similarly combining the responses from the initial (red column) and follow-up questions (blue columns), this graph highlights the margin threshold for the respondents. One-third (33.3%; 19 of 57) would want to have 3 tumour-free sections to call the tumour clear; the next most common response was 2 tumour-free sections 21.1% (12 of 57). (d) The third scenario had the same number of responses for 1, 2 and 3 sections required to be tumour-free to call the tumour clear (all 22.6%, 12 of 53). Again, the red and blue columns show responses from the initial and follow-up questions.

significant difference in MMS training background between respondents from the Netherlands and those from Australia or the UK, with 42.9% of the Dutch Mohs surgeons being trained in MMS during their residency/registrar training compared with 5% from Australia and 6.3% from the UK ($\chi^2 = 19.58$, $P < 0.01$). Other analyses such as Mohs surgeon experience and number of annual cases were not significantly different.

Technical specifications of tissue processing

When questioned on technical specifications of MMS tissue processing, 44.7% (51 of 114) of respondents discontinued the questionnaire, thus the analyses here was based on those who continued.

For the open question on routine wafer (section) thickness, most respondents specified values of 5–10 μm (48 of 62; 77.4%).

Routine distances between levels (trimming intervals) were reported as 50–100 μm by 28 of 61 respondents (45.9%) and, widening the range, as 20–200 μm for 48 of 61 (78.6%).

For level composition, 33 of 62 respondents (53.2%) reported having single sections per level, while 24 of 62 (38.7%) reported serial sections per level (ribboning).

The number of levels required to attain a full epidermal face on a specimen were reported as 1 level (5

Downloaded from academic.oup.com/ced/article/47/8/1472/6692976 by University of Basel user on 21 October 2026

© 2022 British Association of Dermatologists.

Table 2 Comparison of the baseline characteristics of the top three countries by respondents.

Parameters	UK $n = 32$	Neth $n = 28$	Aus $n = 20$	Statistical analysis	Post-test with χ^2 and manual Bonferroni correction[a]
Gender					
Female	8 (25)	20 (71.4)	0 (0)	$\chi^2 = 29.34$, d.f. = 4, $P = 0.001$	**UK vs. Neth, $P < 0.01$**
Male	23 (71.9)	7 (25)	18 (90)		UK vs. Aus, NS;
Prefer not to say/Other	1 (3.1)	1 (3.6)	2 (10)		**Neth vs. Aus, $P < 0.001$;**
MMS training					
Formal MMS fellowship	24 (75)	12 (42.9)	17 (85)	$\chi^2 = 19.58$, d.f. = 6, $P < 0.01$	**UK vs. Neth, $P = 0.02$;**
Informal MMS fellowship	5 (15.6)	4 (14.3)	1 (5)		UK vs. Aus, NS;
During register training/residency	2 (6.3)	12 (42.9)	1 (5)		**Neth vs. Aus, $P = 0.02$**
Observership	1 (3.1)	0 (0)	1 (5)		
Mohs surgeon annual cases[b]					
0–249	22 (68.8)	19 (67.9)	10 (50)	$\chi^2 = 7.694$, d.f. = 8, $P = 0.46$	–
250–499	8 (25)	8 (28.6)	6 (30)		
500–749	2 (6.3)	1 (3.6)	2 (10)		
750–999	0 (0)	0 (0)	1 (5)		
1000+	0 (0)	0 (0)	1 (5)		
Mohs surgeon experience, years					
0–4	12 (37.5)	5 (17.9)	2 (10)	$\chi^2 = 24.59$, d.f. = 12, $P < 0.02$	UK vs. Neth, NS; UK vs. Aus,
5–9	7 (21.9)	10 (35.7)	3 (15)		NS; Neth vs. Aus, NS
10–14	7 (21.9)	6 (21.4)	3 (15)		
15–19	2 (6.3)	4 (14.3)	2 (10)		
20–24	3 (9.4)	0 (0)	4 (20)		
25–29	1 (3.1)	3 (10.7)	3 (15)		
30+	0 (0)	0 (0)	3 (15)		

Aus, Australia; d.f., degrees of freedom; MMS, Mohs micrographic surgery; Neth, Netherlands; NS, not significant. [a]Significant values are in **bold**; [b]as the initial P value was not significant, no *post hoc* testing was indicated.

of 63; 7.9%), 2 levels (16 of 63; 25.4%), 3 levels (15 of 63; 23.8%), 4 levels (11 of 63; 17.5%), 5 levels (5 of 63; 7.9%) and 6 to 10+ levels (11 of 63; 17.5%).

In free comments on the instruments used to freeze down a specimen, 30.0% (18 of 60) reported a cryoblock, 46.7% (28 of 60) a cryospray of liquid nitrogen, 38.3% (23 of 60) a cryoembedder, 8.3% (5 of 60) a cryostat and 6.7% (4 of 60) a freezing processor (PrestoCHILL).

Margin thresholds

Margin threshold assessments are characterized in Fig. 2a with the specified parameters. These involved three individual scenarios with cheek tumours: a 20-mm nodular BCC (Fig. 2b), a 20-mm infiltrative BCC (Fig. 2c) and a 15-mm well-differentiated SCC (Fig. 2d). Free text responses commenting on margin thresholds were stratified into themes. Reasons given for wanting > 1 clear section being tumour-free included a desire to account for a margin of error or to act as a safety margin, or that this was the way the surgeon had been trained. A final standalone question, identified that 9.8% (5 of 51) of respondents felt that their margin threshold would change if there were an opportunity to dual-report MMS sections.

Intraoperative preferences

In the final component of the survey, 45.1% of respondents (23 of 51) reported routinely debevelling their MMS defect prior to closure. Six of 51 respondents (11.8%) would routinely take a safety margin if their MMS sections were very close but clear, and would proceed straight to the repair, discarding the tissue.

Discussion

This questionnaire evaluated an important clinical question often encountered in practice: when in Mohs surgery is a tumour clear and when is it not? Using an international selection of Mohs surgeons, we worked to define margin thresholds using three differing hypothetical scenarios encountered in practice. The responses to the margin assessment questions highlight the complexity of decision-making in assessing tumour clearance. Alani *et al.*, recently reported on a survey of UK Mohs surgeons; the mean number

Downloaded from academic.oup.com/ced/article/47/8/1472/6692976 by University of Basel user on 21 October 2026

 © 2022 British Association of Dermatologists.

of sections required to declare tumour clearance was 2.2 (range 1–6) and for those using microns, it was 165.6 μm (range 50–300 μm).[5] However, as our results demonstrate, rather than being a static assessment, the threshold to confirm tumour margin clearance is dynamic and highly responsive to tumour subtype (Fig. 2a–d). As we highlight from the open free-text responses, additional factors such as MMS training tenets, or a desire to account for errors and to have 'safety margins' also caused some additional variability in the margin threshold. Other technical factors related to MMS sections that have been reported to influence margin thresholds included the presence of scar tissue, inflammation, perineural invasion and slide quality.[5] From our model scenarios, the most common threshold assessment for a 20-mm nodular BCC on the cheek would be to have either one or three (each preferred by 27.6% of respondents) 50-μm-spaced tumour-free 7-μm sections being clear. For an infiltrative BCC on the face, the mode response (33%) was three 50-μm-spaced tumour-free sections being clear. Finally, for a well-differentiated facial SCC the mode response was split equally between one, two and three 50-μm-spaced tumour-free sections being clear, demonstrating clinical equipoise.

Despite these results being an insightful peer reference they are still hypothetical and lack the complexity of the real world. Nevertheless, in contrast to Cartee and Monheit,[4] who previously assessed margin thresholds in the USA, we intended to bring more meaningful assessments by including technical values such as section (wafer) thickness, trimming interval and epidermal completeness. This provides more gravitas to the responses but also perhaps in part reduced participation.[4] Following this theme, at the start of the questions regarding MMS specimen processing, just under half of respondents unexpectedly discontinued the survey (44.7%). We had sought to avert this by having an introductory statement on the questionnaire stating that the involvement of the MMS histotechnician might be needed. We are curious to know in practice how many Mohs surgeons are aware of their MMS sections and levels distances, as that will invariably define their MMS margin thresholds. From the completed questions, it is apparent that the methods of processing MMS specimens are diverse. For routine trimming intervals 78.6% (48 of 61) of respondents reported values of 20–200 μm; however, inversely > 20% therefore stated values outside this range, with values of up to 1000 μm (1 mm) documented. Likewise, for the average number of levels required to gain 100% epidermal views, the results were highly varied, with two and three levels accounting for almost 50% of responses (31 of 63); however, > 25% (16 of 63) highlighted values of 5 to 10+ levels and 7.9% (5 of 63) reported on average at the first level. Such varied responses act not only as a proxy for the quality of the MMS sectioning but also the diverse ways that MMS specimens are prepared and embedded.[6,7] In a US study, the mean number of microns until a full epidermal face was attained was found to be 285 μm for 218 first stages and 280 μm for 65 subsequent stages, both equating to the fourth section in their practice.[8] There are also significant variations both regionally and nationally on who completes the embedding process. Interestingly, in many MMS units in the USA, the histotechnician is the most likely team member to ink (55%) and flatten down (77%) the specimen.[9] This is somewhat echoed by MMS units in the UK, with the embedding component of the procedure undertaken by the MMS histotechnician (78%).[6] In the present study, given the variability of parameters in MMS specimen tissue processing when pooling responses from two continents, we believe that greater standardization of tissue embedding and processing should be considered. Further research into this area would be of benefit.

Our survey of over a third of the Mohs surgeon members of four Mohs/dermatological surgery organizations, with representation of 20 countries of practice, has provided a unique opportunity, for the first time, to characterize the profile of international Mohs surgeons (Fig. 1a–e). From our responses the gender composition within MMS surgery continues to have an overall male preponderance, as has been demonstrated elsewhere, but that does significantly vary by country of practice with the Netherlands respondents identifying as 71.4% female (Table 2).[5,10–12] Notably, respondents were also provided the option of not declaring their gender or of reporting a nonbinary option (total 4.4%; 5 of 114). Notably in the USA, over a third of the American College of Mohs Surgeons (ACMS) members and roughly 50% of ACMS fellows are female.[13,14]

Between countries, there are also significant differences between where MMS training is undertaken (Table 2). Whereas in the UK (75%) and Australia (85%), fellowship-trained Mohs surgeons were the predominant respondents, the Dutch respondents had a significantly different composition and were equally as likely to have received their MMS training during residency (42.9%) as they were to have had formal fellowships (42.9%) (Table 2). Certainly in the UK and Australia, fellowship training is now the

Downloaded from academic.oup.com/ced/article/47/8/1472/6692976 by University of Basel user on 21 October 2026

© 2022 British Association of Dermatologists.

established route of training for MMS surgery.[5,12] Overall, the survey attracted respondents with a good range of experience, with both recently qualified Mohs surgeons and a handful of veteran Mohs surgeons with over 30+ years experience represented (Table 2). Most Mohs surgeons operated on < 250 cases per year, which is similar to findings also reported elsewhere.[12] Conversely, US Mohs surgeons appear to operate on over two-fold that number on average.[15,16]

There are of course limitations to this study. First, it was disappointing to have such attrition during the course of the survey, particularly at the point of the MMS processing technical details. However, as previously mentioned, this is an important finding in itself, with a number of Mohs surgeons perhaps not being familiar with the distances used for their section or level composition. We had a good initial response rate, but it is likely that it is better than reported, because response rates were gauged by self-proclaimed country of practice; however, some respondents will certainly be members of two or more MMS surgery organizations but only compared with a single manifest. Finally, as mentioned earlier, the decision-making process for MMS margin thresholds is complex and dynamic; simulating MMS surgery situations can only go so far to reflect the authenticity of the real thing.

Conclusion

We present the survey responses from an international cohort of Mohs surgeons representing 20 countries across 2 continents. Using three scenarios reflecting commonly encountered tumours, we assessed the tumour margin thresholds when assessing MMS sections, and the common MMS specimen processing parameters in use. Finally, we characterized the respondents, which encompass over one-third of the Mohs surgeons from the four surgical organizations.

What's already known about this topic?

- MMS is a tissue-sparing surgical and histopathological technique.
- In MMS, the Mohs surgeon employs tissue marking and histological analyses using fresh frozen sections processed with a special method to visualize 100% of the deep and peripheral margins using horizontal sectioning, providing confirmation of tumour clearance prior to reconstruction.
- In MMS, confirmation of histological tumour clearance using the number of tumour-free sections (or distance in μm) has been described as the 'margin threshold'.
- There is significant regional and national variation in both assessment of 'margin threshold' and in approaches to tissue processing.

What does this study add?

- We present the survey responses from an international cohort of MMS surgeons representing 20 countries. Characterizing over one-third of the Mohs surgeons from four surgical organizations.
- The 'margin thresholds' across three scenarios using different cutaneous tumours were defined, which serves as a useful peer-reference resource.
- The specifications for MMS specimen tissue processing and the intraoperative practices of the surgeons have been delineated, which highlight large heterogeneity in clinical practice.
- Given the great variation in Mohs specimen tissue processing methods, 'margin threshold' assessment, and intraoperative approaches - further studies to develop evidence and consensus are warranted.

Acknowledgement

We thank all the organizations that circulated our survey, specifically the BSDS, the ESMS, the Australian MMS Group of the ACD, and the NZSMS. We also keenly thank the clinical audit department at the University Hospitals Plymouth NHS trust, in particular Christopher Rollinson and Helen Neilens. We also thank Dr Helen Whitley for her advice on the questionnaire.

Conflict of interest

The authors declare that they have no conflicts of interest.

Funding

None.

Ethics statement

Ethics approval was not applicable. Participants provided implied consent.

Downloaded from academic.oup.com/ced/article/47/8/1472/6692976 by University of Basel user on 21 October 2026

 © 2022 British Association of Dermatologists.

Data availability

Data available on request from authors.

References

1 Weesie F, Naus NC, Vasilic D *et al*. Recurrence of periocular basal cell carcinoma and squamous cell carcinoma after Mohs micrographic surgery: a retrospective cohort study. *Br J Dermatol* 2019; **180**: 1176–82.

2 Tschetter AJ, Campoli MR, Zitelli JA *et al*. Long-term clinical outcomes of patients with invasive cutaneous squamous cell carcinoma treated with Mohs micrographic surgery: a 5-year, multicenter, prospective cohort study. *J Am Acad Dermatol* 2020; **82**: 139–48.

3 Leibovitch I, Huilgol SC, Selva D *et al*. Basal cell carcinoma treated with Mohs surgery in Australia II. Outcome at 5-year follow-up. *J Am Acad Dermatol* 2005; **53**: 452–7.

4 Cartee TV, Monheit GD. How many sections are required to clear a tumor? Results from a web-based survey of margin thresholds in Mohs micrographic surgery. *Dermatol Surg* 2013; **39**: 179–86.

5 Alani A, Wernham AGH, Mann J *et al*. UK National Mohs Surgeon Survey 2020. *Clin Exp Dermatol* 2021; **46**: 1609–10.

6 Jerrom R, Varma S. DS03: Tissue processing in Mohs micrographic surgery: what is current UK practice? *Br J Dermatol* 2021; **185**(Suppl): 104.

7 Aslam A, Aasi SZ. Frozen-section tissue processing in Mohs surgery. *Dermatol Surg* 2019; **45**(Suppl 2): S57–69.

8 LeBoeuf M, Bieber K, Cooper S, Isenor A. Quantitative analysis of frozen section histology in Mohs micrographic surgery. *Dermatol Surg* 2020; **46**: 876–9.

9 Ishii L, Arshanapalli A, Surprenant D *et al*. Contemporary Mohs micrographic surgery histologic preparation methods, laboratory-assistive personnel training, and practice setting – a survey study. *Dermatol Surg* 2019; **45**: 768–71.

10 Tierney EP, Hanke CW, Kimball AB. Recent changes in the workforce and practice of dermatologic surgery. *Dermatol Surg* 2009; **35**: 413–19.

11 Nguyen JC, Jacobson CC, Rehmus W, Kimball AB. Workforce characteristics of Mohs surgery fellows. *Dermatol Surg* 2004; **30**: 136–8. discussion 8.

12 Rutherford T, Elliott T, Vinciullo C. Mohs surgery in Australia: a survey of work practices. *Australas J Dermatol* 2011; **52**: 98–103.

13 Papac N, Collins L. The female pioneers in Mohs micrographic surgery. *Int J Womens Dermatol* 2019; **5**: 18–20.

14 Kohli N, Golda N. Practice patterns and job satisfaction of Mohs surgeons. *Dermatol Surg* 2018; **44**: 42–7.

15 Alhaddad M, Zade J, Nabatian A *et al*. Association between surgeon-specific features and number of stages, flaps, and grafts in Mohs Micrographic surgery: a retrospective observational study of 59 early-, mid-, and advanced-career Mohs surgeons. *Dermatol Surg* 2017; **43**: 1358–62.

16 Alam M, Berg D, Bhatia A *et al*. Association between number of stages in Mohs micrographic surgery and surgeon-, patient-, and tumor-specific features: a cross-sectional study of practice patterns of 20 early- and mid-career Mohs surgeons. *Dermatol Surg* 2010; **36**: 1915–20.

Downloaded from academic.oup.com/ced/article/47/8/1472/6692976 by University of Basel user on 21 October 2026

© 2022 British Association of Dermatologists.

Mohs Mapping Fidelity: Optimizing Orientation, Accuracy, and Tissue Identification in Mohs Surgery

Janet Y. Li, MD,* Sirunya Silapunt, MD,* Michael R. Migden, MD,† Jamie L. McGinness,‡ and Tri H. Nguyen, MD§

BACKGROUND Mohs micrographic surgery (MMS) is a highly effective process that requires consistent accuracy in resection, mapping, and histologic interpretation. Although the general sequence in MMS is similar, there are numerous variations among Mohs surgeons as to how this process is performed.

OBJECTIVE This article aims to review the process of MMS, with the intent to identify and mitigate the potential errors at each step. Existing variations will be discussed and protocols offered to minimize error and optimize accuracy.

METHODS A Pubmed search was performed for publications on methods of tissue mapping, orienting, and processing in MMS.

RESULTS Our literature review highlights various techniques for tissue orientation, transfer, flattening, inking, mapping, and processing of later stages and multiple specimens. We discuss our system, which reduces error during tissue transfer, tissue identification in vivo and ex vivo, and tissue flattening. Furthermore, we discuss adaptations to increase the accuracy during reexcisions of subsequent Mohs layers.

CONCLUSION Variations in MMS reflects the diverse training and creativity among Mohs surgeons. Unless potential errors are addressed, however, false negatives will occur and undermine the superior cure rate of MMS.

The authors have indicated no significant interest with commercial supporters.

Mohs micrographic surgery (MMS) relies upon a consistent accuracy to ensure margin clearance and patient safety. It is paramount that any tumor found on histology is translated clearly to its location on the Mohs map and the patient. Errors in MMS may lead to false negative margins, inaccurate tissue resection, and ultimately tumor recurrence. We identify seven key steps where errors may critically undermine the accuracy of MMS, review the common variations for these key steps as practiced by Mohs surgeons, and suggest enhancements to minimize errors and optimize accuracy.

Marking Techniques for Orientation

Orientation techniques include the use of suture,[1] staples,[2] tissue nicks (TN),[1] gentian violet (GV),[3] or methylene blue.[4] GV does not leave a permanent mark on the skin and is easy to use, but may be easily smudged and needs to be sterilized.[5] Lines drawn with GV should be long and allowed to dry briefly, prior to starting the procedure, to guard against smudging. Bagheri and colleagues[3] randomized 101 patients to have their tissue margins oriented via superficial TN or GV. They found no instances of misorientation in either group and no visible scars from TNs. However, their study involved an average of 1.65 Mohs layers and did not address which technique is superior for more complex cases. Larson previously described the placement of reference staples on the tumor and adjacent wound edge.[2] They are easy to use and are not skill-dependent, but staples on the tumor must be removed prior to embedding, and so cannot aid in orientation during slide review. Magee and Wagner[4] have used methylene blue tattoos placed in the dermis with a 22-gauge needle to correspond with TNs placed only on the specimen. This method does not smudge,

Department of Dermatology, University of Texas McGovern Medical School, Houston, Texas; †MD Anderson Cancer Center, Houston, Texas; ‡Department of Dermatology, Springfield Clinic, Springfield, Illinois; §Texas Surgical Dermatology PA, Spring, Texas

© 2017 by the American Society for Dermatologic Surgery, Inc. Published by Wolters Kluwer Health, Inc. All rights reserved.
ISSN: 1076-0512 • Dermatol Surg 2018;44:1–9 • DOI: 10.1097/DSS.0000000000001215

© 2017 by the American Society for Dermatologic Surgery, Inc. Published by Wolters Kluwer Health, Inc. Unauthorized reproduction of this article is prohibited.

unlike GV, and may last from several hours to 2 weeks. Since methylene blue is soluble in alcohol, it is removed during horizontal frozen section processing and does not interfere with staining. There have been no reported cases of adverse events from its use as a skin stain.[6] Cognetta and colleagues[7] describe a "stereo-orienting" technique which involves placing the specimens on the glass slide at the microtome in the same orientation as the Mohs map and the patient. This bypasses the need to rotate the slide to match the Mohs map. "Stereo-orienting" may be combined with the use of an object marker, which screws directly into the microscope nosepiece. Once tumor is identified, the user presses the object marker down onto the glass slide, creating an ink circle around the tumor.[8] Randle and colleagues[9] use superficial TNs at 12, 3, 6, and 9 o'clock positions extending from the wound edge to the specimen.

Our technique is similar to Randle's with the addition of an extra TN. After debulking centrally, the peripheral margin around the tumor is lightly scored, and four superficial TNs are made from the peripheral wound edge *into* the excised specimen at the 12, 3, 6, and 9 o'clock positions. One extra TN is placed equidistant between either the 12 and 9 o'clock positions or the 12 and 3 o'clock positions (Figure 1). A midline scoring incision (connecting 12 to 6 o'clock) may be placed to orient and to help bisect the tissue if needed in the lab. Relaxing incisions may also be made in vivo. The excision is completed at an angle between 45° and 90° and the layer is transferred directly to the transfer card (TC) (Figure 2) and taken to the lab.

If only 4 TNs are placed and the tissue is accidentally dropped, rotated, or shifted during transfer, orientation is lost. The extra TN creates asymmetry, which allows for accurate reorientation of the specimen with the defect. TNs are also more readily visible than ink on low-power microscopy (2.5–4×). Incisions on the peripheral wound edge, no deeper than the lower papillary dermis are essential, as deep nicks may impair later repair. TNs on the specimen need to be deepened during processing to accentuate their visibility and prevent closure during embedding. Closely spaced TNs may contribute to tissue folding and tearing during cutting. For smaller specimens, the asymmetric TNs may be more evenly spaced. Instead of 12, 10:30 (extra nick), 9, and 6, they may be at the 12, 10, 8, and 6 o'clock positions. TNs that align the wound edge and the specimen at the time of tumor removal ensure the utmost concordance between the microscopic tissue and the patient.

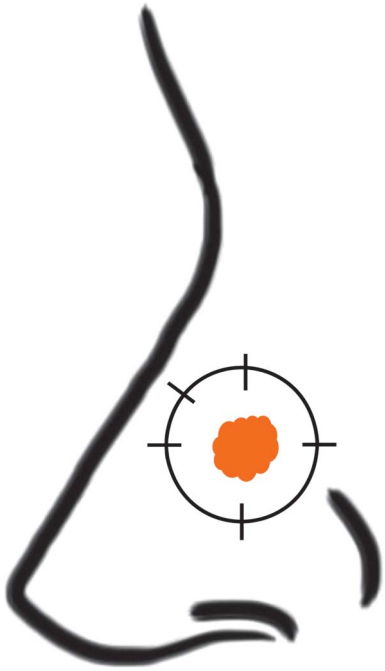

Figure 1. Tissue nicks are made from the specimen edge to the wound edge at 12, 3, 6, and 9 o'clock positions. One extra tissue nick is made between 9 and 12 o'clock.

Previous authors have noted a risk of introducing floaters, or tissue fragments of tumor cells, into tissue nicks.[10] A consensus conference of 26 Mohs surgeons found that the mean rate of floaters per tumor treated using MMS was 1.8%, and the rate of floaters per tissue block was 0.70%.[11] Our nicks are placed in a shallow manner from the outside margin into the tumor, which we postulate minimizes the risk of floaters. Furthermore, we almost always debulk the tumor with a razor blade, not with curettage. This decreases the amount of tumor left in the excised specimen from which floaters may derive. If the tumor is friable or still grossly visible despite debulking, then we do clean the blade in between nicks and we use a new 15-blade for each stage. In 2013, our floater rate was 0.0017%, and in 2012, our floater rate was 0.0057%, and there was no significant difference whether the primary tumor was basal cell carcinoma or squamous cell carcinoma.

© 2017 by the American Society for Dermatologic Surgery, Inc. Published by Wolters Kluwer Health, Inc. Unauthorized reproduction of this article is prohibited.

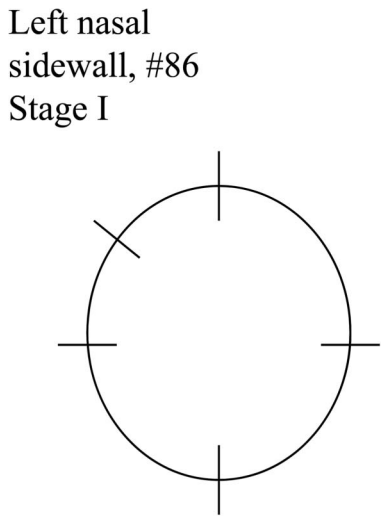

Figure 2. Tissue is placed on the transfer card, which is labeled with the site and the Mohs case number. If the specimen is small, tissue nicks may instead be placed at the 12, 10, 8, and 6 o'clock positions.

Tissue Transfer

Methods for tissue transfer from the patient to the laboratory include placing the specimen on a Telfa pad,[12] filter paper on a petri dish,[13–15] glass slides,[16] and gauze pad.[16] Weber and colleagues place their Mohs layers on a leaf of paper, upon which further flattening and inking takes place.[17] These methods may not protect from specimen shifting during transfer, which can lead to loss of orientation and patient morbidity.

We use a blank TC made of thick card stock, specifically: 80 lb Cover cardstock, style Neenah CLASSIC Laid, Avon Brilliant White (Neenah Paper, Inc., Alpharetta, GA). These may be ordered and shipped from www.paper-papers.com. Sized in 8.5×11 inches, the cardstock may be ordered precut into four smaller rectangles (4.25×5.5 inches). The cardstock is rigid, absorbs blood, adheres tissue, and can be written on. Once on the TC, the tissue can be dropped or even flung and it will remain on the TC in its original orientation. We use a blank TC that is labeled with the site and a unique Mohs case number (e.g., 86 indicates the 86th case of the year) (Figure 2). All further processing (tissue flattening, inking, mapping) occurs on the TC, and the surgeon may simply move or rotate the TC as needed while leaving the specimen in its original location. As the tissue is flattened onto the card, one can easily identify if the tissue is properly relaxed. If the epidermis is lying flat against the rigid TC, then the tissue is adequately relaxed. However, if there is a gap between the epidermis and the card, more relaxation may need to be performed for proper embedding.

Since processing and inking occur directly on the TC, the ink pattern is preserved. We save each TC until the end of the day for reference if needed. If the ink color under the microscope or block number differs from the Mohs map, then the surgeon can refer to the actual ink pattern and label on the card for resolution. Ink color discrepancy may occur for various reasons: the surgeon may ink a color pattern differently from the map, incorrect labeling, or another patient's tissue placed on the wrong slide.

Tissue Flattening

Complete 360° margin evaluation is necessary for the integrity of MMS. This requires for the epidermal margin to lie in the same plane as the deep margin. A survey conducted by Silapunt and colleagues[18] found that 22.6% of Mohs surgeons (310 responders) use heat-extractor flattening in the cryostat, 16.1% use tissue slits, 14.2% use both heat-extractor flattening and tissue slits, 10.3% use aerosol freezing on a glass slide, 9.4% use aerosol freezing and tissue slits, and 3.9% use the Miami special (mechanical flattening using sponge forceps with two attached copper plates and liquid nitrogen). Weber and colleagues[17] use the "cross-hatching" technique of relaxing incisions. Randle and colleagues[9] use a combination of relaxing incisions and mechanical pressure on a glass slide. Wanitphakdeedecha and colleagues[19] expanded on this concept in using in vivo intraoperative relaxing incisions, which are made prior to complete excision in a star/concentric pattern. The benefit of the in vivo method is the ability to stretch the skin and stabilize the tissue, allowing for precise incision placement. Lin and colleagues[20] have also used horizontal relaxing incisions to minimize tethered floaters on thick layers.

To achieve flattening, we use a combination of debulking, in vivo and ex vivo relaxing incisions,

© 2017 by the American Society for Dermatologic Surgery, Inc. Published by Wolters Kluwer Health, Inc. Unauthorized reproduction of this article is prohibited.

and manual flattening (Figure 3A,B). The entire surgical margin, peripheral and deep, should lie in one plane for proper embedding. We debulk the tumor with a double-edged razor blade. We also make an in vivo longitudinal midline scoring incision connecting 12 to 6 o'clock prior to removal of the tumor. In the lab, the tissue is first pressed flat using a 4″ × 4″ gauze, which exudes fluid and allows for significant relaxing. If it does not lie flat, superficial vertical or beveled relaxing incisions are made parallel to but far away from the edge of the tumor. Care should be taken neither to place the relaxing incisions too close to the peripheral margin nor to extend the relaxing incisions into the deep margin. Doing so would disrupt the margins, creating epidermal folding and unintended divisions in the sections.

Specimen Inking

A variety of inking patterns have been described. A standard technique involves inking two adjacent nonepidermal edges with two different colors (e.g., blue and red).[13–15,21] Randle and colleagues[9] create nicks within the tissue at the 12, 3, 6, and 9 o'clock positions, and color-code the 9 and 12 o'clock nicks. These methods are adequate when inking and sectioning occur flawlessly. However, in cases where one ink color may not cover the entire surgical margin, or may not appear during tangential sectioning, more colors provide a wider safety net.

We ink the specimen directly on the TC, typically with 4 different colors (blue at 12, green at 3, red at 6, yellow at 9) for a single section. However, a fifth color can also be used at the extra TN (orange, lime, black, violet, etc.). If the histotechnician mistakenly mixes different case blocks, this additional unique identifier aids in determining the error. For the first layer, a single round or oval section is inked only within the cut edges of the nicks, making sure to cover the entire surgical margin and epidermis of the TN (Figure 4). The epidermis at the nick may not be pushed into the same plane as the remainder of the tissue during embedding, which can result in a false negative. This tissue-embedding error can be easily visualized if ink is not seen actually touching the epidermal margin at the nick. In order to reflect the true deep margin, ink should be thinly applied only to the edge touching the TC, as excessive ink running onto the undersurface may confound the true deep margin. When there is a nonepidermal edge, we ink the tissue in 360° with 4 colors to allow for more complete margin assessment. Precise inking is time consuming and requires detailed technique to make sure that the colors do not run together. Sharp-ended toothpicks are useful.

Inking directly on the TC allows for automatic imprinting and preservation of the ink pattern. If the Mohs surgeon accidentally uses a different color from his routine colors or from the Mohs map, there is documentation of the correct colors used. After the section is completely inked, a diagram of the wound and the inking pattern is drawn on the Mohs map (Figure 5). The TC and Mohs map are labeled with the section number in Arabic numerals and the stage number in Roman numerals. The TC, specimen, and Mohs map are then delivered

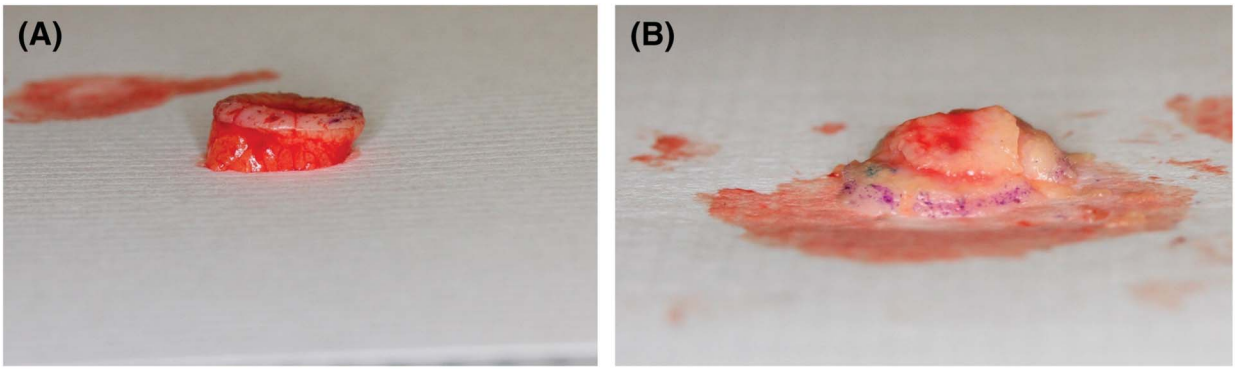

Figure 3. (A) The specimen adheres to the transfer card. Note the vertical sides of the specimen. (B) Relaxing incisions allow the entire epidermal edge to lay flat.

© 2017 by the American Society for Dermatologic Surgery, Inc. Published by Wolters Kluwer Health, Inc. Unauthorized reproduction of this article is prohibited.

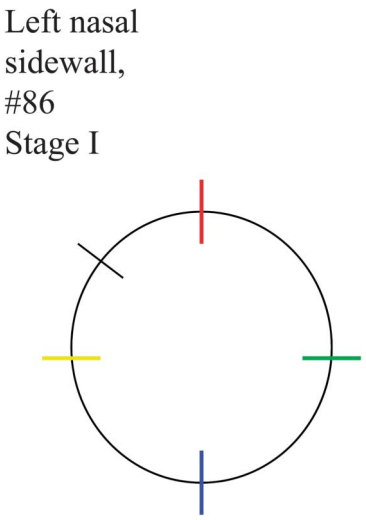

Figure 4. Tissue is inked directly on the transfer card with 4 colors (e.g., red, green, blue, yellow). The extra nick is not inked.

to the histotechnician who embeds and cuts the tissue.

Mohs Mapping

Silapunt and colleagues[18] found that most Mohs surgeons (69.4%) use hand-drawn pictures of the specimens for mapping and orientation. Twenty-one percent use preprinted maps or cartoons of anatomical sites, 1.3% use digital photographs, 0.6% use Polaroid photographs.[18] The advantage of the preprinted anatomical site is standardization across all cases and ease of use. The disadvantage is the lack of consideration of the patient's individual anatomy. Hand-drawn figures offer more flexibility to the dermatologic surgeon but require skill and time. Tromovitch described a technique of placing a plastic sheet over a lightly scored wound specimen and tracing the outline and divisions with a felt-tip pen, which is then used to make the Mohs map.[15] Others have used digital or Polaroid photographs in lieu of conventional Mohs maps. Koranda and colleagues[22] used Polaroid cameras to photograph the specimen adjacent to the surgical site. A Sharpie marker is then used to mark the divisions on the tissue and the wound bed. Jih and colleagues[12] also used Polaroid photographs of the specimen and the wound, and recorded the ink pattern on the photo with corresponding dotted or wavy lines. The Polaroid method is limited by the small size of the photograph, the

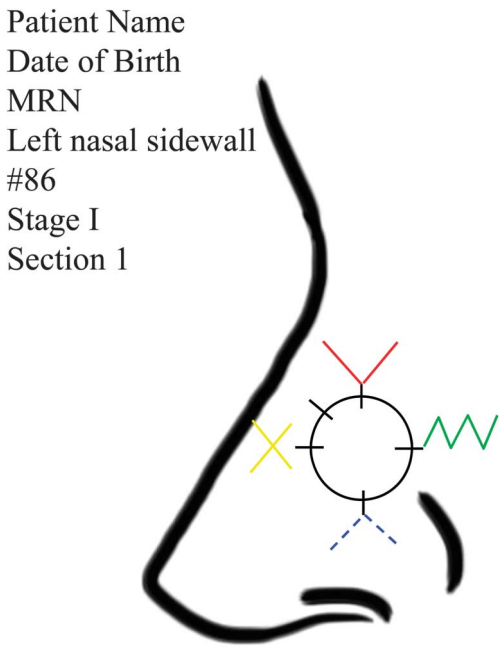

Figure 5. Mohs map is diagrammed with the ink pattern. The Mohs map is labeled with the patient's identifying information and a unique Mohs case number.

difficulty of writing on a glossy surface, bulky archiving, and outdated technology. Papa and Ramsey[23] photographed specimens via digital photography and printed the photos for further mapping, but the wound and patient were not included. Lin and Taylor[24] described four methods of digital photography of the patient and wound bed printed on plain paper, followed by hand-drawn mapping. Alcalay divides the specimen in the surgical suite and then photographs the pieces adjacent to the defect.[25] He then makes his Mohs map and marks the positive margin entirely on the computer. Moriarty and colleagues[26] detailed the use of high-resolution digital photography by a medical photographer. With photography, there is an advantage in depicting the precise size, shape, and orientation of the tumor and wound in addition to the patient anatomy at each stage. However, they require more resources (camera, photographer, equipment), time, and training. A digital system is also subject to technical malfunction, systems crashes, and power outages.

Our Mohs map is preprinted with a diagram of the anatomical site and is labeled with the patient's name, date of birth, medical record number, and a Mohs case number (Figure 5). We hand-draw the specimen on the

© 2017 by the American Society for Dermatologic Surgery, Inc. Published by Wolters Kluwer Health, Inc. Unauthorized reproduction of this article is prohibited.

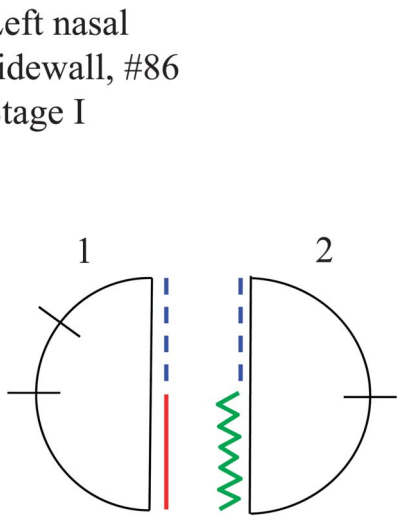

Figure 6. When one stage is divided into two sections, the cut border is inked with blue and red on one side and blue and green on the other. An extra tissue nick is placed in one section.

anatomical diagram following excision. We typically reserve digital photography for surgeries with stages beyond Stage IV, when operating in the perineum or genitalia, or when operating on deep or excavated defects.

Single Versus Multiple Specimen Processing

The first Mohs layer may be processed as a single piece or divided into multiple pieces. Specimen subdivision allows for adequate flattening, mounting on the cryostat chuck, and placement on the glass slide. In a survey by Silapunt and colleagues,[18] the first layer is processed as a single piece by 8.4%, 2 pieces by 47.7%, 3 pieces by 14.8%, and more than 4 pieces by 5.5%. Randle and colleagues[9] describe a single-section method for small or thin specimens using TNs at 12, 3, 6, and 9 o'clock positions, with inking at the 9 and 12 o'clock positions. Some divide the specimen into multiple pieces and lay them on a marked grid in a petri dish.[13–15,27] Once residual tumor is identified, it is then easy to locate within the corresponding grid on the wound. However, when one specimen is cut into multiple sections, there is potential for more false positives as the deeper portions of the tumor at the points of division are pressed flat in continuity with the true surgical margins. There is also potential for more false negatives since more tissue is lost during processing.

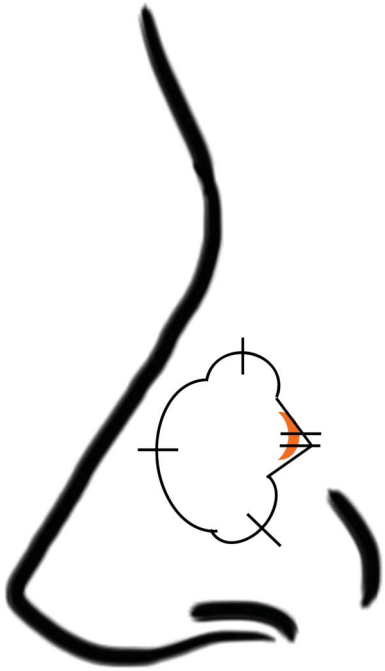

Figure 7. An angulated border and two tissue nicks may be used to note the leading edge of a later stage.

Ellis and colleagues[28] proved mathematically that error rates increase as the number of blocks and the thickness of each layer increases. In addition, more time is required for slide preparation and interpretation. There is greater risk of error in labeling and mapping. However, multiple sections are inevitable in cases where the specimen is too large to mount on the cryostat or on a slide.

In our technique, the tissue is maintained as a single section during processing when possible. If the first layer cannot lie flat or is too large to be maintained as a single section, it is divided into as few sections as possible. In bisected specimens, one block (i.e., Block 1) will have 2 TNs, and the other (i.e., Block 2) will have 1 TN. If the blocks are mislabeled by the histotechnician, the extra TN helps to confirm the correct block. Each section is inked completely around the cut edge, and the nonsurgical adjacent edges of each section are inked differentially (e.g., blue and red in Block 1 and blue and green in Block 2) (Figure 6). The TNs of each section may also be inked with a different color, which adds another unique identifier and helps to ensure that the complete epidermal margin at the TN is seen.

© 2017 by the American Society for Dermatologic Surgery, Inc. Published by Wolters Kluwer Health, Inc. Unauthorized reproduction of this article is prohibited.

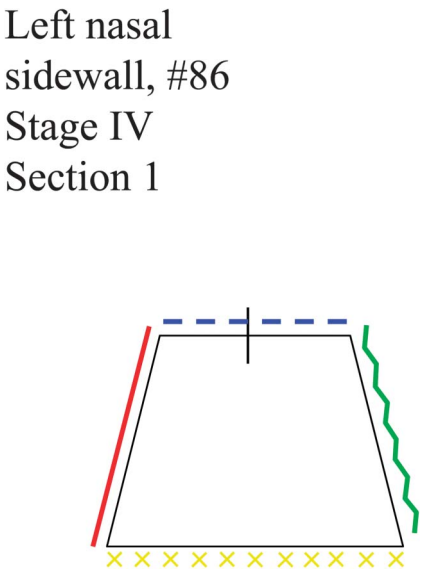

Figure 8. A stage taken of only the deep margin and without epidermis may be shaped as a rhomboid, inked along all sides, and nicked at the 12 o'clock position.

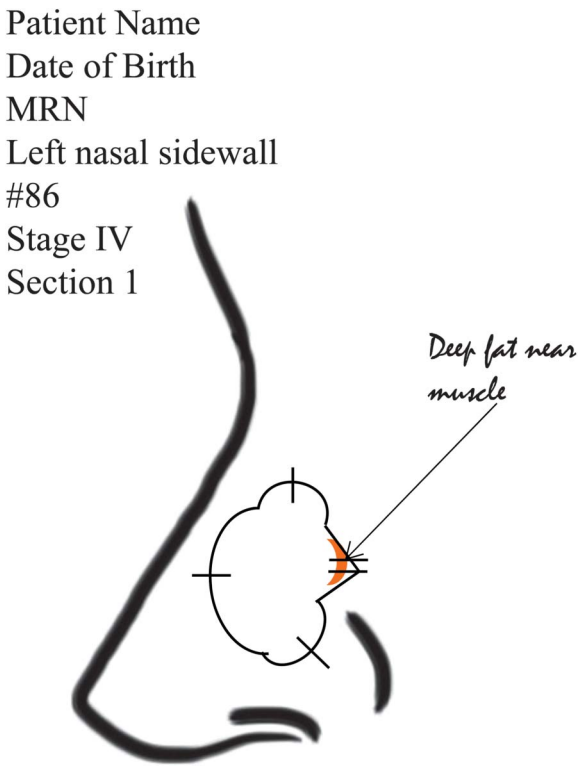

Figure 9. The Mohs map is annotated to note the plane of location of the tumor.

Multiple Stages and Multiple Sites

In later stages, more complexities are encountered: long layers, scalloped borders, and difficulty in locating the tumor in 3D. If a subsequent layer is long and large, an extra TN placed in the middle of the layer will help to break the monotony and allow for easier localization of the tumor. When more than three curved Mohs layers are taken, the positive margin may be difficult to distinguish due to multiple scalloped borders with many TNs on the defect. Double TNs placed 5 millimeters apart in the leading margin can aid in identification of the positive margin. Subsequent layers may also be taken with angulated corners or polygonal shapes to avoid multiple similar-appearing scalloped borders (Figure 7). We have previously described angulated excisions for later stages or -multiple sites to allow for easy visual distinction.[29] Although slightly more tissue is removed during a polygonal excision, the benefit of ensuring accurate tumor resection takes precedence. Flattening the edges and corners is often easier than flattening oval/circular specimens, as the straight margins are more conducive to horizontal compression.

If the layer contains only fat, the top surface may be confused with the bottom surface. In this case, the deep margin (top surface) is completely inked (typically yellow), the periphery is completely inked with four other colors, and the layer is shaped as a trapezoid and nicked at the 12 o'clock position (Figure 8). Since Mohs surgery takes a 3D tumor and flattens it onto a 2D plane, it is important to denote the location of residual tumor in a 3D construct. Tumor located in the periphery may also be present at the deep margin, and vice versa. Annotation of the Mohs map aids in identifying the plane of tissue involved with tumor. The location of the tumor is marked on the map and a note is written to indicate which exact plane (e.g., deep fat near muscle) (Figure 9). This aids the surgeon in remembering to remove muscle in the next layer, which is especially crucial for high-risk tumors such as dermatofibrosarcoma protuberans, or microcystic adenexal carcinoma. Subsequent layers must include a peripheral and deep margin beyond the location of the tumor to ensure adequate removal.

Keeping track of sections from multiple Mohs cases is necessary in cases when 1 patient has more than 1 site, especially in the same subunit/anatomic region. Alternatively, more than 1 patient may have tumor in

© 2017 by the American Society for Dermatologic Surgery, Inc. Published by Wolters Kluwer Health, Inc. Unauthorized reproduction of this article is prohibited.

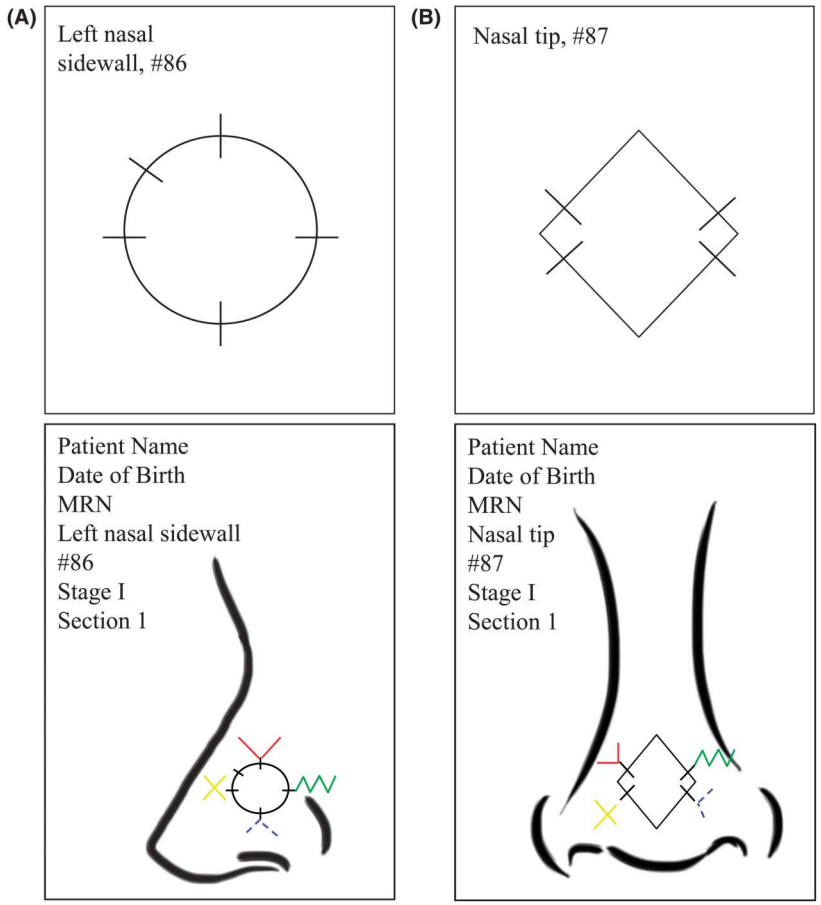

Figure 10. Separate and distinct Mohs maps and transfer cards are used for separate sites. The second site may be shaped with angulated borders.

the same subunit. Kuwahara and colleagues[30] suggest using food coloring to stain tissue-mounting medium to help distinguish each block. In our technique, a second tumor at a separate site requires a distinct Mohs map and TC (Figure 10). This is effective even if 2 tumors are located on anatomically similar sites. For example, a figure of the lateral nose may be used for a tumor on the nasal sidewall, and a figure of the anterior nose may be used for a tumor on the nasal tip. The extra TN may be placed between 12 and 9 o'clock for 1 site, and between 12 and 3 o'clock for a different site. Each specimen may be inked a different color at the extra TN. The second site may also be excised as a polygon (preferably diamond or rhombus).

Conclusion

Precise orientation and tissue mapping is essential to the ability for MMS to attain high cure rates. Although many variations exist at each step, each surgeon develops his own trusted method to ensure complete tumor clearance and maximal tissue preservation. However, each step in this intricate process is subject to error. The surgeon may drop the tissue or shift it out of orientation on the way to the lab. One or more ink colors may not be visible during slide examination due to processing loss, which may result in incomplete or incorrect margin assessment. The ink pattern may differ from the specimen in the Mohs map. Multiple pieces of a single specimen may be switched, labeled incorrectly, or inked incorrectly. The Mohs surgeon may accidentally review the wrong slides prepared for a different case.

We recognize that there are many ways to perform Mohs accurately. It is our intent to encourage each Mohs surgeon to critically analyze their processes and identify and minimize potential failure points. Our system detailed above provides multiple redundant methods (labeling, tissue nicks, inking, angulated

© 2017 by the American Society for Dermatologic Surgery, Inc. Published by Wolters Kluwer Health, Inc. Unauthorized reproduction of this article is prohibited.

borders) for orientation, accuracy, tissue identification, and above all, patient safety. The absorbent TC is a crucial component of this system as it allows for secure adherence of the tissue, which prevents rotation or dropping, and automatically imprints the inking pattern. We have also outlined our methods for handling the nuances of multiple stages, multiple sites, and larger specimens. These techniques are not recommended for every Mohs case, but may be employed for higher risk or more complex cases, which are more prone to error at higher stakes.

References

1. Swanson NA, Grekin RC, Baker SR. Mohs surgery: techniques, indications, and applications in head and neck surgery. Head Neck Surg 1983;6:683–92.
2. Larson PO. Staple and double-staple method of tissue orientation in Mohs micrographic surgery. J Dermatol Surg Oncol 1987;13:732–4.
3. Bagheri S, King T, Justiniano H, Eisen DB. Maintaining tissue orientation during mohs micrographic surgery: scalpel versus marker. Dermatol Surg 2011;37:1412–6.
4. Magee NS, Wagner RF Jr. Surgical pearl: the use of methylene blue temporary tattoos for tissue orientation in Mohs micrographic surgery. J Am Acad Dermatol 2004;50:640–1.
5. Chen TM, Castaneda M, Wanitphakdeedecha R, Nguyen TH, et al. Precautions with gentian violet: skin marking made sterile, effective, and economical. Am J Infect Control 2009;37:244–6.
6. Granick MS, Heckler FR, Jones EW. Surgical skin-marking techniques. Plast Reconstr Surg 1987;79:573–80.
7. Cognetta AB Jr, Wolfe CM, Stewart-Eaves C, Edwards JL. Letter: stereo-orientation of Mohs surgical specimens: a novel histologic pearl to reduce mental fatigue. Dermatol Surg 2012;38:1886–7.
8. Sunseri J, Wolfe CM, Cognetta AB Jr. Object marker: a unique assistive teaching tool in a mohs surgery fellowship. Dermatol Surg 2016;42:902–4.
9. Randle HW, Zitelli J, Brodland DG, Roenigk RK. Histologic preparation for Mohs micrographic surgery. The single section method. J Dermatol Surg Oncol 1993;19:522–4.
10. Ingraffea AA, Bosley R, Godsey T, Gloster HM Jr. The significance of floaters in the nicks of Mohs frozen sections. Dermatol Surg 2012;38:797–9.
11. Alam M, Shah AD, Ali S, Rauf M, et al. Floaters in Mohs micrographic surgery. Dermatol Surg 2013;39:1317–22.
12. Jih MH, Goldberg LH, Friedman PM, Kimyai-Asadi A. Surgical pearl: the use of Polaroid photography for mapping Mohs micrographic surgery sections. J Am Acad Dermatol 2005;52:511–3.
13. Cottel WI, Proper S. Mohs' surgery, fresh-tissue technique. Our technique with a review. J Dermatol Surg Oncol 1982;8:576–87.
14. Picoto AM, Picoto A. Technical procedures for Mohs fresh tissue surgery. J Dermatol Surg Oncol 1986;12:134–8.
15. Tromovitch TA, Stegman SJ. Microscopie-controlled excision of cutaneous tumors: chemosurgery, fresh tissue technique. Cancer 1978;41:653–8.
16. Gross KG, Steinman HK. *Mohs Surgery and Histopathology: Beyond the Fundamentals*. Cambridge, NY: Cambridge University Press; 2009.
17. Weber PJ, Moody BR, Dryden RM, Foster JA. Mohs surgery and processing: novel optimizations and enhancements. Dermatol Surg 2000;26:909–14.
18. Silapunt S, Peterson SR, Alcalay J, Goldberg LH. Mohs tissue mapping and processing: a survey study. Dermatol Surg 2003;29:1109–12; discussion 1112.
19. Wanitphakdeedecha R, Nguyen TH, Chen TM. In vivo intraoperative relaxing incisions for tissue flattening in Mohs micrographic surgery. Dermatol Surg 2008;34:1085–7.
20. Lin SW, Dorrian J, Engasser H, Deem A, et al. Horizontal relaxing incisions limit false positives in thick Mohs sections. Dermatol Surg 2013;39:189–92.
21. Swanson NA. Mohs surgery. Technique, indications, applications, and the future. Arch Dermatol 1983;119:761–73.
22. Koranda FC, Heffron ET, Modert CW, Perkins LL. Photo-mapping for microscopically controlled surgery. J Dermatol Surg Oncol 1982;8: 463–5.
23. Papa CA, Ramsey ML. Surgical pearl: digital imaging for mapping Mohs surgical specimens. J Am Acad Dermatol 2000;43: 712–3.
24. Lin BB, Taylor RS. Digital photography for mapping Mohs micrographic surgery sections. Dermatol Surg 2001;27:411–4.
25. Alcalay J. Digital computerized mapping in Mohs micrographic surgery. Dermatol Surg 2000;26:692–3.
26. Moriarty B, Seaton ED, Deroide F. Use of digital photographic maps for Mohs micrographic surgery. Dermatol Surg 2014;40:349–51.
27. Grabski WJ, Salasche SJ. Mapping and orienting tissue during Mohs micrographic surgery. An alternate approach. J Dermatol Surg Oncol 1991;17:865–8.
28. Ellis JI, Khrom T, Wong A, Gentile MO, et al. Mohs math–where the error hides. BMC Dermatol 2006;6:10.
29. Chen TM, Wanitphakdeedecha R, Nguyen TH. Polyangulated specimen and tissue nicks to facilitate orientation and re-excision in Mohs micrographic surgery. Dermatol Surg 2009;35:993–6.
30. Kuwahara RT, McElroy R, Garcia CA, Cornelison RL. Surgical pearl: colored tissue-mounting medium for Mohs surgery. J Am Acad Dermatol 2003;49:706–7.

Address correspondence and reprint requests to: Tri H. Nguyen, MD, Texas Surgical Dermatology PA, 21009 Kuykendahl Road, Suite A, Spring, TX 77379, or e-mail: mohsdermhouston@gmail.com

© 2017 by the American Society for Dermatologic Surgery, Inc. Published by Wolters Kluwer Health, Inc. Unauthorized reproduction of this article is prohibited.

Frozen-Section Tissue Processing in Mohs Surgery

Arif Aslam, MBChB* and Sumaira Z. Aasi, MD†

BACKGROUND Mohs micrographic surgery (MMS) is the most reliable tissue-sparing technique in the management of cutaneous malignancies. Although the concept is simple, there is considerable variability in the mapping and processing techniques used by Mohs surgeons and histotechnicians.

OBJECTIVE This review article aims to examine the frozen-section tissue processing techniques. Existing variations will be discussed and pearls offered to optimize the frozen processing technique.

METHODS A PubMed search was performed for publications on methods of tissue processing in MMS.

RESULTS Our review highlights variations in debulking, embedding, processing adipose tissue, cartilage, and wedge resections. We offer pearls on how to avoid false-positive and false-negative margins and discuss advances in immunohistochemistry.

CONCLUSION Our article provides a how-to format on the different stages of tissue processing with pearls and techniques to optimize practice and improve accuracy.

The authors have indicated no significant interest with commercial supporters.

What differentiates Mohs micrographic surgery (MMS) from any other tumor extirpation procedure is the concept of "one"—the surgeon-pathologist—who performs the removal of the cancer and oversees its histologic processing and then evaluates for complete microscopic control of the tumor margins. This concept of "one" is unique to MMS and decreases the opportunities for errors in communication and variation in mapping, grossing, processing, and interpreting pathology that can occur when excised tissue is passed through multiple individuals all involved with various aspects of tissue processing and interpretation. In addition, a Mohs surgeon can provide clinicopathologic correlation that cannot be achieved when cancer extirpation is performed by a surgeon, and interpretation of pathology is performed separately by a pathologist. Ideally, complete tumor margin evaluation and consistent meticulous steps to obtain high quality, interpretable frozen sections are the raisons d'etre for the unsurpassable cure rates achieved with MMS. Although the general technique in MMS is similar, there are numerous variations among Mohs surgeons as to how this procedure is performed.

Grossing Tissue

Tumor Debulking

Not all tumors must be debulked before Mohs surgery, but proper debulking, either in situ on the patient or ex vivo at the time of processing, will allow for the deep and lateral margins to be manipulated into one plane for sectioning.

In Situ Debulking

An optimal debulking technique facilitates tumor removal while preserving tissue integrity. Historically, this has been achieved with blunt curettage followed by a beveled excision to obtain the Mohs specimen.[1–3] Debulking allows for excision of a thinner layer of

*Oxford Dermatology, Mount Hawthorn, Perth, Western Australia; †Department of Dermatology, Stanford University, Redwood City, California

© 2019 by the American Society for Dermatologic Surgery, Inc. Published by Wolters Kluwer Health, Inc. All rights reserved.
ISSN: 1076-0512 • Dermatol Surg 2019;45:S57–S69 • DOI: 10.1097/DSS.0000000000002260

© 2019 by the American Society for Dermatologic Surgery, Inc. Published by Wolters Kluwer Health, Inc. Unauthorized reproduction of this article is prohibited.

tissue that is "relaxed" and lies easily in one plane, thus improving embedding and sectioning. Traditional curettage debulking relies on tactile feedback by the surgeon and may lead to larger and deeper defects and, possibly, loss of the normal epidermis.

Many Mohs surgeons now prefer to use sharp debulking (Figure 1). First, the lesion is incised to the dermis at its peripheral margin, and a flat, planar, sharp excision is conducted within the deeper portion of the tumor. The debulked specimen can be sectioned vertically to examine tumor subtype, pattern of invasion, depth, and detection of critical features such as perineural invasion. The Mohs layer is then excised peripherally and deep to the debulking layer. This Mohs stage may either be beveled or incised vertically because this tissue layer is easily manipulated to achieve appropriate lateral and deep margins in the same plane.[4]

A randomized controlled prospective study directly comparing curettage and sharp debulking found the average number of stages required to clear basal cell carcinomas during Mohs surgery was not statistically different.[5]

Postoperative Debulking

Debulking may be conducted after tumor removal. In this case, the specimen is transferred to the Mohs laboratory, and the central portion of the lesion is excised sharply. This allows for analysis of the central section and for easier manipulation of the Mohs tissue layer.

Any form of debulking can lead to the formation of floaters on the histology slide. To minimize this, some surgeons will rinse the tissue after a debulking; carefully wiping any blades used to manipulate the Mohs sections also decreases the chance of friable tumor dislodging. Regardless of the type of debulking the surgeon may opt to use and how it is processed, it is axiomatic that the debulk is not considered and not billed as a separate stage of Mohs surgery.

Orientation, Inking, Embedding, and Mounting

The most careful excision of a tumor is of little use if the histology slides are not an excellent representation of the surgical margin. Tissue manipulation, orientation, and labeling must be precise and accurate to assist in the appropriate mapping of tissue margins.



Figure 1. Tangential excision debulking of tumor.

Numerous methods are used to transfer the tissue from the patient to the laboratory, and these include gauze, glass slides, and filter paper in a Petri dish. We use either a thick filter paper or a gauze on which flattening, inking, and mapping takes place. The paper or gauze is thick enough to absorb any blood and excess fluid, and the tissue adheres to it loosely, preventing it from moving or losing orientation. A patient label is included with the specimen so that it is not confused with other specimens and is transferred to the laboratory in a Petri dish (Figure 2).

Spatial orientation of the excised Mohs layer is maintained by tissue nicks or hatches, sutures, staples, gentian violet, or methylene blue. In the laboratory, the tissue is inked to maintain the orientation of the specimen after sectioning and transferred to glass slides.

© 2019 by the American Society for Dermatologic Surgery, Inc. Published by Wolters Kluwer Health, Inc. Unauthorized reproduction of this article is prohibited.

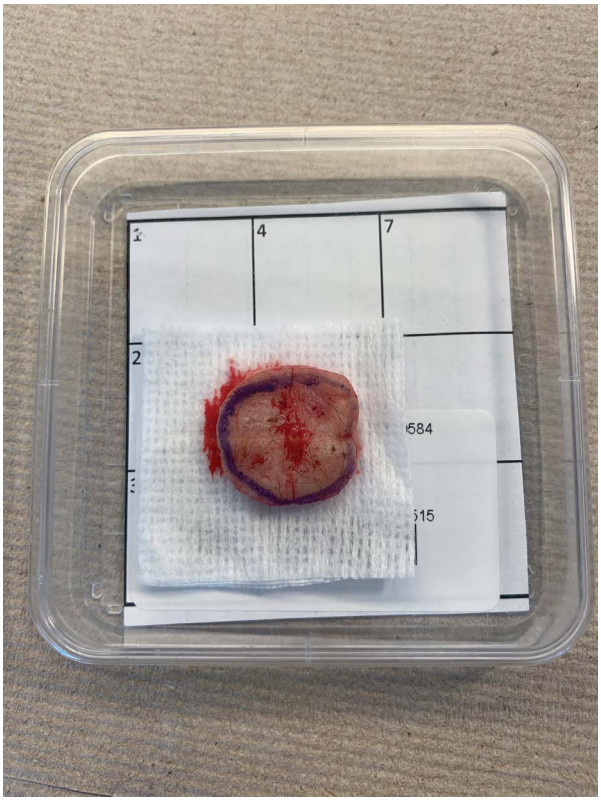

Figure 2. Specimen in a Petri dish on paper which provides orientation and label (not seen to protect patient identity) allows the safe transport and identity of the specimen.

Small and moderate-sized specimens may be sectioned whole. Typical, larger tumors require division into 2, 4, or more sections. Larger cases may require division into many sections (Figure 3).

Our technique involves central tumor debulking (when clinically visible tumor is present), excising the Mohs layer with a beveled cut, followed by scoring the peripheral margins of the Mohs specimen and the corresponding wound edges superficially through the epidermis and papillary dermis. The peripheral wound edge is often scored more lightly and superficially than the Mohs specimen to minimize bleeding from the tissue edge and disruption to the later reconstruction. If the specimen is small and to be kept whole, a nick is made by the surgeon at 12 and 3 or 9 o'clock. If the tumor is to be bisected, additional nicks may be made at 3, 6, and 9 o'clock, but the 12 o'clock is often replaced with double nicks to delineate the orientation clearly. Sutures to mark and provide orientation to the wound are useful for larger tumors and in areas of lax skin where orientation and anatomic alignment become challenging. One such place that we use sutures is when excising large tumors from genital sites that involve the penis and the scrotum or with tumors such as dermatofibrosarcoma protuberans that can erratically cross anatomic tissue layers.

A typical Mohs specimen is divided into pieces that are appropriate in size for both processing and placement on a glass slide. The tissue section(s) are then carefully inked, which allows for orientation and accurate identification. Several different inking patterns have been described, but a standard technique involves inking 2 adjacent deep edges with 2 different colors. When processing a smaller tumor in a single section, the epidermis should be inked for orientation. It is also critical when processing a subsequent stage (re-excision) of a deep positive margin where no epidermis is included that all the peripheral edges of the section are inked to ensure that 100 percent of the margins are being represented on the sections present on the slide.

After sectioning and inking, the surgeon creates a Mohs map which is a 2-dimensional representation of the 3-dimensional operative wound. Many surgeons

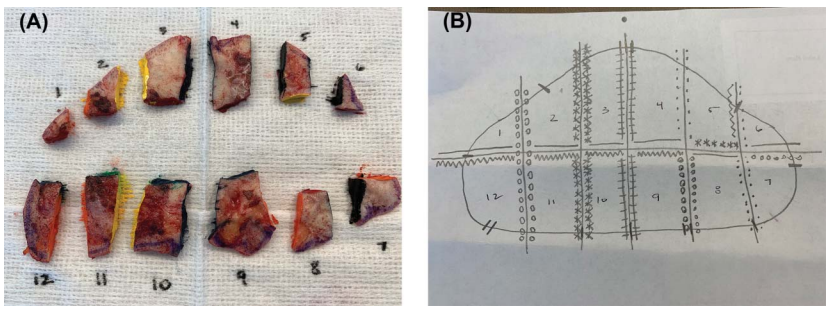

Figure 3. (A) Large tumor subdivided into smaller sections with multiple inks. (B) Corresponding map of large subdivided tumor.

© 2019 by the American Society for Dermatologic Surgery, Inc. Published by Wolters Kluwer Health, Inc. Unauthorized reproduction of this article is prohibited.

use symbols to represent colors. The most common ink colors used in a typical case are black, red, and blue. A solid line delineates one color, dashes represent another, and (x)s represent another, etc. The key is to use a system where all inking and mapping is standardized. Most Mohs surgeons use hand-drawn pictures of the specimen for mapping and orientation, whereas others use preprinted maps or images of anatomical sites or photographs.[6] Free hand drawing is quick and offers flexibility to account for individual patient anatomy. The Mohs map must accurately demonstrate the size and shape of the surgical wound, tissue subdivisions and inking, the exact location of all reference markings, any relevant association with anatomic landmarks, and as tumor removal progresses, the graphic representation of the location, burden, and depth of tumor presence. Ideally, the map should also have information about the features of the tumor such as subtype, differentiation, depth, penetration into deeper anatomic layers, and invasion of nerves and vessels which would have management implications for the patient.

There are advantages to keeping sections as one whole piece: fewer sections to cut and hence less processing time and less cost, possibly less chance of false positives and less chance of errors with mixing up sections and the mapping process.[7] However, many technicians find it easier to mount, prep, freeze, and section smaller pieces of tissue. Whether the Mohs specimen is being processed as a whole (undivided) section or smaller subsections, it is imperative that the deep and epidermal margins are manipulated such that they lie in one plane. As noted earlier, debulking the tumor results in a specimen that is more flexible and easily manipulated. To lay the tissue flat, superficial vertical or beveled relaxing incisions can be made parallel to the edge of the tissue. Standard relaxing incisions pass through the epidermis and a portion of the dermis (Figure 4A–C). They enable the tissue to act as an accordion, stretching out to allow all margins to rotate into a single plane. Multiple forms of relaxing incisions are useful for thick specimens because these incisions allow the dermis to remain intact and allow the adipose and deeper tissues to move independently of the dermis.[8]

Muscle tissue and loose fascial tissues will tend to retract when the specimen is incised. When mounting the specimen, carefully tease out the deep tissue to ensure that this is sectioned. When the tissue is divided into multiple sections, the loose deeper tissue of muscle or fascia can retract, allowing the tumor to overhang or "fold over" and cause a false positive. Similarly, when thin epidermal/dermal sections are created, the epidermis may easily be compressed over the deep margin, creating a false reading.

Embedding and freezing the Mohs specimen have historically been the area of tissue preparation with the greatest variation among surgeons. Yet freezing and embedding are perhaps the most critical steps in ensuring complete, accurate, and high-quality frozen histologic sections. It is important to freeze tissue that will be cut in a cryostat as quickly as possible. Slow freezing of tissue allows the water present in tissue to form ice crystals that can be perceived as artifacts or holes under the microscope.[9] Several embedding methods exist and include freezing tissue on gauze, chucks, glass slides, lens paper, or in liquid nitrogen. Once tissue has been embedded onto a chuck, it must be individually labeled so that it is correctly identified and arranged in a consistent order to avoid confusion (Figure 5).

Most physicians and technicians now use the glass slide technique (Figure 6), which enables the technician to grossly see that the deep and epidermal edges lie on the same plane, without air pockets. The epidermal edge may be teased and unrolled on the glass side, and all such tweaking can be performed before adding the embedding medium. In cases where the tissue does not easily lie flat, the deep margin may be affixed to the slide with a cryogen, and the dermis and epidermis can then be manipulated flush with the slide by applying pressure with the side of a gloved finger. Once the specimen has been appropriately flattened against the glass slide, the superficial portion of the section can be sharply removed with a blade. This is essentially a pre-embedding debulking technique which thins out the specimen and allows it to more easily adhere to the embedding material and freeze to an appropriate hardening for sectioning.

© 2019 by the American Society for Dermatologic Surgery, Inc. Published by Wolters Kluwer Health, Inc. Unauthorized reproduction of this article is prohibited.



Figure 4. (A) Relaxing incisions to ensure the peripheral and deep margins are sectioned in a single plane. (B) Close view of relaxed epidermis. (C) Epidermis and deep margins in a flat single plane.

The epidermis and dermis are usually relatively easy to section. Areas with thicker dermis such as the nose routinely produce reliable, high-quality sections with ease. Unfortunately, many areas and tissues can be challenging to cut properly. Atrophic skin and skin with extensive elastosis will easily chatter, fragment, and accordion fold. Adipose tissue freezes differently from the epidermis and dermis and generally requires longer freezing time before sectioning and may need to be frozen to a colder temperature to obtain appropriate sections.

Sectioning a specimen as one whole piece ensures that the deep margin is unaltered and results in the most accurate representation of the deep margin. However, it is substantially more challenging to obtain unfolded sections of a single piece than it is when the tissue has been bisected or divided into multiple sections. When multiple sections are created, the chuck should be rotated such that the microtome blade meets a natural pointed and cut edge of the section where the epidermis and dermis meet. The microtome blade then is essentially perpendicular to the epidermis and cuts the specimen lengthwise through the epidermis and dermis simultaneously, diminishing the likelihood of a rolled or folded skin edge.[10]

Processing Adipose Tissue

Specimens rich in adipose tissue need to be chilled beneath the temperature of a standard cryostat to obtain high-quality frozen sections and require a more prolonged cooling exposure time than the epidermal or dermal tissue for sectioning.[6,10] However, longer cooling times lead to ice crystal formations in the tissue and increase the risk of freeze artifact, cellular destruction and contribute to the loss of normal tissue histology. Cutting thicker sections, flash freezing with an isopentane histobath, and liquid nitrogen are 3 strategies that have been reported to help with handling adipose tissue. Tung and colleagues systematically compared the frozen-section quality of Mohs specimens containing abundant adipose tissue processed without additional cooling treatments versus those pretreated with LN2 or 1,1,1,2-tetrafluoroethane (TFE), a well-known coolant, and found the use of liquid nitrogen as a cooling spray facilitates the preparation of high-quality frozen sections slides.[11]

The easiest and most effective way to reduce the temperature of adipose tissue is to freeze it in situ on the cryostat with liquid nitrogen. First, the chuck is faced, and several sections are obtained, which contain only the epidermis and dermis. The adipose tissue is then meticulously frozen with liquid nitrogen on the faced tissue block. A few sections are taken and discarded (2 or 3), and the next section is usually easily obtained with a full section containing representative adipose tissue.



Figure 5. Chucks are labeled for identification and are orderly arranged to avoid any confusion.

© 2019 by the American Society for Dermatologic Surgery, Inc. Published by Wolters Kluwer Health, Inc. Unauthorized reproduction of this article is prohibited.

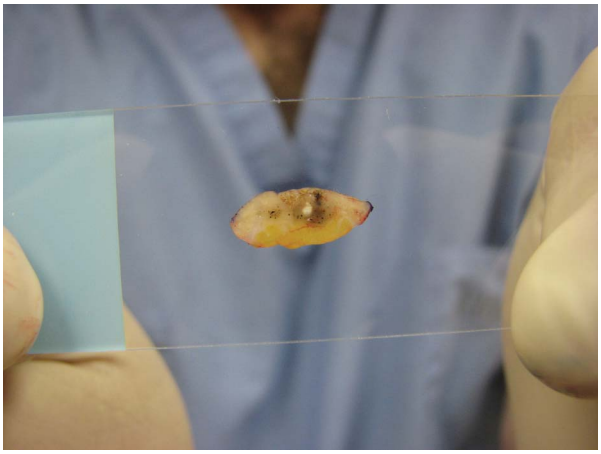

Figure 6. Tissue ready for sectioning using the glass slide technique.

Subsequent stages often involve the removal of thin layers of fascia, periosteum, or looser areolar tissues. These layers desiccate, fold, and retract easily, and they lose spatial orientation quickly. Two methods can be used to facilitate histology processing. In the first method, the tissue is maintained very moist with saline on a gauze. As soon as it is excised, it is placed on the gauze and covered with a Petri dish. The tissue is processed in the Mohs laboratory with care and transferred to a glass slide where it is carefully teased onto the slide and inked at that time. Making incisions into the tissue alters the deep margin, and the largest specimens that can be handled by the technician should be utilized.

The second method involves placing the specimen immediately on a thin layer of a filter paper and then leaving the filter paper adherent to the tissues when doing the initial sectioning. The filter paper is "faced" off the specimen. This method has the advantage of maintaining spatial orientation but may dull the cryostat blade.[12]

Processing Cartilage

Cartilage is temperature-sensitive, so it is optimally sectioned at higher temperatures than adipose tissue, usually between −16 and −22°. Cartilage can be rubbery or stiff and is challenging to flatten. In addition, when it is flattened against a slide, other tissues often retract away from the true margin. To optimize the processing and cryosectioning of cartilage, a few helpful steps can be taken. Cartilage should be kept moist as it becomes more difficult to manipulate as it desiccates. Cartilage also separates readily from glass slides during staining. Because cartilage contains sulfates which create a negative charge, the use of positively charged slides significantly helps the cartilage adhere to the slide. This adhesion to the slides can be enhanced by gently heating the slide, drying the section out before fixation, and by using acetone as a fixative to shorten the fixation process. Slowing the staining process will also prevent the cartilage being washed from the slides as will reducing the water pressure in automated stainers.[13]

The easiest way to section cartilage is longitudinally as a strip, such as along a helical rim. When cartilage is being used as a deep margin, it is helpful to include a layer of deep perichondrium. Perichondrium cuts easily, adheres well to slides, and provides an excellent margin.

Processing Tissue Wedges

Wedge sections of the ear, eyelid, and lip are best excised and handled as a divided prism. If the tissue is excised vertically through the lip, the margin of the eyelid, or the helical rim, the specimen may be harvested such that the specimen forms a prism. The 2 sides of the prism form the medial and lateral boundaries of the excision. Starting several millimeters toward the center of the section, the specimen is divided sharply toward the outer deep margin. The section that is separated then represents one lateral margin. This is repeated on the contralateral side. In most cases this results in 3 tissue sections that bear the meaningful anterior, posterior, lateral and deep margins of the wedge. For the eyelid, the sections look like a sandwich anatomically and histologically with an inner layer of the conjunctiva, then glandular tissue, tarsus, muscle, subcutis, and skin. For the lip, the pattern is mucosa, submucosa, orbicularis oris, subcutis, and skin (Figure 7A, B).

The ear has an anterior and posterior side where the sandwich of tissue would be anatomically and histologically similar unlike the lip and eye; appropriate inking ensures that orientation is maintained.

© 2019 by the American Society for Dermatologic Surgery, Inc. Published by Wolters Kluwer Health, Inc. Unauthorized reproduction of this article is prohibited.

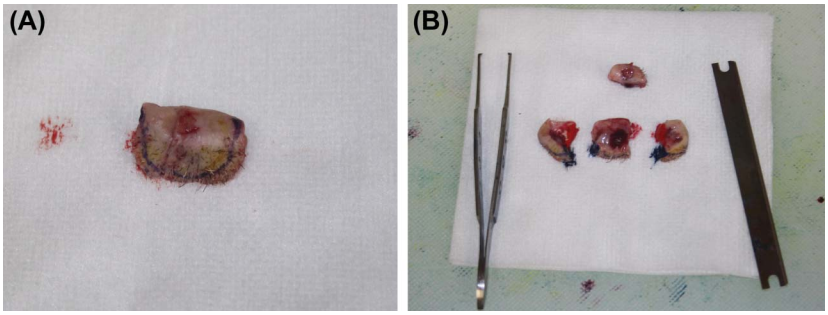

Figure 7. (A) Lip wedge. (B) Lip wedge divided into 3 sections; debulk also shown.

Cryosectioning

Tissue facing should be minimized. Facing is defined as the removal of tissue from the true surgical margin with a microtome before sectioning. Embedding and freezing methods that require extensive facing off to achieve complete sections result in false positives, need for additional layers, larger surgical defects, larger and more complex repairs, and greater patient morbidity.[14] The glass slide technique for embedding allows the entire surgical margin to be in place in a single plane avoiding the need for trimming before sectioning.

The epidermis contains epithelial cells which have an average thickness of 8 μm, so frozen sections are cut between 4 and 6 μm. Cutting tissue at 4 μm is accomplished with a microtome—a cutting instrument which advances the tissue a precise distance and then shaves it using a sharp knife edge creating a very thin frozen section. Thickness preferences should be decided by the Mohs surgeon, and adjusting the thickness will be necessary to accommodate various types of tissue. Periocular tissue may require thin sections, whereas tissue with large fat content may require readjustment to thicker sections. Thinner sections will have clearer nuclear and cytoplasmic elements when stained routinely with hematoxylin and eosin (H&E), and some of these features may be obscured in thicker sections.

Sections that come off the knife edge are idealized when they are cut with slight tension applied to the leading edge of the section. A camel hair paint brush is a useful tool for technicians when sectioning and is used to gently initiate the cutting of the tissue section onto the knife edge. The brush delicately grasps the tissue and guides the section as it is being cut, straightening out wrinkles and preventing folds.

A warm or slightly damp slide will readily attract and allow a frozen tissue section to adhere to the slide. Many technicians gently blow on the slide to use their breath to warm and moisten the slide. After a section is placed on the slide, the excess embedding material adjacent to and surrounding the section should be carefully wiped off so that the next section cut and placed on the slide is not overlapping with the excess embedding material. If this occurs, the staining of a section that is placed on overlapping excess embedding is affected. Sections should be placed on the slide in a defined order, and the same order should be used in each case, such that the surgeon knows which section represents the true margin in each case.

Pitfalls in Cutting Tissue

A great frustration for the Mohs histotechnician and Mohs surgeon occurs when the surgical specimen shatters or "chunks out" during cryosectioning attempts. Once this occurs, the specimen is usually lost, often necessitating the resection of further tissue. This occurs most commonly with very thin sections. What actually happens is that the blade catches the tissue and begins to lift it away from the embedding material. This can sometimes be avoided by excising a slightly thicker layer of tissue and then serrating the top of the specimen to allow for the embedding material to better enmesh with the specimen. Precise affixing to the chuck and meticulous embedding may also prevent this.

Staining Techniques

The most commonly used tissue stain is hematoxylin and eosin (H&E). Toluidine blue is used less frequently and is mostly helpful when treating basal cell carcinomas. Hematoxylin is a natural dye derived

© 2019 by the American Society for Dermatologic Surgery, Inc. Published by Wolters Kluwer Health, Inc. Unauthorized reproduction of this article is prohibited.

from the bark of the logwood tree. It is a basic nucleophilic dye that binds to the negatively charged nuclear material (RNA and DNA). Eosin is an acidic counterstain applied after hematoxylin and is negatively charged and stains positively charged tissue proteins. There are many rapid H&E staining methods used in Mohs surgery, but the 7 key distinct steps are as follows: fixation, hydration, staining, blueing, counterstaining, dehydration, and clearing. Fixation is the most important for ensuring high-quality frozen sections, and ethanol (70%–90%) is the most commonly used fixative because it works quickly and provides clear nuclear detail.[15] Some providers use methanol, and others use acetone. Reagents are best purchased from the same manufacturer as part of a set of reagents to ensure compatibility.

After fixation, hydration, and hematoxylin staining, an acidic agent is commonly used to remove the embedding agent. After a set of water washes, the blueing agent is then applied. After counterstaining with eosin, the tissue needs to be dehydrated to remove all the water and any excess eosin. Alcohol solutions need to be 95% reagent alcohol or higher for adequate dehydration. Extra alcohols are utilized for better dehydration.

Hand staining is commonly used, and slides are dipped in reagents as batches. An automated linear stainer absolves the technician of the need to dip slides. Automated linear stainers are slower than hand-dipped slides.

Distilled water is the best choice for hydrating tissue, but this is rarely feasible with an automatic stainer, and the local water source is used if the results are acceptable.

The final process is clearing, which makes the tissue translucent. Xylene used to be the gold standard clearing agent, but the 2 main substitute agents are limonene and aliphatic; the latter has the advantage of drying more quickly and being less oily. The most common agent in use is limonene.

Toluidine Blue

Toluidine blue is a weakly hydrophilic cationic dye that is blue in color and orthochromatic when it binds to nucleic acids. It stains reddish purple when it binds to glycosaminoglycans, and this staining is called metachromasia. Some Mohs surgeons feel that this contrast of the blue stain of basal cell carcinoma aggregates with the reddish-purple metachromasia stain of glycosaminoglycans in the surrounding stroma helps to delineate tumor better from adnexal structures.[16] T. blue staining is faster and simpler than H&E and requires no counterstain; however, nuclear detail is inferior, and many providers prefer H&E for squamous cell carcinoma.

Avoiding False-Positive and False-Negative Margins

The reliability of Mohs surgery to cure skin cancer is attributed to excellence in histology. Recurrences may be attributed to several factors including anatomical location, tumor size, aggressive histological subtype, processing errors, interpretation errors, and potentially tumor multifocality.[17] Incomplete sections and missing skin edge can lead to a false-negative margin. The deep margin of a slide should always be complete, the inking should be visible along the entire margin, and the adipose and deeper tissues should be readily and reliably visualized. It is not uncommon to find diminutive, isolate foci of infiltrative tumor and/or perineural tumor, and if the sections are not complete and excellent, the likelihood of missing tumor is higher. Processing Mohs frozen sections is a complex multistep process and errors in any one of the steps can lead to suboptimal slides (Table 1 and Figures 8–10).

Reading the histology on Mohs slides requires an intimate knowledge and experience with neoplastic lesions but also the skill to recognize various patterns of both inflammation and benign normal structures/adnexa.[18] Having thin, excellent, representative sections allows the Mohs surgeon to distinguish between inflammation that is masking tumor cells and inflammation that is simply peritumoral. If there are questions regarding the presence of tumor on a slide, examining the deeper sections into the tissue block or vertical sections of the debulk can assist in determining whether any tumor remains.

The role of inflammation in Mohs surgery has been studied extensively, and in a review of 22,419 cases,

© 2019 by the American Society for Dermatologic Surgery, Inc. Published by Wolters Kluwer Health, Inc. Unauthorized reproduction of this article is prohibited.

TABLE 1. Common Errors and Tips in Mohs Slides Processing[10,15,33]

Presence of rips/tears in epidermis and dermis	Knick in microtome blade
	Uneven Mohs layer with varying thickness of tissue.
	Epidermis and dermis are too cold.
Holes in sections	Tissue is not properly flattened/planar.
	Dull blade
Folds on edges	Single section difficulty.
Accordion folds	Cryostat is too warm or histotech rushes sectioning.
Chatter (venetian blind effect)	Loose blade
	Loose chuck
	Inadequate lubrication
Specimen chunks out of block	Specimen too thin
	Specimen too cold
	Blade is dull
	Loose blade or chuck
	Very sebaceous tissue with extensive elastosis that fragments/shatters
Irregular stain uptake	Thick sections
	Residual embedding material not wiped from slide or cleared with clarifying agent
Slides with bubbles	Insufficient mounting media
	Poor mounting technique
Inadequate nuclear staining and slide inadequately blue/purple	Change hematoxylin and/or bluing agents; increase staining time
Sections too pink	Decrease eosin stain time
	Dilute eosin with 100% alcohol
	Change clearing agent
Small blurry spots and "greasy" haze	Inadequate final dehydration
	Use more washes of absolute alcohol and longer washes (Figure 8)
	Insufficient clearing
Dark sections	Sections cut too thick (Figure 9)
Older slides illegible; detached cover slip	Incompatibility of clearing agent and mounting media or inadequate mounting media or excess water on slide before cover slipping (Figure 10)

additional levels were taken due to inflammation and fibrosis from 6,233 tumors where only 1.9% of cases revealed additional tumor.[19] The authors conclude the importance of taking additional stages if there is inflammation at the periphery because this may yield collision tumors particularly in those patients with significant photodamage. It is important to ensure tissue is examined beneath any scar from a biopsy, previous topical treatment, or surgery to ensure no residual tumor is missed.

Equally common and problematic can be the presence of a false-positive margin, particularly when this is a false-positive deep margin. An "overhanging" margin, a floater, or extensive facing off of tissue can lead to a false-positive margin. Unfortunately, when dealing with aggressive lesions in areas where recurrence will be problematic, the presence of tumor at the deep margin on a tissue slide requires further excision, even if it is most likely that the actual margin is negative and the slide is misrepresentative. For that reason, attention to detail in each step of Mohs specimen processing—debulking, relaxing, embedding, mounting, sectioning, and staining—is essential.

A complete tissue margin examination is the hallmark of Mohs surgery and can be technically difficult to achieve (Figure 11). A case–control study comparing recurrent versus nonrecurrent controls from a database of over 6,000 cases found surgeon interpretation errors, tissue drop-out, and aggressive tumor type as the primary factors resulting in recurrences after MMS, highlighting

© 2019 by the American Society for Dermatologic Surgery, Inc. Published by Wolters Kluwer Health, Inc. Unauthorized reproduction of this article is prohibited.

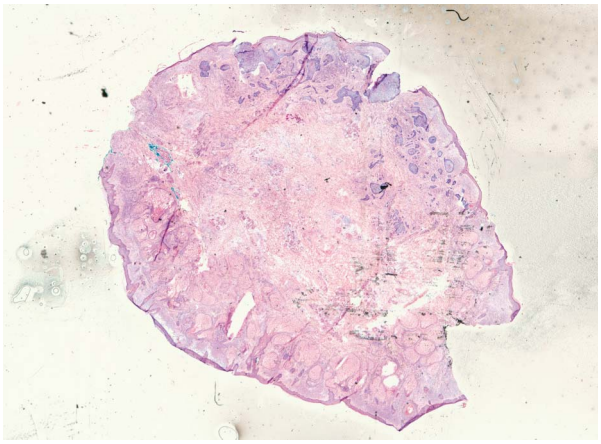

Figure 8. Insufficient clearing leading to water beads forming under the coverslip causing a greasy haze.

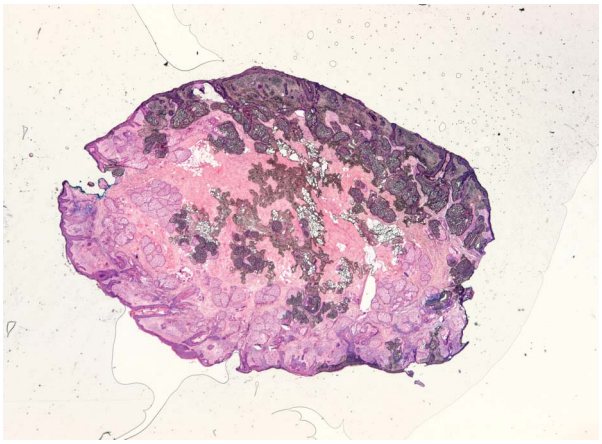

Figure 10. Insufficient mounting medium causing lifting of the coverslip.

the importance of examining the entire dermis and subcutaneous tissue in addition to the entire epidermal margin and not accepting tissue drop-out.[20]

Perineural invasion (PNI) is an important histologic finding and is a negative prognostic factor for basal cell carcinoma (BCC) and especially for squamous cell carcinoma (SCC) (Figure 12). Perineural invasion is defined as tumor cells within any of the 3 layers of the nerve sheath or tumor foci outside of the nerve with involvement of at least 33% of the nerve's circumference.[21] Perineural inflammation and peritumoral fibrosis may indicate nearby PNI and thus warrant further frozen or paraffin sectioning. Perineural inflammation in the absence of an underlying hematologic malignancy consists of predominantly normal-appearing lymphocytes with regular cell size, basophilic nucleus, and scant cytoplasm without cytologic atypia and when isolated may indicate nearby nerve involvement. Peritumoral fibrosis (parallel layers of spindle fibroblasts and collagen fibers around tumor cells) closely resembles PNI and may be very difficult to delineate from true PNI. BCCs and SCCs with perineural invasion can also demonstrate peritumoral fibrosis. Hassanein and colleagues[22] found that 5.8% of BCCs and 4.5% of SCCs with PNI demonstrated peritumoral fibrosis.

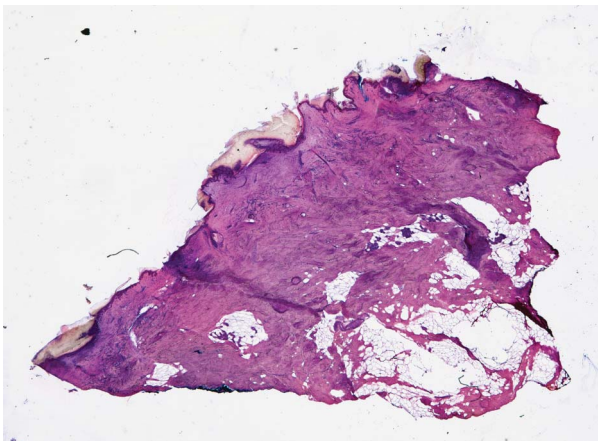

Figure 9. Excessive staining due to thick sections.

A key to perineural invasion is having a high index of suspicion. Perineural invasion can be subtle, and meticulous slide review is essential. Many Mohs surgeons and pathologists have missed isolated, subtle foci of perineural disease only to identify it on the slide at the time of a recurrence. When evaluating a slide, it is important to first scan at low power to get a broad view of the slide. The eye should be attracted to any piece of the puzzle, which is asymmetric or does not fit with the background. The epidermis and dermis should then be examined at midrange magnification. Then, the deep tissue should be examined. Particular attention should be paid to any apparent perivascular or perineural inflammation and/or extension. This may range from involvement of very large nerves down to the most subtle involvement of tiny, superficial nerve branches.

Advances in Immunohistochemistry

Immunohistochemistry (IHC) is routinely used on formalin-fixed tissue and can take several hours to

© 2019 by the American Society for Dermatologic Surgery, Inc. Published by Wolters Kluwer Health, Inc. Unauthorized reproduction of this article is prohibited.

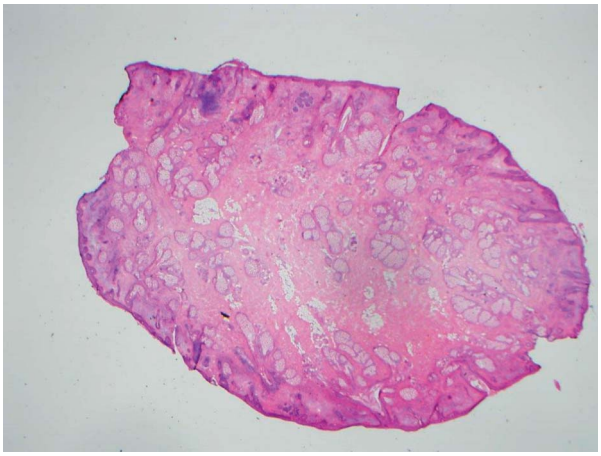

Figure 11. Whole section showing the complete epidermal and deep margins.

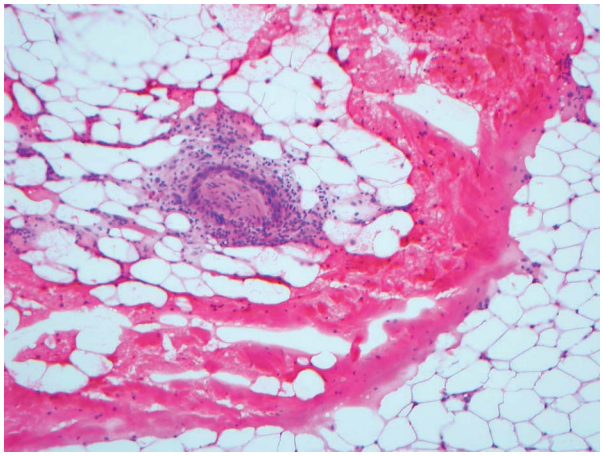

Figure 12. Easily missed small focus of perineural squamous cell carcinoma in subcutis.

complete. Using frozen sections with higher antibody titers results in faster binding, and protocols now exist, which allow for the creation of high-quality slides in less than 90 minutes. Higher antibody concentrations result in more nonspecific staining, so negative controls are necessary for accurate interpretation, and ideally, sections should be 4 μm or less. Each center must determine its favored process. The various staining regimens differ in reagent use and time of preparation.

Mel-5, HMB-45, MART-1, and S100 have all been used for the treatment of melanoma. Melan-A/MART-1 stain is regarded as the most effective single stain used in the interpretation of melanomas with epidermal and dermal components except desmoplastic and spindle cell variants.[23,24] Melan-A, also known as melanoma-associated antigen recognized by T cells (MART-1), is a melanocyte differentiation antigen found in the skin in melanomas, adult melanocytes, and the epidermal and dermal component of nevus cells. MART-1 has consistently been shown to be more sensitive and specific when compared with HMB-45 and S-100.[23–25]

The density, confluence, and depth of follicular penetration of melanocytes in long-standing sun-exposed skin using the MART-1 immunostain have been examined in detail. On average, melanocytes are located along the basal layer at an average density of 15 to 20 per high-power field. Normal sun-damaged skin will have runs of up to 9 adjacent melanocytes with linear arrays of melanocytes extending along hair follicles, albeit without nesting or pagetoid spread[26] (Figure 13A). A biopsy of a nonlesional contralateral sun-exposed site can serve as an appropriate negative control (Figure 13B).

A large cohort study of Mohs surgery using IHC for melanoma in situ and superficially invasive melanoma reported a 0.34% recurrence rate over 2.8 years.[27] In this study, the central debulk section was sent for permanent section breadloaf/vertical histology.

One pearl when doing MART-1 immunostains is to never overlap the new sections with any embedding material. By avoiding overlay with embedding material, the slides are crisper and more definitively stained (Figure 13C).

Mohs micrographic surgery with MART-1 has become much more widespread in the past decade, and a process that used to be limited to a few sites is now widely available. The learning curve for creating good slides is longer than for standard stains, and requirements for Clinical Laboratory Improvement Amendments (CLIA), College of American Pathologists (CAP), and/or Joint Commission on Accreditation of Healthcare Organizations (JCAHO) are greater; however, with practice, the use of MART-1 becomes standardized, reproducible, and easier.

© 2019 by the American Society for Dermatologic Surgery, Inc. Published by Wolters Kluwer Health, Inc. Unauthorized reproduction of this article is prohibited.

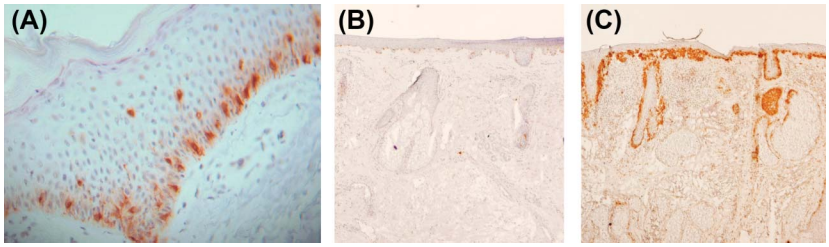

Figure 13. (A) MART1 staining of normal suprabasilar melanocytes. (B) Negative control MART-1 IHC stain. (C) Positive MIS MART 1 stain.

Cytokeratin Stains

Antibodies toward cytokeratins are used in immunohistochemical staining to identify keratinizing cells and to distinguish them in areas of inflammation where morphology may preclude a precise reading. Many studies have demonstrated the value of IHC to detect BCC and SCC, but in practice, few Mohs surgeons utilize these antibodies due to the additional time and cost involved with IHC. Cytokeratins can assist in the interpretation of Mohs slides when removing challenging tumors with aggressive or poorly differentiated histology, perineural invasion, or extensive inflammation.[28]

The anticytokeratin stain, such as AE1/AE3 (stains of both high- and low-molecular-weight cytokeratins), is the most pragmatic choice to incorporate into a Mohs practice because it can identify both BCC and SCC. Although the other stains (desmogleins and Ber-EP4) assist in differentiating between basaloid and squamous proliferations, this information is not critical for the Mohs surgeon, whose task is to remove the tumor with clear margins.[25]

Unfortunately, cytokeratin staining is less reproducible than MART-1, may be more costly, and the remuneration for immunostains is low. For that reason, many Mohs surgeons will cut additional sections themselves and have a pathology laboratory perform IHC or, alternately, they will submit the final Mohs layer for permanent sections with IHC. Although this is inconvenient, it can be beneficial for garnering further information regarding the tumor margins.

Cytokeratin-7 is widely considered to be the immunostain of choice for EMPD because it is the only stain that stains all cases diffusely with intense and specific staining of Pagets cells within the epidermis. A comparison of treatments for EMPD found that MMS with CK-7 staining resulted in significantly less disease recurrence than that of wide local excision. At the mean follow-up visit of 65 months for excision and 24 months for Mohs, the disease recurred in 22% of wide local excision patients, versus 8% of the MMS patients.[29]

Quality Control

Histological accuracy in Mohs surgery is vital and the basis for being the gold standard for tissue preservation and optimal curative rates. Many studies demonstrate the excellent congruence of the histologic interpretation of frozen section slides between a fellowship-trained Mohs surgeon and the dermatopathologist.[30–32]

To achieve histological accuracy, quality assurance and quality control of the laboratory and the tissue processing procedure are essential. Quality control with Mohs surgery and ongoing review of slides is a requirement for CLIA, CAP and JCAHO certification. Slides should be routinely reviewed by an unaffiliated pathologist or dermatologic surgeon/Mohs surgeon. Records of concordance rates and discordance rates along with subsequent outcomes should be maintained. The ACMS now offers an annual slide review, which will assess in detail the quality of slides produced by the laboratory and provide feedback and instruction on continued quality improvement. In addition, multiple organizations including the ASMH now provide ongoing instruction in laboratory operation and management, and numerous consultants can assist with improving and optimizing laboratory function.

© 2019 by the American Society for Dermatologic Surgery, Inc. Published by Wolters Kluwer Health, Inc. Unauthorized reproduction of this article is prohibited.

Mohs micrographic surgery is a highly effective tumor extirpation process that requires consistent accuracy in resection, mapping, and histologic interpretation. Its success relies on constant vigilance and aspiration for perfection from both the Mohs histotechnician and the Mohs surgeon.

References

1. Russell KJ, Lee MD, Saleeby ER, Weiss ET, et al. Does debulking using curettage affect the presence of floaters? Dermatol Surg 2014;40:347–8.
2. Jih MH, Friedman PM, Goldberg LH, Kimyai-Asadi A. Curettage prior to Mohs' micrographic surgery for previously biopsied nonmelanoma skin cancers: what are we curetting? Retrospective, prospective, and comparative study. Dermatol Surg 2005;31:10–5.
3. Huang CC, Boyce S, Northington M, Desmond R, et al. Randomized, controlled surgical trial of preoperative tumor curettage of basal cell carcinoma in Mohs micrographic surgery. J Am Acad Dermatol 2004; 51:585–91.
4. Tucker SC, Vinciullo C. Tangential excision debulking with vertical sections prior to Mohs micrographic surgery. Australas J Dermatol 2019;60:221–3.
5. Ratner D, Bagiella E. The efficacy of curettage in delineating margins of basal cell carcinoma before Mohs micrographic surgery. Dermatol Surg 2003;29:899–903.
6. Li JY, Silapunt S, Migden MR, McGinness JL, et al. Mohs mapping fidelity: optimizing orientation, accuracy, and tissue identification in Mohs surgery. Dermatol Surg 2018;44:1–9.
7. Ellis JI, Khrom T, Wong A, Gentile IM, et al. Mohs math—where the error hides. BMC Dermatol 2006;6:10.
8. Lin SW, Dorrian J, Engasser H, Deem A, et al. Horizontal relaxing incisions limit false positives in thick Mohs sections. Dermatol Surg 2013;39:189–92.
9. Bouzari N, Olbricht S. Histologic pitfalls in the Mohs technique. Dermatol Clin 2011;29:261–72.
10. McCulloch M, Hetzer MR, Geddis C. Manual of Frozen Section Processing for Mohs Micrographic Surgery. Am Coll Mohs Surg 2008; 603,701–4,1001–8.
11. Reserva J, Kozel Z, Krol C, Speiser J, et al. Processing adipose-rich Mohs samples: a comparative study of effectiveness of pretreatment with liquid nitrogen versus flash freezing spray. Am J Dermatopathol 2017;39:838–41.
12. Kunz M, Poyner L, Walker K, Somani AK. How we do it: optimising the histological mapping of thin delicate tissue in Mohs micrographic surgery—the paper cut technique. Dermatol Surg 2019. [Epub ahead of print].
13. Shelton M. Lab pearls: making great slides. In: Gross K, Steinman HK, editors. *Mohs Surgery and Histopathology: Beyond the Fundamentals*. New York, NY: Cambridge University Press; 2009; pp. 52–56.
14. Taylor BR, Groover JA, Cook J. Facing the block and false positives in Mohs surgery: a retrospective study of 2,198 cases. Dermatol Surg 2013;39:1662–70.
15. Larson K, Hao HH, Anumolu PL, Minsue Chen T. Hematoxylin and eosin tissue stain in Mohs micrographic surgery: a review. Dermatol Surg 2011;37:1089–99.
16. Todd MM, Lee JW, Marks VJ. Rapid toluidine blue stain for Mohs' micrographic surgery. Dermatol Surg 2005;31:244–5.
17. Highsmith JT, Highsmith MJ, Monheit GD. Histologic accuracy of Mohs micrographic surgery. Dermatol Surg 2018;44:350–3.
18. Aasi SZ, Lefell DJ, Lazova RZ. Atlas of practical mohs histopathology. In: *Chapter 5, Differentiating basal cell carcinoma from normal and benign histologic findings*. New York, NY: Springer; 2013; pp. 65–8.
19. Macdonald J, Sneath JR, Cowan B, Zloty D. Tumor detection after inflammation or fibrosis on Mohs levels. Dermatol Surg 2013;39:64–6.
20. Campbell T, Armstrong AW, Schupp CW, Barr K, et al. Surgeon error and slide quality during Mohs micrographic surgery; is there a relationship with tumor recurrence? J Am Acad Dermatol 2013;69: 105–11.
21. Shimizu I, Thomas VD. Evaluation of nerves in Mohs micrographic surgery: histologic mimickers of perineural invasion and nervous tissue on frozen section. Dermatol Surg 2014;40:497–504.
22. Hassanein AM, Proper SA, Depcik-Smith ND, Flowers FP. Peritumoral fibrosis in basal cell and squamous cell carcinoma mimicking perineural invasion: potential pitfall in Mohs micrographic surgery. Dermatol Surg 2005;31:1101–6.
23. Albertini JG, Elston DM, Libow LF, Smith SB, et al. Mohs micrographic surgery for melanoma: a case series, a comparative study of immunostains, and informative case report, and a unique mapping technique. Dermatol Surg 2002;28:656–65.
24. Zalla MJ, Lim KK, DiCaudo DJ, Gagnot MM. Mohs micrographic excision of melanoma using immunostains. Dermatol Surg 2000;26: 771–4.
25. Thosani MK, Marghoob A, Chen CS. Current progress of immunostains in Mohs micrographic surgery: a review. Dermatol Surg 2008;34:1621–36.
26. Hendi A, Brodland DB, Zitelli JA. Melanocytes in a long-standing sun-exposed skin: quantitative analysis using the MART-1 immunostain. Arch Dermatol 2006;142:871–6.
27. Etzkorn JR, Sobanko JF, Elenitsas R, Newman JG, et al. Low recurrence rates for in situ and invasive melanomas using Mohs micrographic surgery with melanoma antigen recognized by T cells 1 (MART-1) immunostaining: tissue processing methodology to optimize pathologic staging and margin assessment. J Am Acad Dermatol 2015; 72:840–50.
28. Stranahan D, Cherpelis BS, Glass LF, Ladd S, et al. Immunohistochemical stains in Mohs surgery: a review. Dermatol Surg 2009;35:1023–34.
29. Damavandy AA, Terushkin V, Zitelli JA, Brodland DG, et al. Intraoperative immunostaining for cytokeratin-7 during Mohs micrographic surgery demonstrates low local recurrence rates in extramammary paget's disease. Dermatol Surg 2018;44:354–64.
30. Mariwalla K, Aasi SZ, Glusac EJ, Leffell DJ. Mohs micrographic surgery histopathology concordance. J Am Acad Dermatol 2009;60:94–8.
31. Kesty K, Sangueza OP, Leshin B, Albertini JG. Mohs micrographic surgery and dermatopathology concordance: an analysis of 1421 cases over 17 years. J Am Acad Dermatol 2017. [Epub ahead of print].
32. Semkova K, Mallipeddi R, Robson A, Palamaras I. Mohs micrographic surgery concordance between Mohs surgeons and dermatopathologists. Dermatol Surg 2013;39:1648–52.
33. Gross K, Steinman HK, Rapini RP. *Mohs Surgery: Fundamentals and Techniques*. St. Louis, MO: Mosby; 1999.

Address correspondence and reprint requests to: Sumaira Z. Aasi, MD, Department of Dermatology, Stanford University, 450 Broadway Street, Pavilion B, 4th Floor, Redwood City, CA 94063, or e-mail: aasi@stanford.edu

© 2019 by the American Society for Dermatologic Surgery, Inc. Published by Wolters Kluwer Health, Inc. Unauthorized reproduction of this article is prohibited.

Histologic Pitfalls in the Mohs Technique

Navid Bouzari, MD[a,b], Suzanne Olbricht, MD[a,b,*]

KEYWORDS

• Mohs • Skin cancer • Histology • Skin surgery

The Mohs micrographic surgical procedure is an important modality that achieves the highest cure rate for most common skin cancers using an intraoperative stepwise histologic evaluation of surgical margins. The success of the procedure is inherently tied to the reliability of each of many steps that make up the technique. Pitfalls in histologic preparation of the tissue specimens may occur during debulking, excising, orienting, creating the map, sectioning, inking, tissue flattening and freezing, cutting, slide fixation, staining, and mapping the tumor. Challenges are also present in the interpretation of the slides. This article discusses some of the histologic pitfalls of the Mohs technique.

TECHNICAL PITFALLS

Because Mohs surgery involves many steps between taking the tissue from the patient and having the slides ready for interpretation, there are many chances for human error and technical problems (**Table 1**).

Debulking

Mohs surgeons typically use curettage for tumor debulking to remove friable tumor-infiltrated dermis, thereby more accurately defining the tumor margins. Whether preoperative curettage can offer a more precise first-stage excision without compromising tissue conservation remains a subject of debate.[1] Some researchers argue that preoperative curettage may remove normal, healing, and/or actinically damaged skin, creating an unnecessary larger wound that subsequently requires fewer Mohs stages for tumor clearance.[2,3] In contrast, some researchers have shown that preoperative curettage may be tumor-specific and potentially assists in delineating the subclinical extensions of the tumors.[4,5] Because there is no evidence-based recommendation regarding preoperative curettage, at present, the decision to perform preoperative curettage rests largely on an individual surgeon's preferences and personal experience. Mohs surgeons should be aware of several pitfalls encountered during pre-Mohs curettage. The curette may not remove tissue in a uniform fashion with smooth sharply defined borders. If curettage yields jagged edges, it is difficult to take a uniformly narrow specimen during Mohs' surgery. In addition, curettage can create shearing forces in the surrounding epidermis, which may lead to epidermal loss during tissue processing. Curetting severely photodamaged skin in areas such as the forearm and cheek may sometimes create overhanging pieces of epidermis at the edges.[3,6] Furthermore, preoperative curettage may increase the incidence of floaters (**Fig. 1**).[7]

Excising

To achieve a flat pancakelike Mohs layer the optimum bevel angle is from 30° to 45°. A bevel angle less than 15° increases the chance of cutting into the cancerous skin thereby increasing the number of Mohs layers and the diameter of the defect. On the other hand, a bevel angle greater than 45° interferes with proper tissue flattening for optimal sectioning. Specimens that are cut thickly or with tall 90° edges do not lie flat on their own. In such circumstances, there is a higher

[a] Department of Dermatology, Lahey Clinic, Burlington, MA, USA
[b] Department of Dermatology, Harvard Medical School, Boston, MA, USA
* Corresponding author. Lahey Clinic, 41 Mall Road, Burlington, MA 01805.
E-mail address: Suzanne.m.olbricht@lahey.org

Dermatol Clin 29 (2011) 261–272
doi:10.1016/j.det.2011.01.002
0733-8635/11/$ – see front matter © 2011 Elsevier Inc. All rights reserved.

Table 1
Potential technical pitfalls in Mohs surgery

	Potential Pitfall	Recommendation
Debulking	Curettage may create jagged borders, epidermal loss, or induce floater	Curettage when indicated instead of routinely doing it, saline irrigation after excision
Excising	Cutting into cancerous tissue if bevel angle <15°; thick and tall edges if bevel angle >45° Cutting marginal surfaces when making relaxing incisions	Bevel angle of 30° to 45°, use relaxing incisions when tissue doesn't lie flat Make the relaxing incisions close to the center of the specimen
Orienting	Tissue rotation Introducing floaters when making the hash marks	Double-hash at one point, asymmetric hash marks, saline irrigation
Mapping	Inaccurate mapping	Consistency regardless of the mapping method
Sectioning	Inducing tissue lacerations which may be mistaken for hash marks	Controversial whether Mohs surgeon or histotechnician should do the sections. Number of tissue sections are a matter of debate as well
Inking	Placing it in the wrong margin, inadequate inking, ink running over the wrong sections	Controversial whether Mohs surgeon or histotechnician should do the inking. High-quality ink, appropriate amount of ink
Tissue Flattening and Freezing	Ice crystal formation if frozen too slowly leading to cracks and holes in the specimen; curling the tissue if blades are not cold enough	Appropriate temperature from −22°C to −30°C. Cold cutting blades
Cutting	Tearing or curling the tissue with dull blades; tear in the tissue if nicks on the blade; thick specimen with loose screws; inducing floaters	Use sharp blades; check blades for nicks; try to achieve the thinnest sections possible; check the screws; clean the blades
Slide Fixation	Artifact due to short time dehydration; tissue doesn't attach due to defects on the slides; errors in labeling	Appropriate dehydration time; check for defects on the slide; proper labeling
Staining	Artifacts if not long enough time for dehydration; floaters if staining solution is contaminated	Complete dehydration, change staining solution frequently

chance of losing epidermal and/or dermal margins. It is therefore necessary to make relaxing incisions to improve tissue flattening. A potential pitfall is to cut the marginal surface while making the relaxing incisions,[8] which can confuse the orientation as well as interrupt the continuity of the margin. Pitfalls can also occur when taking additional layers for second and subsequent Mohs stages. These sections can be rectangular or crescent shaped. Some investigators think that when a rectangular specimen is taken, tumor may hide in the part of the margin at the end, distal to the acute margin. To avoid a false-negative view, relaxing cuts need to be made in a way such that the 90° angle of the vertical edges is converted to a curved line. This cut can be difficult to perform, especially in narrow specimens. Therefore, some investigators suggest using crescent-shaped sections instead of rectangular sections.[9]

Orienting

The surgeon has many ways of marking the tissue for orientation. Most surgeons create hash marks (nicks) cutting into both the specimen and the edge of the wound simultaneously. Frequently, a nick is created at the 6- and 12-o'clock (or 3- and 9-o'clock) positions in anticipation of a bisected specimen. A potential pitfall for this method is that the tissue may be rotated from the time it is excised to the time it gets to the laboratory. To avoid this rotation, some Mohs surgeons

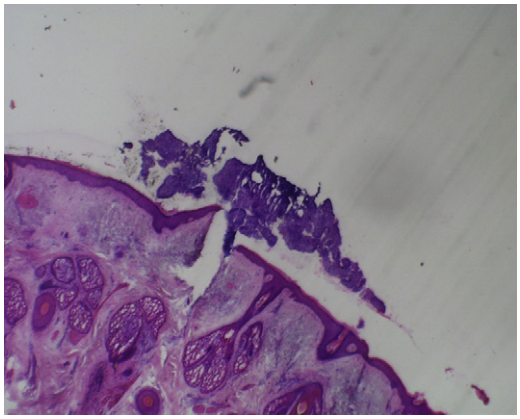

Fig. 1. Floaters can be introduced during curettage, as well as while making nicks, cutting, and staining.

make asymmetric nicks (eg, at the 3- and 12-o'clock positions) or a double nick at 1 point (eg, at the 12-o'clock position). Asymmetric nicks can, however, lead to distortion on the maps in bisected specimens because the bisected line is the result of estimating the half of the specimen. Regardless of the method used by the surgeon, consistency of the orienting method helps to minimize the errors because it provides the ability to the surgeon, the histotechnician, and all the assistants to predict and then identify the right orientation of the tissue without difficulty. Another pitfall that Mohs surgeons should be aware of is that when the tissue is scored from the surface to the depth, a floater can be introduced by forcing tissue at the surface down to the base, producing a false-positive margin (see **Fig. 1**).

Creating the Map

Inaccurate mapping results in false-negative subsequent layers and failure of the technique and may account for some tumor recurrences.[10] There is variability in mapping methods used by Mohs surgeons. Silapunt and colleagues[11] showed in a survey that most of the Mohs surgeons prepare tissue maps themselves using hand-drawn pictures to map and orient specimens. This method is fast and inexpensive. Hand-drawn pictures, however, cannot provide the exact size and shape of the excised area; therefore, these investigators suggest the use of digital and Polaroid photographs, which can produce detailed representations of defects, the excised tissue, and their interrelationship (**Fig. 2**). There are other methods for mapping, such as using preprinted maps or cartoons of anatomic sites. There is no study to show which mapping method is superior in preventing errors. However, consistency of mapping by whichever method



Fig. 2. A printed digital photograph that is available intraoperatively for mapping produces a detailed representation of the defect.

used allows for predictability and thus better accuracy.

Sectioning

Many Mohs surgeons cut the tissue into 2 pieces in the first stage. However, the first-stage tissue may be divided into 3 or 4 pieces in certain circumstances. Cutting into more pieces is more expensive and time consuming but may provide better sections for evaluating epidermal margins.[11] However, there is a higher chance of mislabeling or mixing up the specimens or mismapping positive margins when there are more pieces. Another problem with multiple small sections is the higher likelihood of folding at the epidermal edges, which may lead to false-positive results. In addition, the technician may assume tissue lacerations as hash marks and may make incorrect sections. Hence, some Mohs surgeons section the specimen in the procedure room to reduce the chance of incorrect cuts and inaccurate mapping. However, other surgeons consider that sectioning and grossing by the histotechnician under magnified light allows for better tissue preparation. Still other surgeons prefer that the first stage be processed as 1 piece (pac-man technique), so that orientation cannot be misconstrued. This option works only for relatively small pieces and requires

exceptional skill on the part of the person using the cryotome to section the tissue.[12]

Inking

Inking can be done by the surgeon in the procedure room or by the histotechnician. Some Mohs surgeons prefer to do the inking in the procedure room to reduce the chance of placing ink on the wrong margins. This procedure can, however, be more time consuming for the surgeon, as well as increase the expense because it requires multiple magnifiers and inking equipment in each room. Furthermore, the surgeon should be well acquainted with sectioning because after inking he/she cannot further cut the tissue if the specimen is too large. Inking is most helpful when the ink is placed along a significant portion of the surgical margin rather than just as an orienting dot at the specimen pole (**Fig. 3**). If the specimen is inked along the entire margin, missing ink indicates that a margin is not fully evaluable. On the other hand, if too much ink is used, ink may inadvertently run over and confuse the margins. The same problem can also occur if the specimen is too wet. Quality of the ink is important too. Poor-quality ink may be washed off during the tissue preparation.[13,14]

Tissue Flattening and Freezing

This step is critical for achieving sections in which it is possible to examine the complete en face outer margin of a specimen. Proper flattening makes it possible to section the complete undersurface, the sidewall, and the epidermal margin in a single piece. Several methods are used for flattening: heat-extractor flattening with optimal cutting temperature (OCT) medium in the cryostat, tissue cuts or slits, aerosol freezing on a glass slide, mechanical flattening with liquid nitrogen, or different combinations of these methods.[11] Flattening the tissue can be challenging when the edges are vertical, requiring relaxing cuts to be made. If there is inadequate relaxation of the tissue, peripheral margins may not be teased down, which results in missing epidermis.[15] In some anatomic areas such as periocular tissue, flattening and embedding can be difficult, because delicate periocular tissue may fold easily before embedding.

The tissue should be kept adequately frozen, at −22° to −30°C, to obtain good-quality frozen sections. Colder temperatures of −28° to −32°C may be required for fat-containing tissue. If tissue is frozen too slowly, ice crystals can leave holes in the tissue. Condensate that accumulates in humid conditions can also result in ice crystal formation that causes cracks and holes in the specimen. If the cutting blade in the cryostat is not cold enough, either the sections tend to attach to the blade or the tissue may curl during the cutting. High humidity in the room can also lead to curling of the specimen.[8,14]



Fig. 3. Inking is optimal along a significant portion of the surgical margin rather than just as an orienting dot at the specimen pole.

Cutting

Blades are either permanent or disposable. Dull blades may cause tearing or curling of the tissue, or sometimes cause chatter lines in the tissue as they cut. It is therefore important to sharpen the permanent blades and to move the disposable blades along the blade holder over the course of the day. It is also important to check the blade for nicks. A small microscopic nick in the edge of the blade can create a large tear in the tissue.

The goal in cutting is to achieve the thinnest sections possible because this promotes ease in having the entire epidermis visible on the slide. However, it is difficult to obtain sections thinner than 3 to 4 μm. Thick sections are also difficult to read because some of the cellular details may be obscured (**Fig. 4**). If the knife or chuck screws are loose, the sections may be cut thin in one section and thick in another. Thin sections may make it difficult to cut fat, and holes or tears may be visible. For this reason, thicker sections may be cut. Because the evaluation of both fat and epidermis/dermis is important, alternating thicker and thinner sections may be optimal.[8] Another potential pitfall during cutting is the introduction of a floater from the blade. In this case, the fragment may be visualized on multiple cuts on the slide and may be directly continuous with the true specimen (in contrast to the floaters from

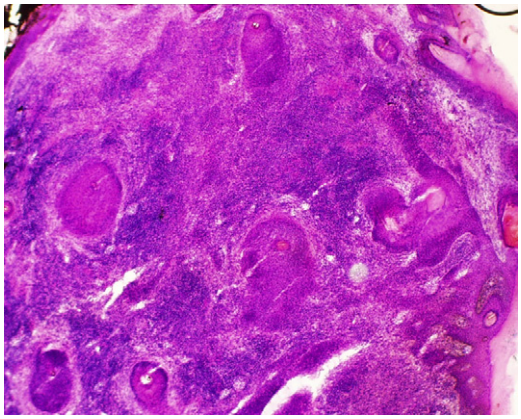

Fig. 4. Cellular details are obscured in thick section (hematoxylin and eosin, original magnification ×2).

the contaminated staining well; see later discussion). The Mohs histotechnician can minimize the potential for introducing floaters by ensuring that the cutting surface and cryostat blade are cleaned between the cases and that the staining solutions are changed frequently.[7] Challenges also occur when the section is slid from the blade onto the slide. After placing each section on the slide, the extra OCT medium around it should be wiped off the glass slide before placing the subsequent specimen. If the subsequent section is placed over the OCT medium, it may not adhere properly during the fixation and as a result it can be washed off the slide during staining. The space between the specimens on the glass slide should be wide enough to avoid overlapping OCT medium with the tissue sections. In addition, if the OCT medium covers the tissue, it may interfere with proper tissue staining.

Slide Fixation

Slide fixation involves the use of chemicals or heat to adhere the tissue to the slide before staining. Mohs laboratories typically use 10% neutral buffered formalin, alcoholic formalin, alcohol, or acetone as a fixative for frozen section slides before staining. Alcohol seems to be the most popular choice, especially because the other 3 agents require the use of a hood. If the slides are removed too quickly from the fixative, they will not have enough time for dehydration, which affects the staining quality (see **Fig. 3**). Another potential pitfall in the slide fixation process is a flaw with the glass slide. If glass slides have any defects or are dirty, tissue may not adhere properly to them. Slides can have frosted or unfrosted ends. The frosted end in slides is usually used to identify the first section that is cut. So slides with a frosted end are preferred because they decrease the chance of confusing the sections. Proper labeling is of utmost importance. Typically, slide labels should include the patient's last name, stage of the surgery, section and level cut, date, and the histotechnician's initials.[16]

Staining

Most Mohs surgeons use hematoxylin-eosin (H&E) for staining. Maintaining quality with H&E staining can be difficult. The staining steps are postfixation preparation, nuclear staining, cytoplasm staining, dehydration, clearing, and cover slipping. Of note, stains are particularly subject to pH changes.[8] Dehydration is also very important to the final outcome. Unless all water is removed, the final slides will have artifact and be difficult to read (**Fig. 5**). Some Mohs surgeons prefer toluidine blue staining.[17] Toluidine blue stains the mucin bright red and, therefore, attracts the eyes to the potential tumor sites. However, mucopolysaccharides can sometimes be abundant around normal adnexal structures, so the bright red color is not specific for tumor. In addition, toluidine blue is not ideal for staining squamous cell carcinomas (SCCs), which have little or no mucopolysaccharides. Another potential pitfall in staining is the introduction of a floater to the slide from a contaminant in the staining solution well. This floater would be expected at only a single locus and at a random orientation to the surgical specimen. The staining solutions should be changed frequently to minimize the risk of introducing floaters.[7]

Mapping Tumor

The surgeon's task of sitting at the microscope and accurately mapping tumor seen on the slides depends on the reliability of the preparation steps

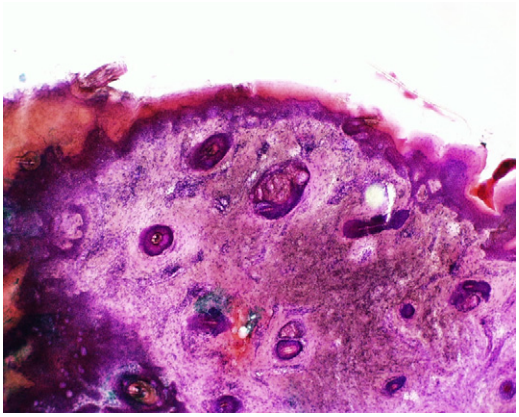

Fig. 5. A thick specimen that is incompletely dehydrated demonstrates low-quality staining and artifact formation (hematoxylin and eosin, original magnification ×2).

detailed so far. Good communication with the histotechnicians as well as daily quality assessment of at least 1 set of slides will facilitate improvement in suboptimal preparation. Specific details of orientation or problems during embedding for unusual specimens can be discussed during handoff of the slides from the histotechnician to the surgeon and may be important and/or time saving during examination of the slides. The surgeon must verify that the slides are matched with the appropriate map and that the pieces are accurately labeled and appropriately represented on the map. Generally, the Mohs surgeon scans the slide first to make sure that the epidermis, dermis, and subcutaneous fat are fully represented; the color of the staining is interpretable; and the ink is visible. Nicks are located on the section, and the location is confirmed on the map. Magnification with a ×2 objective allows the surgeon to easily scan an entire section in 1 power field. Once the tumor has been identified and confirmed with a higher-power lens, the surgeon may then review its location using a ×2 lens to facilitate accurate mapping.

DIAGNOSTIC PITFALLS

A critical component of Mohs technique is the surgeon's skill in interpreting histologic specimens (**Table 2**). Fellowship-trained Mohs surgeons spend much of their time at the microscope acquiring dermatopathology expertise, which improves steadily in relation to the number of cases. Murphy and colleagues[18] showed that more than 1300 Mohs surgery cases and more than 6 months of fellowship training were required before reducing errors to a minimum acceptable level of less than 1 critical error per 100 cases read. Frozen section slides may be more difficult to interpret than formalin-fixed permanent sections, and most dermatologists and pathologists have no experience in examining horizontally cut sections. The Mohs surgeon must follow a systematic, comprehensive, and reproducible system for evaluation of the frozen section slides, correlating the findings observed with the 3-dimensional specimen represented by sequential cuts. There are many challenging situations in which Mohs surgeons must be able to decide whether what they see is a malignant process or a benign structure such as an adnexal structure. Inflammatory cells can both be mistaken for a malignant process or obscure malignant cells.

Floater

If a Mohs surgeon does not accurately identify a floater, an unnecessary excision of normal tissue may ensue. Floaters are extraneous tissue fragments found on a slide in addition to the intended section (see **Fig. 1**).[7] As discussed in the "Technical Pitfall" section, they can be introduced onto the slide at any time during tissue handling and processing. Mohs surgeons may suspect floaters when the visualized tumor differs from the suspected pathologic condition. Location of ink may also help in identification of a floater, in that if the tissue lies outside the ink margin, it is likely to be a floater. The assumption in this case is that the floater is detached from other parts of the specimen and is not located at the true margin. If the origin of the floater is in doubt, another Mohs stage is generally warranted. The occurrence of floaters can be minimized by implementing the preventive methods explained earlier (see the "Technical Pitfalls" section).

Inflammation Versus Tumor

Inflammation may be mistaken for tumor or may obscure an underlying malignancy (**Fig. 6**). Katz and colleagues[19] investigated whether inflammation could mask basal cell carcinoma (BCC). In almost half of the cases, tumor was present in the immediate vicinity of the inflammation. Inflammation can also obscure or resemble SCC, although lymphocytes tend to be smaller and more rounded than epitheloid cells (**Fig. 7**). Some Mohs surgeons stress that prominent aggregates of inflammatory cells may indicate that tumor is nearby, indicating the need for an additional stage of surgery. Using immunohistochemistry, Zachary and colleagues[20] showed single cells or small clumps of SCC in areas in which H&E staining only showed inflammation. However, finding inflammatory cells does not necessarily indicate the presence of tumor. Inflammation can also occur in areas of ulceration or previous biopsy sites.[21] Obtaining a deeper section from the block or having a deeper section cut more thinly may identify if tumor is actually present.

BCC Versus Benign Conditions

A common diagnostic difficulty in histology of skin is distinguishing tangentially sectioned hair follicles from BCC (**Fig. 8**). There are several features that help differentiate the 2, including cleft formation (separation artifact), palisading, mitotic figures, and apoptotic cells that are present around or in BCC nests. Hair follicles are usually surrounded by a fibrous sheath.[22] BCCs that invade deeply into the side of the face or neck may invade into the parotid gland. Mohs surgeons must differentiate the tumor from the blue glandular cells of the parotid (**Fig. 9**). Examining the

Table 2
Potential diagnostic pitfalls in Mohs surgery

	Potential Pitfall	Recommendation
Floater	Floater may be introduced during curettage, making nicks, cutting, and staining	Irrigate with Saline after excision, keep the blades clean, change staining solution frequently
Inflammation vs Tumor	Inflammation can obscure or resemble the tumor	Examine another section from deeper in the block. Immunohistochemistry may be helpful
BCC vs Benign Conditions	Tangentially sectioned hair follicles can be mistaken for BCC	Examine relevant location in multiple sections
BCC vs Other Neoplasms	Trichoepithelioma, spiradenoma, cylindroma, MAC, and metastatic breast cancer may resemble BCC	Examine multiple sections, thaw the block and send for permanent sections. Immunohistochemistry may be helpful
AK vs SCC In Situ vs SCC	Misreading AK for SCC, vice versa, missing SCC clumps in the dermis	Define AK and SCC in situ and make consistent diagnosis. Evaluate the dermis carefully for small clumps of SCC cells. Immunohistochemistry may be helpful
SCC vs Benign Conditions	Healing wound and biopsy sites may be mistaken for SCC. Tangential sectioning of epidermis may resemble SCC	Identify biopsy site grossly and microscopically. Examine multiple sections for lumina, fragments of hair and papillae
SCC vs Other Neoplasms	Inflamed seborrheic keratoses and wart can be mistaken for SCC; adnexal tumors may resemble SCC	Examine multiple sections, thaw the block and send for permanent sections. Immunohistochemistry may be helpful
Perineural Invasion	Missing perineural invasion; Confusing with peritumoral fibrosis, re-excision perineural invasion, reparative perineural proliferation, and epithelial sheath neuroma	Have high index of suspicion in invasive SCC; Examine multiple sections; May need final full margin taken and send for permanent sections and special stains
Melanoma	Hard to recognize melanocytes in frozen section specimen; Inferior quality of frozen section regarding cellular detail	MART-1 staining may be helpful; good communication and close working relationship with dermatopathologist is optimal
Other Tumors	Skip areas in Merkel cell carcinoma, Paget disease, and sebaceous carcinoma; scar may be mistaken for DFSP; normal pilar apparatus may resemble leiomyosarcoma	Be aware of the potential false negative clear margin in multifocal tumors; consider an additional excision of margins for processing as formalin-fixed sections

Abbreviations: AK, actinic keratosis; BCC, basal cell carcinoma; DFSP, dermatofibrosarcoma protuberans; MAC, microcystic adnexal carcinoma.

suspicious area on multiple sections often clarifies confusing histologic results.

BCC Versus Other Neoplasms

Sometimes benign appendageal tumors such as trichoepitheliomas can be confused with BCC. Although trichoepitheliomas characteristically have horn cysts, fibrous stroma, and clusters of mesenchymal cells, in some cases, it is impossible to differentiate them from BCC. Other tumors with blue cells such as poroma, spiradenoma, cylindroma, and metastatic breast carcinoma may resemble BCC. Poromas usually have broad-base connections to the epidermis. Spiradenomas usually have no connection to the surface and make a rosette pattern. Metastatic breast cancer is typically seen in a patient with a history of breast cancer, and commonly in skin of the chest wall. Microcystic adnexal carcinoma is frequently misdiagnosed as BCC, but the appearance of tadpolelike extensions and an increased number of

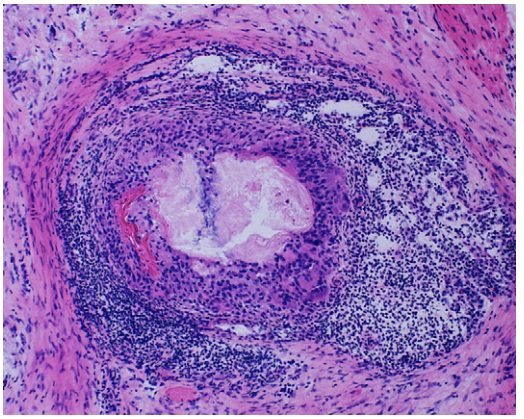

Fig. 6. Inflammation and giant cell reaction around a hair follicle may be confused with tumor (hematoxylin and eosin, original magnification ×10).

glandular structures should help the Mohs surgeon make the correct diagnosis.[21] Examining multiple sections often assists in making an accurate diagnosis. In addition, the block can be thawed and sent for preparation as formalin-fixed paraffin-embedded permanent sections, vertically cut for the dermatopathologist to review.

Actinic Keratosis Versus SCC In Situ Versus Invasive SCC

This diagnostic spectrum has long been a topic of debate within dermatopathology. Distinguishing changes along the actinic damage spectrum is challenging for both clinicians and dermatopathologists (see **Fig. 7; Fig. 10**). Some pathologists think that no fundamental difference exists between actinic keratosis (AK) and SCC but that it is rather a progression along a spectrum.[23,24]

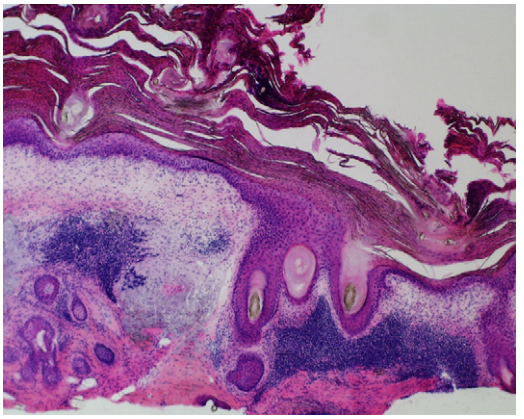

Fig. 7. Differentiation of actinic keratoses and SCC may sometimes be difficult, especially when there is a dense inflammation obscuring the underlying dermis (hematoxylin and eosin, original magnification ×2).

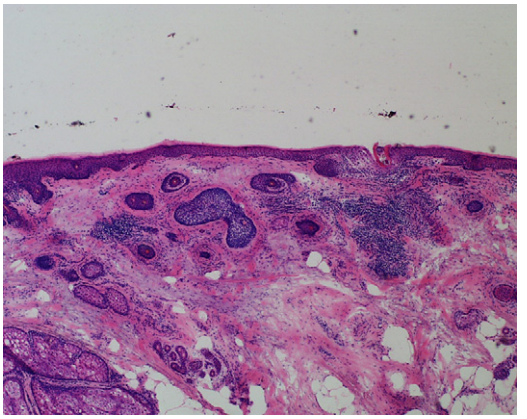

Fig. 8. Tangentially sectioned hair follicle may resemble BCC. Note hair fragments and lack of palisading and retraction artifact. Examination of adjacent sections verified the diagnosis of hair follicle without tumor (hematoxylin and eosin, original magnification ×2).

Studies have shown that up to 60% of SCCs begin as AKs and that there is histologic evidence of contiguous AK in 97% of SCC lesions that arise on sun-damaged skin.[25,26] Furthermore, AKs demonstrate features of malignancy from their inception, from both a cytologic and a molecular biologic perspective. They share genetic tumor markers and have *p53* gene mutations identical with SCCs that involve the dermis.[27] In fact, if cells of an AK could be artificially transplanted into the dermis, the histologic and molecular features would be identical to those of SCC.[23] Invasive disease underlying AK-SCC in situ histology can also be missed. The underlying dermis should be evaluated carefully for nests and cords of atypical squamous cells. It is especially easy to miss small clumps or single cells of SCC in areas of inflammation. Immunostaining using cytokeratin is helpful to



Fig. 9. Dark blue cells are seen in BCC (A), parotid gland cells (B), and lymphocytes in a lymph node (C) (hematoxylin and eosin, original magnification ×2).

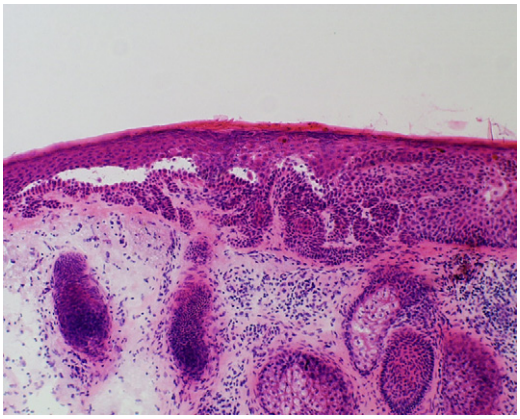

Fig. 10. Distinguishing between actinic keratoses, SCC in situ, and SCC can be challenging, causing disagreement between the Mohs surgeon and the pathologist (hematoxylin and eosin, original magnification ×2).

detect the squamous cells but has the disadvantages of being time consuming and expensive. Moreover, globular material in the papillary dermis may falsely be stained and mistaken for SCC.[28,29] Considering the differences in their treatments, it is important to differentiate AK, SCC in situ, and SCC. Presence of AK in the Mohs sections does not warrant further excision. However, if the Mohs surgeon decides that the extent of atypia is enough to diagnose SCC in situ, it is advisable in most situations to excise another tissue specimen. The threshold for diagnosis of SCC in situ may vary between Mohs surgeons or between Mohs surgeons and dermatopathologists; however, in more than 95% of cases, Mohs surgeons and dermatopathologists agree on the diagnosis as shown in a study by Mariwalla and colleagues.[30]

SCC Versus Benign Conditions

Hair follicles and sweat glands in healing wounds and biopsy sites may show metaplastic changes that can resemble SCC. Keratin pearls, cytologic atypia, and mitoses are all seen in healing wounds and biopsy sites. Helpful clues to differentiate these conditions from SCC are the presence of lumina in the sweat ducts and fragments of hair in the follicles, as well as fibrosis and inflammation at wounded sites. A major difficulty, however, is that SCCs can also exhibit fibrosing inflamed stroma. Tangential sectioning of the epidermis, which is usual in Mohs sections, can produce the appearance of a thickened epidermis resembling SCC. The presence of dermal papillae within the epidermis and the absence of parakeratosis are helpful clues that the diagnosis is not SCC.[21,31]

SCC Versus Other Neoplasms

A variety of benign and malignant neoplasms can be mistaken for SCC. Seborrheic keratoses and warts can show cytologic atypia when irritated. They may have keratin pearls, which are also seen in SCC. Adnexal tumors can also resemble SCC: trichoadenomas usually have numerous horn cysts, sebaceous carcinomas usually arise on the eyelid, and proliferating trichilemmal cysts are commonly seen on the scalp.[21] As with the diagnosis of BCC, examining multiple sections often assists in making an accurate diagnosis. In addition, the block can also be thawed and sent for preparation as permanent sections, vertically cut for the dermatopathologist to review.

Perineural Invasion

Perineural invasion is claimed to occur in approximately 1% of all cases of BCC and in 3% of all cases of SCC (**Fig. 11**).[32] Both Mohs surgeons and pathologists are expected to be able to accurately diagnose perineural invasion. This diagnosis is especially important for Mohs surgeons because studies have shown that the survival rates of patients with SCC complicated by perineural invasion that is cleared by Mohs surgery are better than any other treatment or combination of treatments.[33] Perineural disease can have skip lesions histologically, so that once it is diagnosed, a larger than normal next stage might be performed. Also, if perineural disease is diagnosed, consideration should be given to recommending extensive surgery, such as a parotidectomy for a perineural tumor deep in the cheek, or adjuvant therapy, such as radiotherapy. Although it is important not to miss the perineural invasion, confusing it with other benign conditions may lead to unnecessary Mohs stages and adjuvant

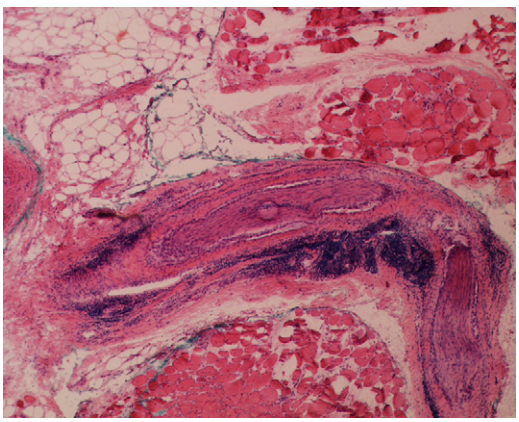

Fig. 11. SCC with perineural and intraneural invasion (hematoxylin and eosin, original magnification ×5).

therapies. In case of a novice, a hair follicle transected through the dermal papilla or an arrector pili muscle surrounded by inflammation could be confused with perineural invasion. Other conditions such as peritumoral fibrosis, reexcision perineural invasion, reparative perineural proliferation, and epithelial sheath neuroma could be challenging for even more-experienced Mohs surgeons.[32,34] Multiple sections must be thoroughly reviewed, and consideration should be given to excising a large complete margin for processing as a permanent section with special stains.

Melanoma

The use of Mohs technique in the treatment of melanoma, compared with nonmelanoma skin cancer, is more complicated, and its role in the management of melanoma has been controversial. Although there is mounting evidence to support the use of Mohs technique for melanoma, there are several pitfalls that Mohs surgeons should be aware of. It has been stressed that frozen section quality is inferior to paraffin-embedded sections, especially with regard to cellular detail. Identification of melanocytes is easier when the tissue is processed in formalin-fixed paraffin-embedded sections. During the formalin fixation process, a clear halo is produced in melanocytes as an artifact of the fixation process because of perinuclear cytoplasmic retraction. This artifact allows for easier identification of single melanocytes in formalin-fixed sections compared with frozen sections because it is not present in the latter. Another disadvantage of the Mohs technique is that horizontal sectioning does not allow for evaluation of the growth characteristics of the central tumor mass or its progression toward the margin, or measurement of the maximal Breslow depth.[35] In addition, evaluation of the margins of lentigo maligna may be difficult because sun-damaged skin often contains atypical melanocytes as a baseline and not a manifestation of cancer or a precancerous lesion. Mohs surgeons should decide whether to consider single atypical melanocytes as an indicator of positive margin. The biologic behavior of these single atypical melanocytes is difficult to predict, but some studies suggest that their removal may be unnecessary and may lead to increased surgical morbidity.[36–38] Although immunostaining with MART-1 has shown to be helpful in diagnosis, there is still a significant amount of discrepancy in diagnoses among Mohs surgeons and dermatopathologists. In some reports, the Mohs sections had unacceptably high false-negative results, 47% in one study.[39,40]

Other Tumors

Mohs surgery has been used for the treatment of dermatofibrosarcoma protuberans, microcystic adnexal carcinoma, sebaceous carcinoma, leiomyosarcoma, and atypical fibroxanthoma, as well as extramammary Paget disease. In some cases, it may be beneficial to work with dermatopathologists, and sometimes modifications of the Mohs technique are necessary, such as using paraffin-embedded sections instead of frozen sections when cellular detail is important. For tumors such as Paget disease, Merkel cell carcinoma, and sebaceous carcinoma, which can be multifocal with prominent skip areas, false-negative clear margins may be seen in the Mohs sections,[14] and it may be advisable to take an extra full margin for examination, either as frozen Mohs sections or as permanent sections in the dermatopathology laboratory. For Merkel cell carcinoma in particular, differentiation of cancer from a small focus of inflammation can be difficult using frozen sections. Another diagnostic challenge is to differentiate the tumor from normal tissue. For example, a scar with reactive fibroblast proliferation may be mistaken for dermatofibrosarcoma protuberans. Leiomyosarcomas must be distinguished from normal pilar apparatus. The presence of mitosis, atypical nuclei, and necrosis favors malignancy. For spindle cell tumors, some investigators advise to take an additional Mohs layer for permanent formalin-fixed sections even after Mohs surgeons are convinced that they have achieved clear margins.[41]

SUMMARY

The reliability of the Mohs procedure in curing skin cancers rests on the accuracy with which tissue is excised, oriented, prepared for slide examination, and evaluated by the surgeon. The technique requires time, teaching, and a sufficient quantity of cases from which to learn, as well as continuous attention to the pitfalls that can occur with the processing and interpretation of the histologic appearance of the specimens. Errors of any kind can lead to cancer persistence and local recurrence. Previous studies have shown that technical and interpretational errors are the most important factors affecting recurrence rate of cancer after Mohs surgery[10] and that a significant number of cases and at least 6 months of training under direct supervision are required to reach to an acceptable level of accuracy.[18] The authors also believe that extended time with both direct and indirect mentoring is essential in developing

expertise in both the technical and histopathologic aspects of Mohs surgery.

REFERENCES

1. Ratner D, Lee DA. Economic impact of preoperative curettage before Mohs micrographic surgery for basal cell carcinoma. Dermatol Surg 2006;32: 916–23.
2. Huang CC, Boyce S, Northington M, et al. Randomized, controlled surgical trial of preoperative tumor curettage of basal cell carcinoma in Mohs micrographic surgery. J Am Acad Dermatol 2004;51: 585–91.
3. Jih MH, Friedman PM, Goldberg LH, et al. Curettage prior to Mohs' micrographic surgery for previously biopsied nonmelanoma skin cancers: what are we curetting? Retrospective, prospective, and comparative study. Dermatol Surg 2005;31:10–5.
4. Chung VQ, Bernardo L, Jiang SB. Presurgical curettage appropriately reduces the number of Mohs stages by better delineating the subclinical extensions of tumor margins. Dermatol Surg 2005; 31(9 Pt 1):1094–9.
5. Ratner D, Bagiella E. The efficacy of curettage in delineating margins of basal cell carcinoma before Mohs micrographic surgery. Dermatol Surg 2003; 29:899–903.
6. Miller SJ. Commentary. Dermatol Surg 2000;26:165–6.
7. Walling HW, Swick BL. Identifying a tissue floater on Mohs frozen sections. Dermatol Surg 2009;35: 1009–10.
8. Nguyen DH, Siegel DM, Zell D, et al. Quality assurance. In: Morgan MB, Hamill JR, Spencer JM, editors. Atlas of Mohs and frozen section cutaneous pathology. New York: Springer; 2009. p. 9–14.
9. Yu Y, Finn DT. Crescent versus rectangle: is it a true negative margin in second and subsequent stages of Mohs surgery? Dermatol Surg 2010;36:171–6.
10. Hruza GJ. Mohs micrographic surgery local recurrences. J Dermatol Surg Oncol 1994;20:573–7.
11. Silapunt S, Peterson SR, Alcalay J, et al. Mohs tissue mapping and processing: a survey study. Dermatol Surg 2004;30(6):961.
12. Gross KG, Steinman HK, Rapini RP. Mohs surgery: fundamentals and techniques. St Louis (MO): Mosby; 1999. p. 86–9.
13. Rapini RP. Comparison of methods for checking surgical margins. J Am Acad Dermatol 1990;23: 288–94.
14. Rapini RP. Pitfalls of Mohs micrographic surgery. J Am Acad Dermatol 1990;22:681–6.
15. McColloch M, Geddis C, Hetzer MR, et al. Embedding techniques. In: Fish FS, editor. Manual of frozen section processing for Mohs micrographic surgery. Milwaukee (WI): ACMMSCO; 2008. p. 601–88.
16. Geddis C, Keating J. Slide fixation and clearing agents. In: Fish FS, editor. Manual of frozen section processing for Mohs micrographic surgery. Milwaukee (WI): ACMMSCO; 2008. p. 901–3.
17. Hetzer MR. The Mohs laboratory. In: Snow SN, Mikhail GR, editors. Mohs micrographic surgery. London: The University of Wisconsin Press; 2004. p. 329–38.
18. Murphy ME, Brodland DG, Zitelli JA. Errors in the interpretation of Mohs histopathology sections over a 1-year fellowship. Dermatol Surg 2008;34(12):1637–41.
19. Katz KH, Helm KF, Billingsley EM, et al. Dense inflammation does not mask residual primary basal cell carcinoma during Mohs micrographic surgery. J Am Acad Dermatol 2001;45:231–8.
20. Zachary CB, Rest EB, Furlong SM, et al. Rapid cytokeratin stains enhance the sensitivity of Mohs micrographic surgery for squamous cell carcinoma. J Dermatol Surg Oncol 1994;20:509–10.
21. Rapini RP. Basal cell carcinoma and squamous cell carcinoma in Mohs sections. In: Gross KG, Steinmann HK, Rapini RP, editors. Mohs surgery fundamentals and techniques. St Louis (MO): Mosby; 1999. p. 161–91.
22. Smith-Zagone MJ, Schwartz MR. Frozen section of skin specimens. Arch Pathol Lab Med 2005;129: 1536–43.
23. Fu W, Cockerell CJ. The actinic (solar) keratosis: a 21st-century perspective. Arch Dermatol 2003; 139(1):66–70.
24. Ackerman AB. Solar keratosis is squamous cell carcinoma. Arch Dermatol 2003;139(9):1216–7.
25. Marks R, Renne G, Selwood TS. Malignant transformation of solar keratosis to squamous cell carcinoma. Lancet 1988;1:795–7.
26. Hurwitz RM, Monger LE. Solar keratosis: an evolving squamous cell carcinoma: benign or malignant? Dermatol Surg 1995;21:184.
27. Brash DE, Ziegler A, Jonason AS, et al. Sunlight and sunburn in human skin cancer: p53, apoptosis, and tumor promotion. J Investig Dermatol Symp Proc 1996;1:136–42.
28. Thosani MK, Marghoob A, Chen CS. Current progress of immunostains in Mohs micrographic surgery: a review. Dermatol Surg 2008;34(12):1621–36.
29. El Tal AK, Abrou AE, Stiff MA, et al. Immunostaining in Mohs micrographic surgery: a review. Dermatol Surg 2010;36(3):275–90.
30. Mariwalla K, Aasi SZ, Glusac EJ, et al. Mohs micrographic surgery histopathology concordance. J Am Acad Dermatol 2009;60:94–8.
31. Grunwald MH, Lee JY, Ackerman AB. Pseudocarcinomatous hyperplasia. Am J Dermatopathol 1988; 10:95–103.
32. Hassanein AM, Proper SA, Depcik-Smith ND, et al. Peritumoral fibrosis in basal cell and squamous cell carcinoma mimicking perineural invasion: potential

pitfall in Mohs micrographic surgery. Dermatol Surg 2005;31(9 Pt 1):1101–6.
33. Lawrence N, Cottel WI. Squamous cell carcinoma of the skin with perineural invasion. J Am Acad Dermatol 1994;31:30–3.
34. Dunn M, Morgan MB, Beer TW. Perineural invasion: identification, significance, and a standardized definition [review]. Dermatol Surg 2009;35(2):214–21.
35. Whalen J, Leone D. Mohs micrographic surgery for the treatment of malignant melanoma. Clin Dermatol 2009;27:597–602.
36. Bricca GM, Brodland DG, Ren D, et al. Cutaneous head and neck melanoma treated with Mohs micrographic surgery. J Am Acad Dermatol 2005; 52:92–100.
37. Bienert TN, Trotter MJ, Arlette JP. Treatment of cutaneous melanoma of the face by Mohs micrographic surgery. J Cutan Med Surg 2003;7:25–30.
38. Bhardwaj SS, Tope WD, Lee PK. Mohs micrographic surgery for lentigo maligna and lentigo maligna melanoma using Mel-5 immunostaining: University of Minnesota experience. Dermatol Surg 2006;32: 690–6.
39. Zitelli JA. Accuracy of en face frozen sections for diagnosing margin status in melanocytic lesions. Am J Clin Pathol 2004;121:937–8.
40. Cohen LM, McCall MW, Hodge SJ, et al. Successful treatment of lentigo maligna and lentigo maligna melanoma with Mohs' micrographic surgery aided by rush permanent sections. Cancer 1994;73: 2964–70.
41. Siegel DM. Mohs surgery for large and difficult tumors and in special clinical situations. In: Gross KG, Steinmann HK, Rapini RP, editors. Mohs surgery fundamentals and techniques. St Louis (MO): Mosby; 1999. p. 231–8.