Journal of Plastic, Reconstructive & Aesthetic Surgery (2015) 68, 56–62

The arterial blood supply of the helical rim and the earlobe-based advancement flap (ELBAF): A new strategy for reconstructions of helical rim defects

Isaac Zilinsky [a,e], Sebastian Cotofana [b,*,e], Niels Hammer [c], Christine Feja [c], Christine Ebel [d], Demetris Stavrou [a], Josef Haik [a], Nimrod Farber [a], Eyal Winkler [a], Oren Weissman [a]

[a] *Department of Plastic and Reconstructive Surgery, Sheba Medical Center, Tel Hashomer, Israel*
[b] *Institute of Anatomy, Paracelsus Medical University, Salzburg, Austria*
[c] *Institute of Anatomy, University of Leipzig, Leipzig, Germany*
[d] *Institute of Anatomy, Ludwig-Maximilians-University, Munich, Germany*

Received 16 March 2014; accepted 22 August 2014

KEYWORDS
Reconstruction of the ear;
Helical rim defect;
Vascularization;
Advancement flap

Summary *Background:* Several techniques are currently available for reconstruction of helical rim defects including Antia and Buch's technique. Some of these techniques produce unsatisfying aesthetic results or are time consuming or technically challenging. Herein, we present the earlobe-based advancement flap (ELBAF) technique and its anatomical basis for reconstruction of helical rim defects.
Methods: A case series of 13 patients with helical rim defects of up to 3.8 cm in length were reconstructed using the ELBAF technique solely or with additional procedures. Patients were followed for the occurrence of complications and evaluation of aesthetic results for up to 8 years. An anatomical assay that included cadaver dissection and anatomical corrosion technique was performed in order to support the ELBAF technique.
Results: Thirteen patients (68.5 ± 9 years, two females) with full-thickness helical rim defects of up to 3.8-cm length caused by basal cell carcinoma in 92.3% underwent reconstruction surgery using the ELBAF technique solely or with additional procedures. No complications related to the ELBAF technique were encountered during follow-up. Cadaver dissections demonstrated a consistent arterial blood supply emerging from the earlobe area, producing arteries that run circularly along the helical rim.

* Corresponding author. Paracelsus Medical University, Strubergasse 21, 5020 Salzburg, Austria. Tel.: +43 662 2420 80410; fax: +43 662 2420 80409.
E-mail address: sebastian.cotofana@pmu.ac.at (S. Cotofana).

[e] Both authors contributed equally to this work.

http://dx.doi.org/10.1016/j.bjps.2014.08.062

Conclusions: Based on the axial vessel pattern, the ELBAF technique seems to be a useful strategy to reconstruct full-thickness helical defects of up to 3.8 cm in length. This procedure can be regarded as a valid addition to the ear reconstruction repertoire, which can be used alone or in combination with other established techniques.

Level of evidence: Level 4, case series.

Introduction

The ear represents a reconstructive challenge for surgeons. It has a complex three-dimensional surface topography that is challenging to mimic during reconstructive surgery. Aesthetic postoperative results shall achieve an aesthetically pleasing ear shape, a symmetric and smooth outer contour, and (if possible) no drawing of the auricle.

Reconstruction of helical rim defects, whether caused by trauma or tumor extirpation, is a common problem that is encountered by plastic surgeons. Traditionally, the most commonly performed method for full-thickness helical rim reconstruction involves a triangular full-thickness excision of skin and cartilage continuous to the defect. This excision is wedge shaped and allows subsequent tensionless cartilage and skin approximation.[1] However, using this method, the outer diameter of the auricle can be significantly reduced and symmetry to the contralateral side is diminished.

Larger helical rim defects can be aesthetically reconstructed using the technique described in 1967 by Antia and Buch.[2] This technique is based on a chondrocutaneous advancement flap for upper pole defects. This method consists of helical rim incisions that go through the anterior skin and cartilage, whereas the posterior auricular skin is left attached to provide ample blood supply. The postauricular skin flap is freed from the conchal cartilage to allow the advancement and approximation of the flaps. While this technique provides good aesthetic results, it tends to be time consuming and there is a long learning curve to mastering it.

Relying on previous anatomical description, the arterial blood supply of the ear is regarded as a spokes-like radial supply of the helical rim emerging from the superficial temporal artery. From our experience albeit, there seems to be reliable and consistent arterial blood vessels coursing along the helical rim, based inferiorly on the earlobe area. Hinging on this alleged blood supply, we suggest a simpler, easier-to-perform, and less time-consuming alternative to the Antia and Buch technique with comparable aesthetic results. We call this the *earlobe-based advancement flap* (ELBAF).

The aim of this study was to describe the ELBAF surgical technique, to report our results with a case series of 13 patients who underwent reconstructive ear surgery using the ELBAF technique, and to demonstrate the proposed arterial blood supply along the helical rim by anatomical assay in cadavers.

Material and methods

Patient selection

A case series of 13 patients (68.5 ± 9 years, two females) were included in this study who underwent reconstructive ear surgery in the Department of Plastic and Reconstructive Surgery, Sheba Medical Center, Tel Hashomer, Israel, between 2005 and 2014 (Table 1). Inclusion criteria consisted of all patients with full-thickness helical rim defects. All patients' defects resulted from tumor extirpation using the Mohs technique. In 12 of the 13 cases, the diagnosis for surgery was basal cell carcinoma and in one case it was Bowen's disease (Table 1). None of the included patients had previous ear surgery or scars upon inspection or other pathologies that might have compromised blood supply of the helical rim. Informed consent was signed by all patients prior to surgery. Follow-up period ranged from 6 months to 8 years.

Surgical technique

All patients were operated by a single surgeon (I.Z.). The surgical technique applied was as follows: Following local anesthesia, a full-thickness incision (through the anterior skin, cartilage, and posterior skin) was carried out from the defects' lower margin, along the scaphoid fossa, and down to the earlobe. The incision was performed using a number 15 blade over a sterile wooden tongue blade for stabilization or by using sharp Metzenbaum scissors. The inferior part of the incision was slightly angled medially ("curving out") at the base of the flap to provide a more robust vascular leash. The resultant flap is long and narrow and its blood supply is based on arteries originating from the earlobe inferiorly, thus rendering this flap an axial flap. The earlobe is flexible and supple and allows for easy advancement of the flap to close the defect (Figure 1). Closure includes cartilage approximation with braided absorbable sutures; anterior skin is sutured with nylon sutures that are usually well hidden in the helical crease and the posterior skin with monofilament absorbable sutures. Patients are instructed to take antibiotics (ciprofloxacin 250 mg p.o. twice daily). Sutures were removed after 1 week's time (see Figure 2).

If defect closure was critical with original flap length, a triangular excision was made at the base of the flap, close to or at the earlobe, imparting a degree of transposition to the proximal part in order to augment the movement of the advancement flap.

Table 1 Demographic and surgical data of the 13 patients included in this study.

Patient	Age	Gender	Side	Diagnosis	defect location	defect size	Flap length	Flap width	Flap ratio	Bilateral flaps	Triangular excisions	Aesthetic result
1	50	M	R	BCC	Middle third	1.8	3	0.6	1: 5			E
2	70	M	L	BCC	Upper third	3.3	5	0.6	1: 8.3		Yes	E
3	74	F	R	BCC	Middle third	2	2.1	0.8	1: 2.6			E
4	63	M	L	BCC	Middle third	1.8	2.2	0.9	1: 2.4	Yes		E
5	82	M	R	BCC	Upper third	3.8	3.5	0.7	1: 5	Yes	Yes	FA
6	67	F	R	BCC	Middle third	1.9	3	0.5	1: 6			E
7	58	M	R	BCC	Middle third	2	2,5	0.8	1: 3.1	Yes		E
8	67	M	R	BCC	Lower third	2.2	1,8	0.6	1: 3			E
9	81	M	L	BCC	Lower third	1.6	2,2	1.5	1: 1.15		Yes	E
10	72	M	R	BCC	Middle third	2	3	0.8	1: 2.7		Yes	E
11	68	M	L	Bowens	Middle third	1.3	2.5	0.6	1: 4.16			G
12	62	M	R	BCC	Upper third	2	4.4	0.9	1: 4.8	YES		G
13	76	M	L	BCC	Upper third	1.5	2.4	0.6	1: 4			E

M = male; F = female; R = right ear; L = Left ear; BCC = basal cell carcinoma; Bowens = Bowens disease; E = excellent; FA = fair; G = good.

Likewise, a superiorly based advancement flap was additionally used to seal the defect if closure was critical with original flap length. The procedure was similar to the inferiorly based advancement flap as described above.

Anatomical analysis

While alive, all body donors gave their informed consent to the participation in studies with scientific purpose. Gross dissection analyses were performed at the Department of Anatomy, Paracelsus Medical University, Salzburg, Austria, while the corrosion procedure and histological staining analyses were performed at the Department of Anatomy, University of Leipzig, Germany. Gross dissection was carried out using six outer ears from three formalin-fixed (in-house embalmment composition) body donors. After removal of the skin and subcutaneous tissues, the superficial temporal artery and the inferior, medial, and superior anterior auricular branches were identified and followed distally as long as macroscopically visible (see Figure 3).

The corrosion procedure was carried out in one ear (left) of a fresh cadaver (no embalmment) while histological staining was performed in the contralateral ear (right) of the same body donor. The bifurcation of the left-sided common carotid artery was visualized macroscopically after incising the lateral border of the carotid triangle before the common and internal carotid arteries were sutured in a circular manner. A catheter was placed in the external carotid artery and a mixture of 10,000 IE heparin (Heparin-Natrium, Ratiopharm®, Ulm, Germany) diluted in 200 ml of warm saline (0.9% by mass) was injected distally until the skin of the ear started to become pale. Then, using the same catheter, Kallokryl M resin (VEB Spezialchemie, Leipzig, German Democratic Republic) was injected into the common carotid artery. After casting of the resin for 3 h, the left ear was removed from the donor and submersed in potassium hydroxide (30% by mass) at

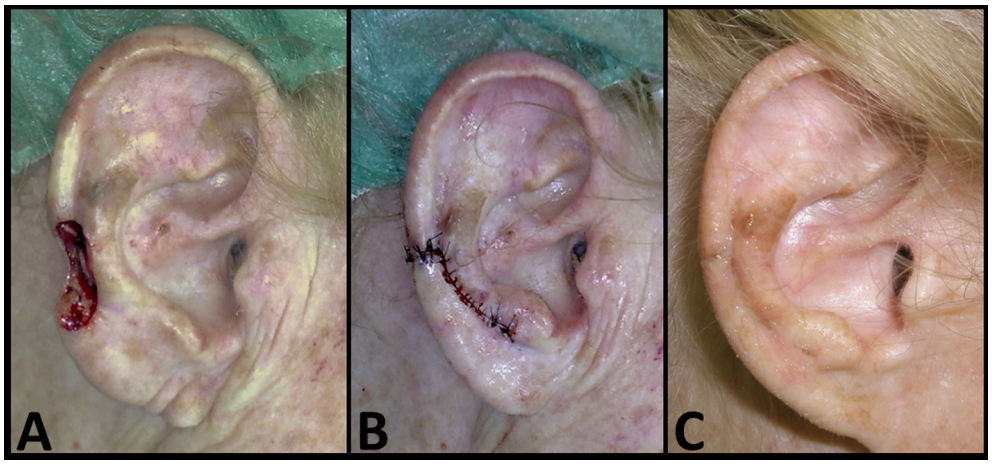

Figure 1 (A) Patient with excision of a basal cell carcinoma in the middle third of the ear. (B) Ear after primary closure. (C) Ear after 4 weeks of follow-up. Please note the stretched earlobe after reconstruction.

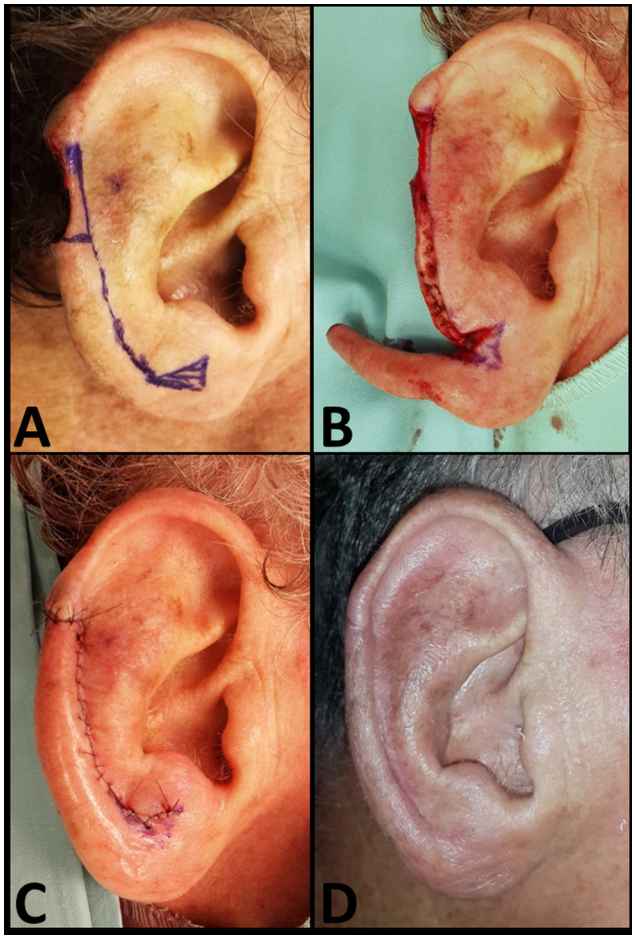

Figure 2 (A) Patient after tumor extirpation on the middle third of the helical rim of the right ear. (B) Ear during surgical reconstruction: ELBAF (Earlobe-based advancement flap) is raised based on blood supply from the earlobe and using additional triangular excisions at the earlobe. (C) Ear after surgical reconstruction: ELBAF after flap advancement and wound closure. (D) Ear 4 weeks after surgery.

35 °C for 3 days to remove the tissues surrounding the Kallokryl resin. After the removal of all surrounding tissues, the arterial system of the outer ear exclusively remained visible (Figure 4).

Tissue samples were obtained from the upper third of the helix of the contralateral outer ear of the same donor. These samples were fixed in 4% paraformaldehyde solution, decalcified with 30% ethylenediaminetetraacetic acid (Chelaplex II, Dr. K. Hollborn & Söhne GmbH & Co KG, Leipzig, Germany), dehydrated in ascending ethanol series and then embedded with paraffin. Serial sections of 10 and 15 μm were stained with hematoxylin—eosin (Figure 5).

Statistical analysis

Differences between surgical procedures applied (ELBAF without additional procedure vs. ELBAF with additional triangular excisions vs. ELBAF with additional superior advancement flap) and defect size were calculated using the Kruskal—Wallis test using Statistical Package for the Social Sciences (SPSS) Statistics 21 (IBM, Armonk, NY, USA).

Results

Patient case series

Demographic and detailed surgical data are presented in Table 1. Defect location was in seven cases (53.8%) in the middle third of the helical rim, in four cases (30.8%) in the upper third, and in two cases (15.3%) in the lower third of the helical rim. The mean defect size was 2.09 cm ranging from 1.3 to 3.8 cm and the mean flap length was 2.89 cm ranging from 1.8 to 5.0 cm. The flap length to width ratio ranged between 1:1.5 and 1:8.3.

In four cases (30.8%), a triangular excision was used to extend the coverage of the flap having a mean defect size of 2.7 cm (range: 1.6—3.8 cm), and also in four cases (30.8%) an additional superiorly based flap was used with a mean defect size of 2.4 cm (range: 1.8—3.8 cm). In six cases (46.2%), no additional procedure was used having a mean defect size of 1.8 cm (range: 1.3—2.2 cm). No statistical

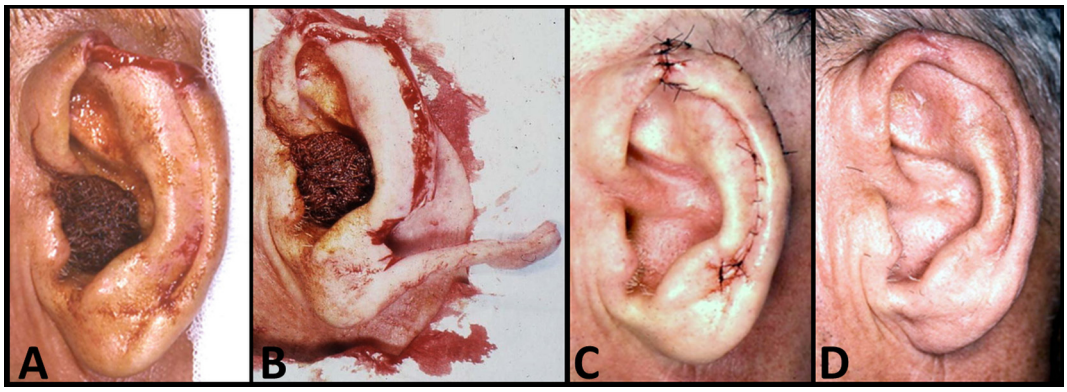

Figure 3 (A) Patient after tumor extirpation of the upper third of the helical rim of the left ear. (B) Intraoperative finding (C) Ear after surgical reconstruction: ELBAF (Earlobe-based advancement flap) is raised based on blood supply from the earlobe and using additional triangular excisions at the earlobe. (D) Left ear 3 weeks after surgery. Please note the stretched earlobe after reconstruction.

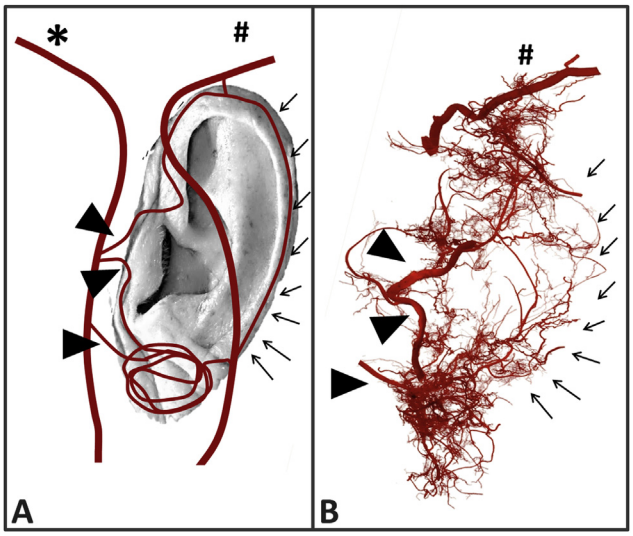

Figure 4 Schematic drawing (A) and corrosion specimen (B) showing the arterial blood supply of the outer ear. * = superficial temporal artery (missing in image B); # = posterior auricular artery (partially visible in the cranial part of the ear but missing in the inferior part); arrow heads mark the inferior, middle, and superior branch of the anterior auricular artery; small arrows mark the anastomosis of the superior and the inferior branch along the helical rim. Note: the earlobe is supplied by both the middle and the inferior branch. Note: an anastomosis is visible between the superior branch and the posterior auricular artery.

significant difference was detected when comparing the defect size to surgical procedure applied, $p = 0.29$.

Aesthetic results, when rated by three different and independent surgeons, were rated in 10 cases (76.9%) as excellent, in two cases (15.4%) as good, and in one case as fair (7.7%). No sloughing of the flap edges or flap necrosis was encountered and no infection, bleeding, or hematomas at the immediate postoperative period were observed. No complaints of excessive pain were reported during the respective follow-up periods.

Anatomical assay

During gross dissection, the superior branch was found in all of the six investigated cases cranial to the tragus, emerging from the superficial temporal artery and running alongside the helical rim posterior-inferiorly. The inferior and the medial branch were identified in all investigated six cases emerging from the superficial temporal artery caudal to the tragus and running both into the capillary system of the earlobe. From the earlobe, small arteries were identified running along the helical rim posterior-superiorly. Due to the small nature of the vessels, arteries were followed distally as long as macroscopically visible (Figure 5).

The corrosion procedure revealed that the resin, injected via the external carotid artery, was visible in the arteries of the outer ear after removal of all surrounding tissues. Two major arteries were identified to be responsible for the vascular supply for the outer ear: the superficial temporal artery and the posterior auricular artery. In detail, three anterior auricular branches (inferior, medial, and superior) were observed to originate from the superficial temporal artery (Figure 4) and one branch was identified to emerge from the posterior auricular artery. The branches of the two arteries had several communicating branches in the concha, the helix, the antihelix, and alongside the tragus. Dorsally on the helical rim, a vascular arch was seen, fed by the inferior and superior branch of

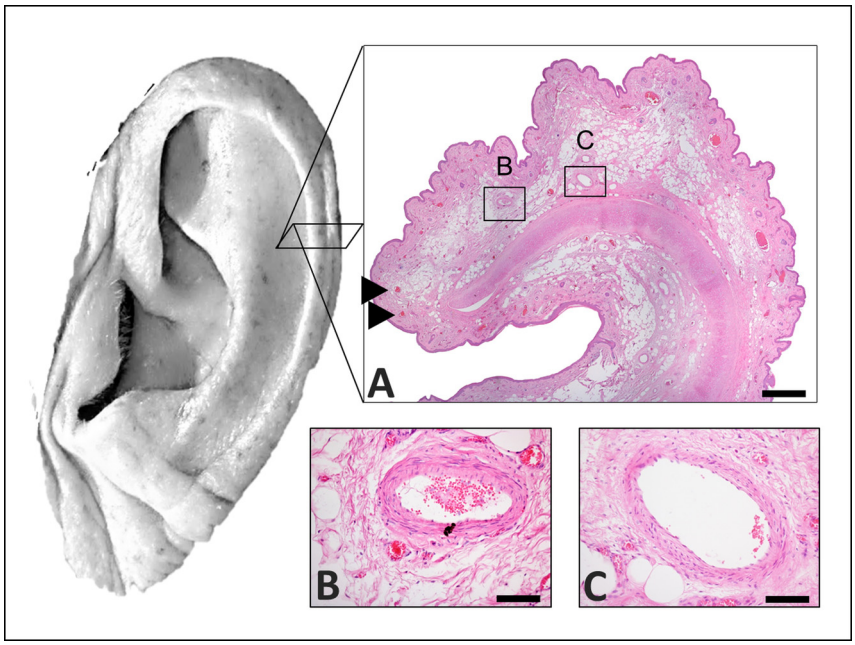

Figure 5 Hematoxylin—Eosin (HE) staining obtained from a sample taken in the upper third of the helical rim (see schematic drawing on the left). (A) Shows arterial branches (B,C) running on the helical rim in the proximity of the auricular cartilage (scale bar 100 μm). Arrow heads mark smaller arteries of the helical rim. (B) and (C) are magnifications of the two greater arteries shown in (A), building the anastomosis between the superior and inferior branch of the anterior auricular artery (scale bar 15 μm).

the anterior auricular artery. On the upper third of the outer ear, the superior branch of the anterior auricular artery had a communicating branch with the posterior auricular artery (Figures 4 and 5). The earlobe was supplied by both the inferior and the medial branch, forming a capillary system. The arteries running on the helical rim were observed to emerge from this capillary system and connecting to the superior branch of the anterior auricular artery.

Discussion

In this study, we report in a case series of 13 patients our results on the surgical reconstruction of helical rim defects. We applied the technique of earlobe-based advancement flap termed herein ELBAF, which can be regarded as an axial flap based on our anatomical studies. They show that the arterial blood supply is provided by arteries emerging from the earlobe and running along the helical rim to form a distinct capillary network between the inferior and the superior branch of the anterior auricular artery.

To date, several techniques for the surgical reconstruction for defects of the helical rim are available. As every technique has its positive and negative sides, the surgeon in charge has to decide which procedure needs to be applied in each respective case. The fact that there is no consensus on an ideal method in terms of ease of performance, time consumption, aesthetic results, and possible donor-site morbidity brings up the need of a potential new or a combination of new and old technique for the reconstruction of helical rim defects.

For instance, direct closure is only applicable in very small defects, and skin grafts tend to lack color and texture match and usually leave a contour deformity and a patchy appearance. Other techniques include the use of a preauricular flap,[3] postauricular flap,[4] banner flap,[5] converse tunnel flap,[6] and mastoid-tubed pedicle flaps.[7] These time-honored techniques provide ample soft tissue cover, though producing visible scarring and aesthetic results that lack in adequate matching of color, texture, and contour. Concomitantly, some of these techniques necessitate several stages while others may produce some appreciable donor-site morbidity.

One of the most popular techniques applied of helical rim reconstruction involves a wedge resection. This technique, though relatively easy to perform, has several inherent flaws. Helical rim shortening with additional wedge-shaped triangular skin and cartilage resection potentially results in cupping deformity when approximated.[1,8] Albeit this deformity can be avoided by adding two small triangular excisions on both sides of the wedge, a noticeable reduction in ear size is produced.[1,9] Scar contraction may produce either webbing or a bilobe-shaped butterfly deformity and the ear may seem pinched.[1]

Antia and Buch's technique provides a reliable method for the reconstruction of helical rim defects as it relies on the ample blood supply of the unhindered posterior auricular skin flap.[2] Several modifications of Antia and Buch's technique have been described, though still requiring the posterior auricular skin flap to be undermined which can prove time consuming as well as susceptible to hematoma formation.[10,11]

Less deforming techniques, based on relatively short, superiorly based or concomitantly superior and inferiorly based helical rim advancement flaps, have been recently described with good results.[8,12] The anatomical basis for the blood supply for these short flaps has been hinted by Park et al.[13] as vascular interconnections between the superficial temporal artery branches and posterior auricular perforators have been reported.

In this present study, we were able to show a communicating branch with the posterior auricular artery, but more importantly we were able to show communication branches running alongside the helical rim connecting the superior and the inferior branch of the anterior auricular artery. This was found constantly in six ears of embalmed specimen and when applying a corrosion procedure in the ear of a fresh cadaver. However, as this was demonstrated in only few numbers, further studies with larger anatomical sample sizes will be needed to guide conclusions regarding the surgical procedure applied.

The ideal reconstructive procedure should be easy to perform, necessitate a single surgical stage, and provide good aesthetic results in terms of color match and texture with minimal visible scarring and no significant donor-site morbidity. Using the ELBAF technique and additional procedures, we have managed to reconstruct defects of up to 3.8 cm and achieved excellent results. From our case series, we can state that in defects up to a size of 2.2 cm the ELBAF technique can be solely applied achieving excellent aesthetic results. For defect sizes of >2.2 cm but also in some dedicated cases having a defect size of more than 1.6 cm, additional procedures such as triangular excisions or a superior-based advancement flap, both ancillaries to the ELBAF, might be necessary to seal the defect properly and aesthetically. The way to decide how long the flap should be excised or if any additional procedure should be added is by a "cut as you go" manner rather than a mathematical preoperative planning. In some cases, the elasticity of the flap is sufficient to stretch it all the way, closing the defect without extending the incision all the way down to the earlobe. When the defect is rather large, the incision down to the earlobe, which is flexible and supple, shall be taken as it allows an easy advancement of the flap to bridge the gap. Albeit we did not find any statistical significant difference between the surgical techniques applied regarding the different defect sizes, larger sample sizes will be needed to strengthen the observations made in this study.

When we attempted utilizing the ELBAF on the defect that was 3.8 cm long, we used additionally the superiorly based helical advancement flap (quite similar to the Tezel and Ozturk technique[12]), and we also had to remove cartilage in order to achieve complete defect closure, hence an aesthetic result that was only fair. In such cases with >3.5-cm defects, we (personal opinion) currently prefer using a retro-auricular-staged interpolation flap in order to achieve excellent aesthetic results. Further, in cases of a previous surgery on the auricle, Antia and Buch's technique may be a safer technique as the arterial blood supply might be impaired.

The ELBAF is a simple straightforward procedure, with no encountered complications in our case series and with almost uniformly excellent aesthetic results. The

consistent blood supply of this flap allowed flaps with a width-to-length ratio of up to 1—8.3 to survive without any additional tip necrosis, further solidifying the validity of the axial pattern of the blood supply.

Conclusion

Based on the axial vessel pattern, the ELBAF seems to be a useful strategy to reconstruct full-thickness helical defects of up to 3.8 cm in length. This procedure can be regarded as a valid addition to the ear reconstruction repertoire, which can be used alone or in combination with other established techniques.

Financial disclosure information

This work did not receive any funding and all authors have no financial interests to disclose.

Ethical approval

Not required.

References

1. Radonich MA, Zaher M, Bisaccia E, et al. Auricular reconstruction of helical rim defects: wedge resection revisited. *Dermatol Surg* 2002;**28**:62—5.
2. Antia NH, Buch VI. Chondrocutaneous advancement flap for the marginal defect of the ear. *Plast Reconstr Surg* 1967;**39**:472—7.
3. Lawson VG. Reconstruction of the pinna using pre-auricular flaps. *J Otolaryngol* 1984;**13**:191—3.
4. Lewin ML. Formation of the helix with a postauricular flap. *Plast Reconstr Surg* 1946;**1950**(5):432—40.
5. Crikelair GF. A method of partial ear reconstruction for avulsion of the upper portion of the ear. *Plast Reconstr Surg* 1946;**1956**(17):438—43.
6. Converse JM. Reconstruction of the auricle. I. *Plast Reconstr Surg Transpl Bull* 1958;**22**:150—63.
7. Steffanoff DN. Auriculo-mastoid tube pedicle for otoplasty. *Plast Reconstr Surg* 1946;**1948**(3):352—60.
8. Taylor JM, Rajan R, Dickson JK, Mahajan AL. Maintaining ear aesthetics in helical rim reconstruction. *Ann Plast Surg* 2012 Dec 13 [Epub ahead of print].
9. Fata JJ. Composite chondrocutaneous advancement flap: a technique for the reconstruction of marginal defects of the ear. *Plast Reconstr Surg* 1997;**99**:1172—5.
10. Low DW. Modified chondrocutaneous advancement flap for ear reconstruction. *Plast Reconstr Surg* 1998;**102**:174—7.
11. Butler CE. Reconstruction of marginal ear defects with modified chondrocutaneous helical rim advancement flaps. *Plast Reconstr Surg* 2003;**111**:2009—13.
12. Tezel E, Ozturk CN. Double helical rim advancement flaps with scaphal resection: selected cases over 10 years and review of the literature. *Aesthet Plast Surg* 2011 Aug;**35**(4):545—52.
13. Park C, Lineaweaver WC, Rumly TO, Buncke HJ. Arterial supply of the anterior ear. *Plast Reconstr Surg* 1992 Jul;**90**(1):38—44.